Interactive effects of dietary and environmental challenges on digestive function and intestinal homeostasis in rainbow trout (*Oncorhynchus mykiss*)

Philosophiae Doctor (PhD) Thesis

Peyman Mosberian Tanha

Department of Animal and Aquacultural Sciences
Faculty of Veterinary Medicine and Biosciences
Norwegian University of Life Sciences

Ås 2016

Thesis number 2016:82
ISSN 1894-6402
ISBN 978-82-575-1398-6

Table of Contents

Acknowledgement

I would like to take this opportunity to express my gratitude to everybody at the Department of Animal and Aquacultural Sciences and to everybody else who supported me at Wageningen University and the Norwegian School of Veterinary Science. I would like to thank the Norwegian University of Life Sciences for financial support of this PhD programme.

First and foremost I thank Professor Margareth Øverland. The completion of this thesis would not have been possible without her dedication, patience, knowledge and support. I am truly grateful that I had the opportunity to work with you! I would like to also thank Dr. Johan Schrama and Dr. Liv Torunn Mydland for their scientific supports and guidance through this journey.

I want to express my deep gratitude to Professor Thor Landsverk who gave me insight into the complicated world of intestinal pathology. Your commitment and dedication made things work at tough times! I also would like to thank Professor Trond Storebakken, for his unconditional support and who I have spent many hours with for discussions.

For the time I spent at the School of Veterinary Sciences I also would like to thank Professor Charles McLean Press for his passionate assistance in histology both technically and scientifically! I would also like to thank my fellow PhD colleagues, who were just great company. I would like to thank the staff at Aquaculture and Fisheries Group at Wageningen University for assisting in sampling and technical issues during my experiment. Also the staff at the histology lab at the School of Veterinary Sciences for their hard work.

I would like to dedicate this thesis to my love, Hona, for her patience, awesomeness and everyday life, who has been always encouraging. This thesis is also dedicated to my family for their unconditional love and support.

September 2016
Peyman Mosberian Tanha

Summary

Aquaculture is challenged by various dietary and environmental factors. A widely debated and studied dietary challenge is the inclusion of plant ingredients containing anti-nutritional factors (ANFs) in salmonids diet. ANFs may adversely affect growth, nutrient utilisation and health of the fish. In addition, aquaculture production is challenged by changes in the environment. Environmental changes can alter several water quality parameters which may directly or indirectly affect the health and performance of the fish. Both dietary and environmental factors interact with gastrointestinal (GI) mucosa and may be harmful to the mucosal barrier. Individually, these challenges may not be a problem, but taken together, problems may start to occur. The complex environment in the GI tract (GIT) consisting of microorganisms, nutrients, anti-nutrients and toxins, makes this organ of the fish vulnerable to diseases. However, the mucosa has developed a barrier function which prevents the penetration of microorganisms and unwanted substances through the lumen. The function of the mucosal barrier is regulated in a way that it will not disturb the absorption of nutrients, water and electrolytes. This function has a crucial role in maintaining gut homeostasis. Challenge to the mucosal barrier, beyond its tolerance, adversely affects the function and integrity of this first line of defence. This in turn results in disturbance of gut homeostasis. The digestive function of the GIT is also sensitive to changes in diet and environment. As absorption is one of the key roles of the GI mucosa, this parameter has been studied under different conditions. Disturbance of the gut homeostasis and mucosal barrier impairment may adversely affect digestive function of the GIT. Different species of fish may respond to the challenges differently. Thus, it is important to gain more knowledge on mucosal barrier function and sensitivity in different fishes. Further, it is important to understand how the interaction of dietary and environmental challenges may affect the fish GI mucosal barrier integrity and homeostasis. It is noteworthy to investigate whether digestive function of the GIT is altered in relation to impairment of mucosal barrier function and intestinal homeostasis.

To expand our knowledge on the mucosal barrier function, an *in vivo* experiment was performed with rainbow trout (*Oncorhynchus mykiss*) fed diets based on fish meal (FM) or increasing levels of soybean meal (SBM) as a dietary challenge to induce soybean meal-induced enteritis (SBMIE). Mucosal barrier function was evaluated in relation to SBMIE by

applying the most commonly used *in vivo* markers in human and mammals: plasma D-lactate, orally administered sugars (sucralose, lactulose and l-rhamnose), and PCR-based detection of bacterial translocation. Orally administered sugar molecules were added to the feed 3 days before sampling. Feeding SBM at 37.5% inclusion level resulted in SBMIE in the distal intestine (DI). Plasma D-lactate level increased linearly with increasing level of SBM inclusion in the diet without increased D-lactate concentration in intestinal content. PCR-based bacterial detection revealed that the risk of bacterial translocation was increased in fish with SBMIE. Neither plasma endotoxin nor sucralose: l-rhamnose (S:R) ratio differed significantly between fish with and without SBMIE. Plasma lactulose: l-rhamnose ratio (L:R) was increased in fish with SBMIE. The plasma level of sugar markers, however, showed large variation among individuals. These results suggest that plasma D-lactate and bacterial translocation were suitable *in vivo* markers to study intestinal barrier function in salmonids.

An experiment was performed to evaluate whether an environmental challenge may aggravate the effect of a plant-based diet on intestinal barrier function, the degree of SBMIE and GI digestive function in rainbow trout. For this purpose, the fish was challenged by SBM diet at 40% inclusion level and exposed to either normal or reduced water flow rate leading to optimal and suboptimal environmental conditions, respectively (i.e., normal or reduced water dissolved oxygen levels). The experiment was split into a 4-week adaptation (Period 1) and a 7- week experimental period (Period 2). In period 1, the fish were adapted to FM (control) and SBM diets and kept at optimal environment. In period 2, the fish was exposed to suboptimal environment under steady-state dietary condition (FM or SBM) or subjected to change in diet (FM to SBM) under steady-state optimal environment or both challenges (FM to SBM and optimal to suboptimal environment). The degree of SBMIE did not increase in response to suboptimal environment; however, the degree of SBMIE was generally high in most of the SBM-fed fish, indicating that the severity of the SBMIE could have masked the additional adverse effect of the environmental challenge on the gut health. However, lipid and starch digestibility was further reduced in fish fed SBM and exposed to suboptimal environment compared to the fish fed the same diet, but kept at optimal environment. The results indicate that there was an interactive effect of dietary and environmental challenge on digestive function in rainbow trout. It may also indicate that digestive function may be a more sensitive parameter compared to SBMIE, when studying the interaction between dietary and environmental challenges.

Detailed study of SBMIE in rainbow trout, revealed pathological features which have not been commonly reported in this form of inflammation. The most robust features were granulomatous response and vacuolar degeneration of epithelial cells. Thus, these two parameters were adopted in the histopathology scoring system in addition to the previously reported classic features of SBMIE. Exposure to suboptimal environment neither induced inflammatory response nor it aggravated pathological features of SBMIE. The classic features developed within one week after SBM feeding without any significant influence from the environment. Granulomatous response and vacuolar degeneration developed within three and two weeks after feeding SBM, respectively. Granulomatous response was associated with the presence of foamy macrophages which were mainly alcian-blue positive. This may be an indication of mucin engulfing by foamy macrophages under this pathologic condition. Furthermore, epithelial cysts were formed mainly at the site of fusion of mucosal folds in association with granulomatous response. Cysts contained cytokeratin-positive material suggesting that these structures may be composed of epithelial cells debris. Significant extrusion of mucosal cells into the intestinal lumen was associated with SBMIE and the epithelial origin of these cells were confirmed by cytokeratin immunohistochemistry. Immunostaining of DI tissue sections with proliferating cell nuclear antigen revealed pattern of changes similar to that of SBMIE, indicating that cell regeneration occurs in accordance with progression of inflammation. In this experiment plasma D-lactate level did not increase in fish challenged by SBM and/or suboptimal environment, but this could be due to sampling in a short time after feeding which may not have allowed sufficient time for intestinal fermentation to occur. Moreover, suboptimal environment alone did not induce inflammatory response in DI of rainbow trout. However, SBMIE was associated with additional pathological conditions to the commonly known features of SBMIE in rainbow trout expressing more pronounced macrophage response. The results in this thesis suggest that exposure of rainbow trout to suboptimal environmental conditions such as hypoxia does not affect the degree of neither the classic nor the variant features of SBMIE.

Overall, the results obtained from this thesis indicate that SBMIE is associated with disturbed gut mucosal barrier function in rainbow trout. This was confirmed based on the results from two *in vivo* markers, plasma D-lactate and PCR-based bacterial detection. In the second experiment, plasma D-lactate level did not increase in response to dietary and environmental challenges but this might partly be explained by the short sampling time after feeding. Furthermore, suboptimal environment showed to aggravate digestive function of rainbow

trout fed a challenging plant-based diet. The suboptimal environment, however, showed no further aggravation of the pathological changes that characterized SBMIE in the DI of rainbow trout. The inflammatory condition in response to dietary challenge in this thesis was associated with many additional uncommon pathological features, including vacuolar degeneration of epithelial cells and granulomatous inflammation. Reduced water flow rate did not induce or aggravate these pathological features.

Sammendrag

Akvakulturindustrien står ovenfor mange utfordringer, inkludert tilgang på nok bærekraftige fôrråvarer av høy kvalitet og endringer i klimaet. En stor andel av dagens laksefôr består av planteingredienser som inneholder ulike antinæringsstoffer (ANFs). ANFs kan påvirke vekst, fôrutnyttelse og helsen hos fisk. I tillegg er akvakulturproduksjonen utfordret av stadige endringer i miljøet, som kan endre viktige vannkvalitetsparametere som direkte eller indirekte kan påvirke helsen og ytelsen til fisken. Både fôret og miljømessige faktorer kan påvirke tarmens slimlag og skade tarmbarrieren. Alene trenger ikke disse utfordringene være et problem, men med flere faktorer sammen, kan problemer oppstå. Det komplekse miljøet i mage-tarmkanalen (GIT) består bl.a. av mikroorganismer, næringsstoffer, antinæringsstoffer og giftstoffer, noe som gjør at dette organet er utsatt for sykdommer. Imidlertid har tarmen utviklet en barrierefunksjon som hindrer inntrengning av uønskede mikroorganismer og stoffer fra tarmlumen. Funksjonen til slimhinnebarrieren er regulert på en slik måte at den ikke skal forstyrre absorpsjon av næringsstoffer, vann og elektrolytter, og barrierefunksjonen har en avgjørende rolle i å opprettholde tarmens homeostase. Når slimhinnebarrieren påvirkes negativt av ulike eksterne faktorer som fôr eller miljø, kan integriteten til denne første forsvarslinje svekkes, og dette kan igjen føre til forstyrrelser i tarmens homeostase. Tarmens evne til å fordøye næringsstoffer er også følsom for endringer i både fôrets sammensetning og miljø. Ettersom absorpsjon er en av nøkkelrollene til tarmen, er denne parameteren undersøkt under mange forskjellige forhold. Forstyrrelse av tarmen homeostase og slimhinnebarrierens funksjon kan påvirke fordøyelseskapasiteten, og ulikefiskearter kan reagere forskjellig på slike utfordringer. Det er derfor viktig å skaffe mer kunnskap om slimhinnebarrieren og undersøke hvor sensitive ulike fisker er. Videre er det viktig å forstå hvordan samspillet mellom ulike fôr og miljømessige utfordringer kan påvirke fiskens tarmens homeostase og slimhinnebarrierer. Det er derfor viktig å undersøke effekt av ulike faktorer på tarmhomeostase og hvordan dette påvirker tarmbarriere og fordøyelsesfunksjon.

For å utvide vår kunnskap om tarmens barrierefunksjon, ble et *in vivo* forsøk utført med regnbueørret (*Oncorhynchus mykiss*) som fikk fôr basert på fiskemel (FM) eller økende nivåer av soyamel (SBM) som utfordring for å indusere soya-indusert enteritt (SBMIE). Tarmens barrierefunksjon ble vurdert i forhold til SBMIE ved å bruke de mest brukte *in vivo* markørene fra forskning på mennesker og pattedyr: plasma D-laktat, endotoksiner, oralt administrerte

sukkerarter (sukralose, laktulose og L-rhamnose), og PCR-basert deteksjon av bakteriell translokasjon. Oralt administrerte sukkermolekyler ble tilsatt i fôret tre dager før prøvetaking. Det høyeste inkluderingsnivået på 37,5% SBM i fôret resulterte i SBMIE i baktarmen (DI). Plasma D-laktat nivået økte lineært med økende grad av SBM nivå i fôret uten at øket D-laktatkonsentrasjon ble observert i tarminnholdet. PCR-basert deteksjon av bakterier i plasma avslørte at risikoen for bakteriell translokasjon økte i fisk med SBMIE. Verken plasma endotoksin eller sukralose:l-rhamnose (S:R) ratioen var signifikant forskjellig mellom fisk med og uten SBMIE. Plasma laktulose:l-rhamnose ratioen (L:R) økte i fisk med SBMIE. Plasmanivået av sukkermarkørene, viste imidlertid stor variasjon mellom individer. Disse resultatene tyder på at plasma D-laktat og PCR-basert detektering av bakteriell translokasjon kan være egnede *in vivo* markører for å studere tarmbarriere hos laksefisk.

Et annet forsøk ble utført for å vurdere om miljøutfordringer kan forverre effekten av et plantebasert fôr på tarmbarrierefunksjon, graden av SBMIE og fordøyelseskapasiteten i regnbueørret. I dette forsøket ble fiskene utfordret med et fôr med 40% SBM, og utsatt for enten normal eller redusert vannstrømningshastighet som førte til henholdsvis optimale eller suboptimale miljøforhold (d.v.s. normale eller lave nivåer av oksygen i vannet). Forsøket ble delt inn i en 4-ukers tilpasningsperiode (Periode 1) og en 7 ukers forsøksperiode (Periode 2). I periode 1., ble fisken tilvendt til FM (kontroll) og SBM diettene og fiskene ble holdt på optimalt vannmiljø. I periode 2, ble fisken utsatt for suboptimalt miljø med konstant fôring av samme fôr (FM eller SBM) eller utsatt for endringer i kostholdet (FM til SBM) under konstante optimalt miljø eller utsatt for begge utfordringene (FM til SBM og optimal til suboptimalt miljø). Graden av SBMIE økte ikke i respons til det suboptimale miljøet; men graden av SBMIE var generelt høy i de fleste av de SBM-fôrede fiskene, noe som indikerer at graden av SBMIE kan ha maskert en eventuell ytterligere forverring av tarmhelsen p.g.a. miljøutfordringen. Derimot ble lipid- og stivelses-fordøyeligheten ytterligere redusert i fisk fôret med SBM og utsatt for suboptimalt miljø, sammenlignet med fisk fôret med samme diett, men holdt på optimalt miljø. Resultatene tyder på at det var en samspillseffekt av plantebasert diett og miljøutfordring på fordøyelseskapasiteten i regnbueørret. Det kan også tyde på at endringer i fordøyelsen kan være en mer følsom parameter i forhold til SBMIE, når man vil studere samspillet mellom kosthold og miljøutfordringer.

I en detaljert studie av SBMIE i regnbueørret, ble det oppdaget patologiske forandringer som ikke har tidligere blitt rapportert i forbindelse med denne form for betennelse. De mest

fremtredende nye parameterne var granulomatøs respons og vakuolær degenerasjon av epitelcellene. Dermed ble disse to parametrene også inkludert i skåringssystemet for de histopatologiske undersøkelsene i tillegg til de tidligere rapporterte klassiske parameterne for SBMIE. Eksponering for suboptimal miljø induserte verken en betennelsesreaksjon eller forverret de patologiske trekkene ved SBMIE. De klassiske parameterne ble utviklet innen en uke etter start av SBM-fôring uten nevneverdig påvirkning fra omgivelsene. Granulomatøs respons og vakuolær degenerasjon utviklet seg i løpet av henholdsvis tre og to uker etter fôring med SBM. Granulomatøs respons var assosiert med tilstedeværelse av skummende makrofager som var hovedsakelig positive for Alcian-blåfarging. Dette kan være en indikasjon på at under denne type patologiske tilstand, kan mucin tas opp direkte av skummende makrofager. Videre, i forbindelse med de granulomatøse responsene, ble epiteliale cyster hovedsakelig observert der slimhinnefoldene går sammen. Cystene inneholdt cytokeratin-positivt materiale, noe som tyder på at disse strukturene kan være sammensatt av rester av epitelceller. Betydelig tap av slimhinneceller til tarmlumen var assosiert med SBMIE og den epiteliale opprinnelsen av disse cellene ble bekreftet v.h.a. immunhistokjemisk farging for cytokeratin. Immunfarging av vevssnitt fra baktarmen med PCNA (proliferating cell nuclear antigen) viste typiske endringsmønster for SBMIE, noe som indikerer at regenerering av celler finner sted i tråd med utviklingen av betennelsen. I dette forsøket økte ikke plasma D-laktat nivået i fisk fôret med SBM og/eller ved suboptimalt miljø, men dette kan skyldes prøvetaking kort tid etter fôring, slik at det ikke var tilstrekkelig tid for økt forekomst av tarmgjæring. Resultatene viste også at eksponering av regnbueørret til suboptimale miljøforhold ikke påvirket graden av de klassiske parameterne for diagnostisering av SBMIE. Videre viste resultatene at suboptimalt miljø alene induserer ikke en betennelsesreaksjon i DI hos regnbueørret. Men under våre eksperimentelle forhold ble SBMIE assosiert med flere patologiske parametere enn de vanlige velkjente parameterne for SBMIE i regnbueørret. Dette kan tyde på at tarmimmunresponsen hos regnbueørret viste et nytt mønster med økt makrofagaktivitet.

Resultatene i denne avhandlingen viser at SBMIE kan være assosiert med nedsatt barrierefunksjon i tarmmucosa hos regnbueørret. Dette ble bekreftet på grunnlag av resultatene fra to *in vivo* markører; plasma D-laktat og PCR-basert deteksjon av bakterier i plasma. Men konsentrasjonen av plasma D-laktat i det andre forsøket økte ikke som følge av diett- og/eller miljøutfordringene, men dette kan delvis forklares med prøvetaking kort tid etter fôring. Videre viste det seg at det suboptimale miljøet ytterligere reduserte

fordøyeligheten av næringsstoffer i regnbueørret som var fôret med et plantebasert fôr. Men det suboptimale miljøet gav ikke ytterligere forverring av de patologiske parameterne som kjennetegner SBMIE i baktarmen hos regnbueørret. Betennelsestilstanden i DI som ble utløst etter fôring med SBM dietten, var i denne avhandlingen forbundet med flere uvanlige patologiske parametere, inkludert vakuolær degenerasjon av epitelceller og granulomatøs betennelse, men disse ble ikke forverret p.g.a. redusert vanngjennomstrømning i fisketankene.

List of papers

Paper I

Mosberian-Tanha, Peyman; Øverland, Margareth; Landsverk, Thor; Reveco, Felipe E.; Schrama, Johan W.; Roem, Andries J.; Agger, Jane W.; Mydland, Liv Torunn.
Bacterial translocation and *in-vivo* assessment of intestinal barrier permeability in rainbow trout (*Oncorhynchus mykiss*) with and without soybean meal-induced inflammation.
Journal of Nutritional Science, 2016; 5, e26 (10 pages).

Paper II

Mosberian-Tanha, Peyman; Schrama, Johan W.; Landsverk, Thor; Mydland, Liv Torunn; Øverland; Margareth.
The effect of plant-based diet and suboptimal environmental conditions on digestive function and diet-induced enteropathy in rainbow trout (*Oncorhynchus mykiss*).
Aquaculture Nutrition, Submitted 2016.

Paper III

Mosberian-Tanha, Peyman; Landsverk, Thor; Press, Charles McLean; Schrama, Johan W.; Mydland, Liv Torunn; Øverland, Margareth.
Granulomatous enteritis in rainbow trout (*Oncorhynchus mykiss*) challenged by soybean meal regardless of water dissolved oxygen level as an environmental challenge
In preparation.

Abbreviations

ADC	apparent digestibility coefficient
ANF	anti-nutritional factors
DGGE	denaturing gradient gel electrophoresis
DI	distal intestine
DNA	deoxyribonucleic acid
DO	dissolved oxygen
FM	fish meal
GIT	gastrointestinal tract
IBD	inflammatory bowel disease
IEC	intestinal epithelial cell
LAL	limulus amebocyte lysate
LCFA	long-chain fatty acid
LPS	lipopolysaccharides
L:R	lactulose: l-rhamnose
MGC	multi-nucleated giant cell
NSP	non-starch polysaccharide
PCNA	proliferating cell nuclear antigen
PCR	polymerase chain reaction
*p*NA	*p*-nitroaniline
SBM	soybean meal
SBMIE	soybean meal-induced enteritis
SCFA	short-chain fatty acid
SNV	supranuclear vacuole
S:R	sucralose: l-rhamnose
TAN	total ammonia nitrogen
TJ	Tight junction

Introduction

Plant ingredients in aquafeed

Fishmeal (FM) has been traditionally used as the main protein source in salmonids feed production. However, due to the increase in demand for fish meal and limited availability of wild fish, there is a need to find alternative feed ingredients. As a result, inclusion of alternative feed ingredients and their contribution to the sustainability of aquaculture has been debated. In this context, special attention has been paid to plant ingredients due to their widespread availability, low cost and minor effect on the environment (Gatlin *et al.,* 2007). There are, however, some disadvantages associated with use of plant ingredients in fish diets. These ingredients are known to contain a wide range of anti-nutritional factors (ANFs), including fibre and antigenic proteins (Francis *et al.,* 2001). Thus, depending on their source and inclusion level, plant ingredients may adversely affect growth performance, nutrient digestibility, health and welfare of the fish (Gatlin *et al.,* 2007; Krogdahl *et al.,* 2010).

Various types of ANFs are found in a wide range of plant ingredients, including legumes (Francis *et al.,* 2001). Some ANFs can be removed after heat treatment of the feed such as hydrothermal processing, however, other types are heat resistant and may cause nutritional and physiological problems at sufficiently high levels. The concentration and predominance of the heat stable ANFs differ amongst the plant ingredients. For example, saponins are present in most legume-derived meals but the highest concentration is found in soybean meal (SBM) (Francis *et al.,* 2001; Krogdahl *et al.,* 2010).

SBM is known to induce inflammatory response in distal intestine (DI) of salmonid fish resulting in SBM-induced enteritis (SBMIE) (Baeverfjord & Krogdahl 1996; Krogdahl *et al.,* 2003). Feeding SBM to salmonids has also shown to reduce growth performance in a number of studies (Dabrowski *et al.,* 1989; Rumsey *et al.,* 1994; Krogdahl *et al.,* 2003; Collins *et al.,* 2012). SBM inclusion has also shown to decrease digestibility of nutrients and energy in Atlantic salmon (*Salmo salar*) (Opstvedt *et al.,* 2003) and rainbow trout (*Oncorhynchus mykiss*) (Romarheim *et al.,* 2006). Furthermore, altered activity of digestive enzymes in different intestinal regions of Atlantic salmon in response to dietary SBM has been reported (Krogdahl

et al., 2003; Chikwati *et al.*, 2013b). ANFs are suggested to be at least partly, causative factors in altered nutrient digestion. Different types of ANFs are present in SBM, the function of which are not yet fully understood (Francis *et al.*, 2001). However, some experiments attempted to understand the impact of certain types of ANFs on nutrient digestibility. Reduced digestibility of lipids are typically reported in salmonids fed SBM (Refstie *et al.*, 2000; Romarheim *et al.*, 2006; Øverland *et al.*, 2009) and is suggested to occur due to the presence of alcohol-soluble components of soybeans (Olli & Krogdahl 1995). In an experiment, soyasaponin was shown to reduce digestibility of lipids and digestive enzyme activity in DI of Atlantic salmon (Chikwati *et al.*, 2012). Reduction in digestibility of lipid may be related to reduced bile acid level as bovine bile salts addition to SBM diet increased biliary bile salts level and digestibility of lipid in rainbow trout (Yamamoto *et al.*, 2007). Non-starch polysaccharides (NSP) may also reduce digestibility of nutrients and energy by increasing the viscosity of the digesta (Leenhouwers *et al.*, 2006).

The impaired digestive function may partly be related to the morphological changes caused by SBMIE. It has been suggested that DI may contribute to the nutrient digestibility through absorption of nutritionally important components such as cysteine and taurine (Dabrowski *et al.*, 1986; Nordrum *et al.*, 2000b). Morphological changes associated with SBMIE may disturb the capacity of digestion and re-absorption of nutritionally important components in the DI and thus contribute to the lower digestibility of nutrients. However, in Atlantic cod (*Gadus morhua*), development of SBMIE in response to SBM feeding has not been reported (Refstie *et al.*, 2006), but it has shown to reduce digestibility of lipid (Førde-Skjærvik *et al.*, 2006).

Histology of the gastrointestinal tract (GIT)

The structure of the GIT wall of fish and mammals share similarities; however, there are regional variations. The GIT in fish and mammals also differ in anatomy, for example, while subdivisions within small and large intestine are well recognised in mammals, such divisions are not clear in fish. The intestine in salmonid fish can be divided into three major parts, pyloric caeca, mid-intestine and DI. Pyloric ceca is a highly folded region increasing the surface area for digestion (Veillette *et al.*, 2005; Clements & Raubenheimer 2006). The number and size of the caeca differ among different fish species (Hossain & Dutta 1996). Histologically, mucosa of pyloric ceca is similar to that of the mid-intestine with the same cell types. This region is also considered as the main part of the intestine for nutrient uptake

(Nordrum *et al.*, 2000a). DI has less nutrient absorptive capacity but shows more phagocytic activity (Buddington & Diamond 1987).

GIT wall consists of different layers in fish and mammals: Mucosa, submucosa, muscularis and serosa. Mucosa consists of epithelium, and lamina propria. Mucosal epithelium consists of columnar epithelial cells (Fig.1). These cells have digestive and protective role in the GIT. Mucus cells produce mucins, which are the main components of mucus and contribute to the barrier function of the GIT (see details in *Barrier function*) and protection against gastric acid in stomach. In stomach, epithelium includes secretory cells with digestive function (see details in *Digestive function*). In mammals, these cells are HCl-secretory oxyntic cells and chief cells which release pepsinogen and gastric lipase. In fish, both functions are implemented by only one type of secretory cells, called oxynticopeptic cells. In stomach, columnar epithelium forms gastric pits (faveolus) covered by mucus cells. Mucosal gastric glands produce gastric juice and open into the bases of the gastric pits. Stem cells and endocrine cells are also present in the gastric glands and the latter produce hormones such as serotonin.

In mammalian small intestine, projections called villi increase surface area for digestion and absorption of nutrients. Villi are covered by epithelial cells with numerous microvilli on their apical surface. In fish, however, villi are absent and mucosa forms intestinal fold with the same function of increasing surface area. Intestinal epithelial cells (IEC) consist of enterocytes with digestion and absorption function (see details in *digestive function*), and mucus-producing goblet cells with protective role, and in many fishes, rodlet cells with proposed immune function. In mammals, intestinal crypts are located between the villi and are called crypts of Lieberkuhn. Crypts are not found in many fishes including salmonids. Crypts contain Paneth, endocrine and stem cells. Mucosa of colon in mammals lacks villi but has long crypts and epithelium consists of absorptive cells and increased number of goblet cells compared to that in small intestine. Paneth cells, however, are absent in this region. In salmonid fish, DI mucosa has a similar histology to that of proximal regions but contains more goblet cells.

Lamina propria is a connective tissue containing nerve plexus, leukocytes and blood vessels. In mammals underneath lamina propria lays a layer of smooth muscle, called muscularis mucosa. Compared to the lamina propria, submucosa is a deeper and looser connective tissue found under muscularis mucosa. In Atlantic salmon, muscularis mucosa and submucosa are

reported in stomach; however, they are not found in intestinal regions (Løkka *et al.*, 2013). In this fish, underneath lamina propria, stratum compactum, a compact collagen structure, has been reported in stomach and all intestinal regions (Løkka *et al.*, 2013). Muscularis consists of two layers of muscle, inner circular (*muscularis circularis*) and outer longitudinal (*muscularis langitudinalis*) layers. Muscularis contains blood vessels, as well as nerve plexus, which regulates contraction of the intestine, an essential function for mixing and pushing the luminal contents along the intestine. Serosa is a thin layer of connective tissue and contains blood vessels.

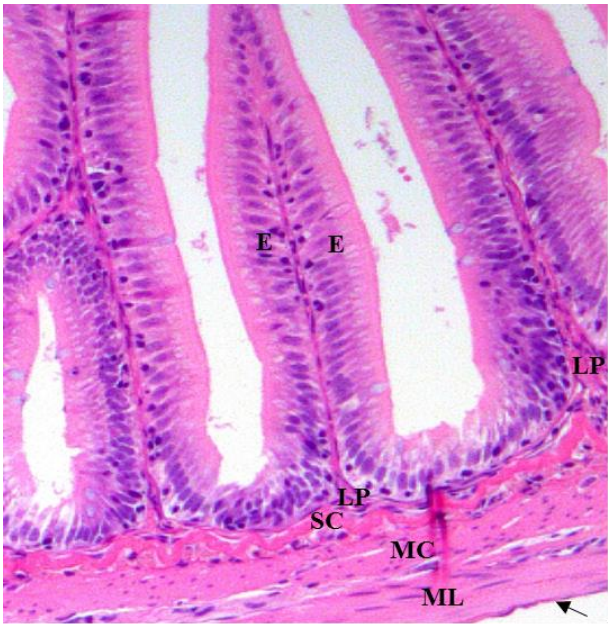

Figure 1: Histology of distal intestinal tissue of rainbow trout. E: epithelium; LP: lamina propria; SC: stratum compactum; MC: inner *muscularis circularis*; ML: outer *muscularis langitudinalis*; Serosa (arrow).

The function of the GIT

Digestive function

Hydrolysis of macronutrients and release of their small constituents is a common basic function of the GIT in mammals and fish. Digestive enzymes secreted from stomach and pancreas break down macronutrients into smaller molecules, which are further degraded by the brush border enzymes located on the apical surface of enterocytes. The product of the brush border enzymes are small molecules, which are transported across the epithelium and absorbed into the circulation.

In stomach, low pH induced by secretion of gastric acid (i.e. hydrochloric acid, HCl) leads to protein denaturation and activation of pepsinogen, a proteolytic enzyme that hydrolyses peptide polymers. HCl lysis in stomach also ruptures plant cell walls and releases cell contents for further enzymatic processes (Lobel 1981). HCl and pepsinogen are secreted by oxynticopeptic cells in fish gastric glands; however, in mammals the gastric gland cells are differentiated. In these organisms, HCl is produced in oxyntic (parietal) cells and pepsinogen in chief cells (Smit 1968). In the gastric mucosa, endocrine cells control secretion of gastric juices and goblet cells produce mucins with protective role against HCl. Muscle contractions in stomach mixes the digesta with gastric secretions, which results in production of chyme.

The chyme enters the intestine by peristaltic movements for further digestion process. Digestion of the chyme is continued and absorption of nutrients occurs in the intestine. Gallbladder secretions and pancreatic juice, containing digestive enzymes and bicarbonate, enter the intestine through the common duct. Pancreatic enzymes include trypsinogen, chymotrypsinogen, proelastase, carboxypeptidase, aminopeptidase, procollagenase, pancreatic lipase, phospholipase and α-amylase. The products of pancreatic enzymes are small peptides, free amino acids, 2-monoglycerides, free fatty acids, lysophospholipids, maltose and branched oligosaccharides (Rust 2002). Secretion of gallbladder contains bile salts, which are produced in the liver, and contribute to digestion and absorption of lipids through emulsification of lipid droplets and formation of micelles. Enterokinase of brush borders activates pancreatic trypsinogen in the lumen. Active trypsin in turn, activates chymotrypsinogen, proelastase and procollagenase. Amylase activity differs among different fish species and in salmonids as carnivores, the activity is lower than in omnivorous fishes (Hidalgo *et al.*, 1999).

Enterocytes are a category of IECs with central role in digestion and absorption process of food. Enterocytes express Na^+/K^+-ATPase, with crucial role in nutrient transport and ion regulation. On the apical surface of these cells, finger-like microvilli form brush border to increase intestinal surface area. The digestive function of enterocytes is performed by various digestive enzymes located in brush border membrane (Kuz'mina & Gelman 1997). These enzymes include aminopeptidase, carboxypeptidase, mono- and triglyceride lipase, wax ester hydrolase and amylase. The products of these enzymes are small peptides, free amino acids, 2- monoglycerides, free fatty acids, glycerol, fatty alcohols and monosaccharides. Peptides

and proteins can alternatively be absorbed directly from the lumen and transported across brush border membrane through pinocytosis (Stroband & Kroon 1981; Watanabe 1984). Endocrine cells in the intestinal region regulate digestion process by releasing hormones such as cholecystokinin and secretin. This function is necessary to control contraction of gallbladder and secretion of pancreatic juice (including digestive enzymes and bicarbonate) (Rust 2002). Colon in mammals is the site of fermentation due to the presence of large number of microflora. The fermentation process in these microorganisms contribute to the maintenance of intestinal homeostasis, partly, through production of short chain fatty acids (SCFA) (Thorburn *et al.*, 2014). Microflora are in cross communication with IECs and mucosal immune system, boosting the health of the intestine and contributing to the digestive function. In fish, digestive and absorptive function of the epithelium is reduced gradually along the intestine and replaced by mucus secretory function of the goblet cells. In some experiments, the role of DI in digestive function of fish such as pinocytosis of proteins (Watanabe 1984) and reabsorption of taurine (Nordrum *et al.*, 2000b) has been studied.

Barrier function

One of the important functions of the GIT is protection of the internal milieu from exogenous antigens, microorganisms and harmful substances originated form food and/or environment (Fig. 2). Intestine is an important segment of the GIT due to its significant digestive/absorptive function and the presence of enormous bacterial population. Thus, maintenance of intestinal homeostasis and health conditions directly affect health and survival of human and animals. Maintenance of intestinal homeostasis, under optimum conditions, is achieved through balanced interactions among commensal bacteria, IECs and mucosal immune system.

Epithelial cells along the GIT create chemical and physical barrier by expression of paracellular tight junctions (TJ) and secretion of mucus. Development and maintenance of a physiological barrier for protection is crucial to land-based and aquatic animals as well as human. Disturbance of this physiological barrier adversely affects performance, physiology and health of animals. Under homeostasis, intestinal mucosa absorbs nutrients while preventing unwanted and harmful substances or microorganisms from entering the internal milieu. Loss or impairment of the intestinal mucosal barrier integrity or function has been suggested as a risk factor for sepsis in human (Balzan *et al.*, 2007).

Mucosal barrier function has physical and immunological components. Mucous synthesis and secretion by the goblet cells creates a viscous layer along luminal surface of the GIT in fish and mammals (Shephard 1994; Goto & Kiyono 2012) and provides a physical barrier against pathogens (Ellis 2001). Mucus layer is a porous network containing mucin glycoproteins, anti-microbial peptides, cytokines and antibodies (McGuckin *et al.,* 2011), which is an indication of immunological barrier function of mucus. Mucins, the main constituents in mucus layer, are glycoproteins formed and packed into granules after *O*-glycosylation and *N*-terminal oligomerisation (Thornton *et al.,* 2008). Some mucins are synthetized as cell surface mucins (or membrane-bound mucins) by enterocytes and goblet cells (Kim & Ho 2010). These glycoproteins are transported to the cell membrane and are involved in apical glycocalyx complex and signal transduction (McGuckin *et al.,* 2011). Mucus is secreted as a two-layer complex; outer layer is exposed to the luminal environment and commensal bacteria, while the inner layer is not accessible to bacteria under homeostasis (McGuckin *et al.,* 2011). In mammals, mucus function is strengthened by the presence of anti-microbial molecules produced and secreted into the mucus by Paneth cells. Paneth cells are a category of IECs, which have not been identified in fish. However, intestinal epithelium in fish contains rodlet cells with proposed immune function (Manera & Dezfuli 2004).

IECs are able to produce substances with important role in immunity such as cytokines, chemokines and anti-microbial peptides. These substances improve mucosal immunity by activation of immune cells and maintenance of microflora homeostasis (Goto & Kiyono 2012). Contribution of IECs in fish immunity is not fully understood, however, studies have revealed that IECs of rainbow trout challenged by bacteria and fungus can produce cytokines (Jirillo *et al.,* 2007; Komatsu *et al.,* 2009). Activity of mucosal immune cells and secretion of immunological substances are regarded as the immunological function of the mucosal barrier.

Adjacent epithelial cells are connected via TJ proteins at the apical surface membrane, which are essential for the GIT epithelium integrity and paracellular barrier function (Schneeberger & Lynch 2004). TJs form small pores allowing water and solutes to flow through paracellular route (Schneeberger & Lynch 2004). In saline environment, regulation of ion and water influx is crucial for osmoregulation and adaptation to increased water salinity. In Atlantic salmon, intestinal TJs gene expression has been shown to increase in salt-water, indicating a paracellular response to change in salinity via regulation of TJ proteins (Tipsmark *et al.,* 2010; Tipsmark & Madsen 2012). Various types of TJ proteins have been identified in the GIT

epithelium and research is ongoing to understand details of their structural and barrier function. The most studied TJs in fish and mammals are members of the claudin and occludin families. Claudins have been suggested to participate in paracellular permeability regulation in fish and mammals (Van Itallie & Anderson 2004; Bagherie-Lachidan *et al.,* 2008). Occludins are actively involved in cell polarity or "fence" function and also physical barrier of the epithelium (Tsukita & Furuse 1999).

Microflora have been suggested to participate in mucosal barrier function through their metabolic products (e.g. SCFA) (Thorburn *et al.,* 2014) and communication with the mucosal immune cells (Goto & Kiyono 2012). Intestinal lumen contains various types of microorganisms, which creates a very complex and competitive environment. Dominance of commensal microflora in this environment, adversely affects colonisation of pathogenic bacteria, thus contributing to the function and health of intestinal mucosal barrier (Cain & Swan 2010).

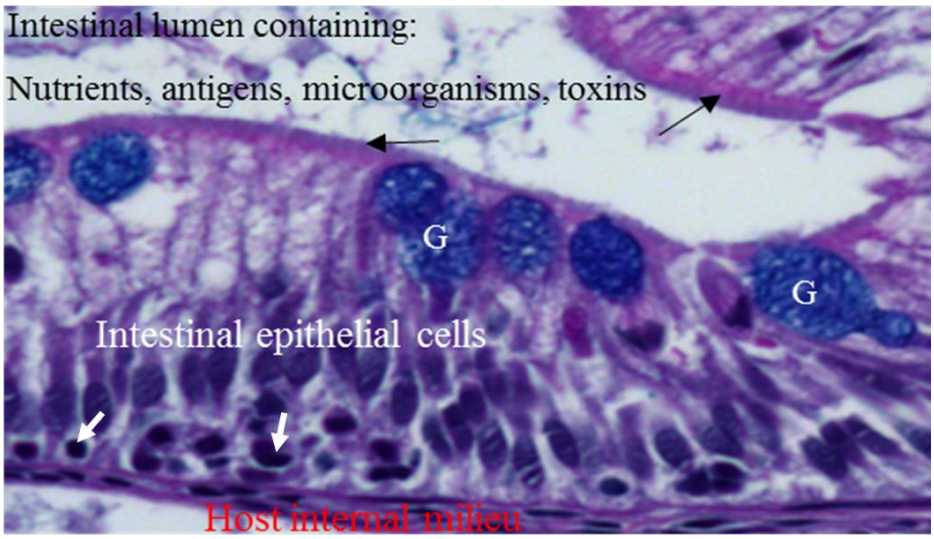

Figure 2: Intestinal mucosal barrier of rainbow trout. Mucosal barrier is a complex system including mucus layer which is directly exposed to the luminal contents covering apical part of the epithelial cells. Other constituents of intestinal mucosal barrier are epithelial cells with absorptive and barrier function. Mucosal barrier is further supported by mucosal immune cells such as lymphocytes (white arrows) scattered through the epithelium and lamina propria. Mucosal barrier allows translocation of nutrients across the epithelium while excluding passage of microorganisms and harmful substances into the host internal milieu. Black arrows indicate apical brush borders. G: goblet cells.

Disturbance of intestinal homeostasis

Intestinal homeostasis is maintained through communication among IECs, mucosal immune system and microflora. Under homeostasis, mucosal barrier permeability is regulated by a process, which allows nutrients and harmless small molecules to pass through the epithelial layer while avoiding entrance of potentially harmful agents such as bacteria, viruses, toxins and antigens. When intestinal homeostasis is disturbed in response to various dietary and environmental factors, luminal agents and bacteria (commensals and pathogens) may translocate across the mucosal barrier. Translocation of bacteria and their antigens is sensed by epithelial cell receptors, triggering the mucosal immune response and initiation of inflammation (Xavier & Podolsky 2007).

There has been efforts to understand the mechanisms of mucosal barrier impairment resulting in increased intestinal barrier permeability and disturbed homeostasis. One of the proposed causes of increased mucosal barrier permeability is the alteration in structure of paracellular junctional complex (Arrieta *et al.,* 2006; Anderson & Van Itallie 2009). Several experiments have attempted to understand the mechanisms of this alteration. It has been suggested that pathogens and food antigens may increase paracellular permeability through zonulin pathway. They may trigger release of zonulin into the lumen which in turn stimulates receptors located on epithelial cells, promoting phosphorylation of TJs and increased permeability (Arrieta *et al.,* 2006). Pathogens, however, may directly interact with TJs and facilitate their intrusion (Bergelson 2009). Under stressful conditions, increased colonic paracellular permeability was observed to be associated with phosphorylation of myosin light chain (MLC) in experimental rats (Ferrier *et al.,* 2003; Ait-Belgnaoui *et al.,* 2005). In this process, MLC kinase is activated through interferon-gamma (IFN-γ), produced predominantly by T-lymphocytes, and results in contraction of the epithelial cells and opening of the TJs (Ferrier *et al.,* 2003).

Diet-induced interruption of intestinal homeostasis

ANFs are among various dietary factors, which may disturb intestinal homeostasis. The mechanism of their effect is not yet fully known. The most widely used plant protein ingredient in animal feed is SBM, which has been shown to induce inflammation in DI of salmonids (van den Ingh *et al.,* 1991; Baeverfjord & Krogdahl 1996; Burrells *et al.,* 1999; Krogdahl *et al.,* 2003). Development of SBMIE has also been reported in the DI of common carp (*Cyprinus carpio* L.) with similar immunological and morphological features to that in salmonids (Urán

et al., 2008). Pea protein concentrate at 35% inclusion level has shown to induce inflammatory response in DI of Atlantic salmon with similar aspects to that of soybean meal-induced inflammation (Penn *et al.,* 2011). Sensitivity and susceptibility to plant-based diets may differ among different fish species and plant ingredients sources and their inclusion levels. A comparative study have revealed that rainbow trout is more tolerant to nutritional and pathophysiological implications of dietary SBM than Atlantic salmon (Refstie *et al.,* 2000). Various types of SBM from different commercial sources have also shown to cause SBMIE with different severity (Uran *et al.,* 2009). Soyasaponins are one the ANFs proposed to be involved in development of SBMIE either as a contributing factor to the aetiology of the enteropathy (Knudsen *et al.,* 2008; Chikwati *et al.,* 2012) or as the cause of the inflammatory response (Krogdahl *et al.,* 2015). Commonly reported features of SBMIE are reduced number of enterocytic supranuclear vacuoles (SNV), infiltration of leukocytes into the lamina propria, atrophy of intestinal folds and increased number of goblet cells. Soybean agglutinin (SBA), an ANF in SBM, has shown to bind *in vivo* to IECs suggesting a link between SBA and histopathological changes in DI (Buttle *et al.,* 2001). In Atlantic salmon, dietary inclusion of SBM and soyasaponins, increased intestinal permeability *in vitro* (Knudsen *et al.,* 2008). Another experiment in piglets showed that high SBA inclusion resulted in increased intestinal barrier permeability *in vivo* and reduced occludin protein expression (Zhao *et al.,* 2011).

Environment-induced interruption of intestinal homeostasis

Alteration in environmental parameters, could be challenging to the fish and result in disturbance of intestinal homeostasis. It has been argued that intestinal barrier function is depressed in response to corticosteroid secretion under stressful conditions (Meddings & Swain 2000). The fish welfare and health is affected by numerous environmental conditions such as change in oxygen level, water temperature, acidity and salinity. Suboptimal environmental conditions such as hypoxia may cause stress and has shown to be associated with increased intestinal permeability *in vitro* in Atlantic salmon (Sundh *et al.,* 2010). Stress has shown also to increase intestinal permeability and bacterial translocation in mammals (Groot *et al.,* 2000; Velin *et al.,* 2004; Pearce *et al.,* 2012). Water dissolved oxygen (DO) is one of the important environmental factors affecting the fish health and metabolism. Water DO is subject to change by different factors, including water temperature and exchange rate. Hypoxic conditions has shown to result in impaired intestinal mucosal barrier function in Atlantic salmon accompanied by morphological changes in posterior intestine (Sundh *et al.,* 2010). Hypoxia has also reported

to increase mucosal neutrophil infiltration in Atlantic salmon (Niklasson *et al.*, 2011).

The interaction of a challenging environment such as stressful conditions with intestinal inflammation has been studied in mammals. In an experiment on rat, stress increased the degree of trinitrobenzenesulfonic acid (TBN)-induced colitis (Gue *et al.*, 1997). In fish, interaction between environment and diet-induced inflammation is not known. Change in water quality parameters such as increased temperature, oxygen depletion and increased salinity, may challenge the fish and enhance the negative effects of dietary ANFs on intestinal homeostasis. Therefore, the present thesis aimed to investigate whether exposure of rainbow trout to suboptimal environment aggravates the effect of a dietary challenge on digestive function and intestinal homeostasis.

Aims of the study

The present work aimed to investigate the interactive effect of a challenging diet containing plant ingredient (i.e. SBM) and a challenging environment (i.e. reduced water flow rate leading to suboptimal environmental condition) on intestinal homeostasis and digestive function in rainbow trout. For this purpose, measurements of the intestinal mucosal barrier function, nutrients digestibility and histopathological evaluation of diet-induced enteropathy in rainbow trout were performed. To evaluate the mucosal barrier function, the use of suitable markers was necessary. Thus, the thesis also provides information about assessment of intestinal mucosal barrier function in rainbow trout with SBMIE, by commonly used *in vivo* markers in human and mammals.

To fulfil the aim of the thesis the following objectives were perused:

- Evaluation of different markers for assessment of intestinal mucosal barrier permeability *in vivo* in rainbow trout (Paper I).

- Assessment of intestinal mucosal barrier function in relation to SBMIE (Paper I).

- Investigation of the interactive effects of a dietary challenge and suboptimal environment on digestive function of rainbow trout (Paper II).

- Investigation of whether the effect of a dietary challenge on intestinal morphological changes and mucosal barrier function of rainbow trout is aggravated by suboptimal environment (Paper III).

Methodology

In this section, the methods used to evaluate mucosal barrier function and histopathological changes in DI of rainbow trout in response to the treatments are presented. Biochemical analyses and PCR-based bacterial detection were used to evaluate *in vivo* intestinal permeability and bacterial translocation rate, respectively (Paper I). Routine histology procedures were used to prepare tissue specimen for microscopic observation and morphological evaluation to study the health status of DI (Paper I, II and III). Further, immunohistochemistry was applied to identify and label specific cellular proteins of interest in tissue specimens (Paper III). Development of SBMIE, which is a known inflammatory response to dietary SBM, was used in the thesis as a model of intestinal inflammation and more specifically, diet-induced intestinal enteropathy (Paper I, II and III). Evaluation of intestinal mucosal barrier function in fish with SBMIE model of inflammation was performed (Paper I). Digestive function of the GIT was addressed by measuring the apparent digestibility coefficient (ADC) of nutrients (Paper II).

Evaluation of SBM-induced enteritis

In Paper I, blinded assessment of DI tissue sections was performed by scoring four morphological parameters of SBMIE. This protocol is based on the criteria used previously to study SBMIE in salmonids (Baeverfjord & Krogdahl 1996; Refstie *et al.*, 2006; Romarheim *et al.*, 2013). Rainbow trout seems to be more tolerant to SBMIE as shown previously (Refstie *et al.*, 2000) and thus, different SBM inclusion levels were applied to examine the degree of morphological changes in response to different doses of SBM. Results from this study (Paper I) was used to formulate a SBM-based diet for induction of SBMIE at a moderate/mild degree in other study (Paper II and III).

A different evaluation protocol was used in Paper II and III following microscopic observation of uncommon pathological features of SBMIE. The new protocol adopted three morphological parameters previously documented in studies of SBMIE (including in Paper I), atrophy, the degree of supranuclear vacuolisation of epithelial cells and the degree of mucosal leukocyte infiltration. These are referred to as “classic” morphological parameters of SBMIE in this thesis (Paper II and III). The new features of SBMIE were granulomatous

response and vacuolar degeneration of epithelial cells. The distinction between vacuolar degeneration and the presence of goblet cells was made following Alcian blue-Periodic acid Schiff (AB-PAS) staining of the tissue sections. AB-PAS staining allowed identification of acid (blue) and neutral (red) mucins in goblet cells (Paper III) (Fig.3).

Inflammation is a complex process involving multiple components. For evaluation of inflammation, an effort was made to identify the most robust criteria. The average score of morphological parameters was used to assess the general status or degree of the inflammation (Paper I and II). Detailed study of each parameter, their degree of change and any possible influence on tissue cell composition and target protein localisation was performed using appropriate and relevant immunohistochemical analysis (Paper III).

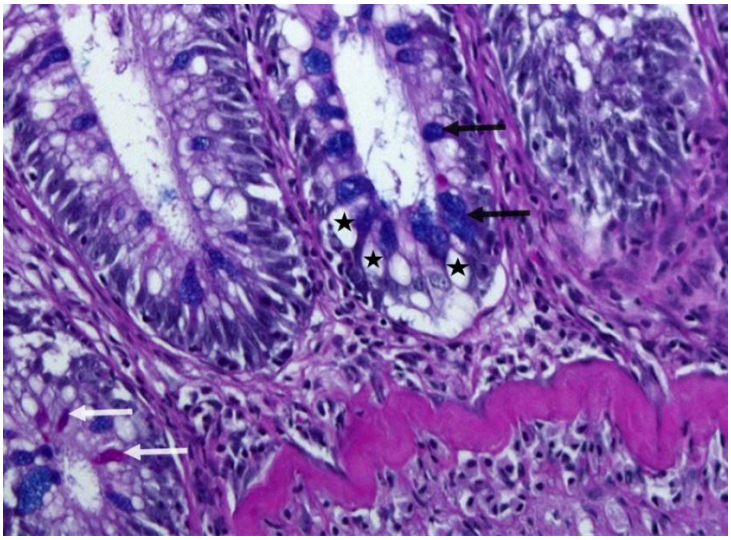

Figure 3: Distal intestinal tissue section of rainbow trout with soybean meal-induced enteritis. Distinction between goblet cells and epithelial cells with vacuolar degeneration was made following Alcian blue - Periodic acid Schiff (AB-PAS) staining. In this micrograph, large number of cells containing acidic (blue) mucins are seen (black arrows). However, a few cells containing neutral (red) mucins are also present (white arrows). Cells with vacuolar degeneration are distinguished (★).

Assessment of the degree of granulomatous response (Fig.4) was performed based on the degree of changes that included foamy (enlarged) macrophages, multi-nucleated giant cells (MGCs) and the subepithelial proliferation of fibroblasts (Paper III)

Mycobacteria are known to cause infiltration of enlarged macrophages which sometimes fuse into MGC at the site of inflammation, an important step in development of granulomatous lesion. These macrophages contain acid-fast mycobacteria if induced by such pathogens. Thus, in our study, Ziehl-Neelsen staining was performed to investigate the possible presence of mycobacteria.

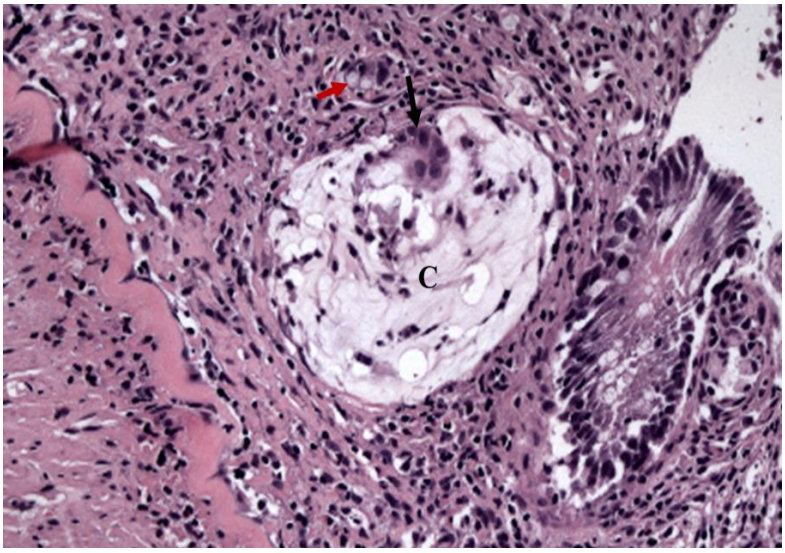

Figure 4: Subepithelial granulomatous inflammation in rainbow trout with soybean meal-induced enteritis (SBMIE). This pathological feature is characterised by the presence of multi-nucleated giant cells (MGCs) (black arrow), epithelioid cells (enlarged macrophages) and proliferation of fibroblasts. Granulomatous areas are surrounded by many lymphocytes. The presence of foamy macrophages, a form that macrophages often acquire (red arrow) and cyst (C) are indicated.

Assessment of intestinal barrier function

Intestinal barrier function has been evaluated in human and animals to understand the cause and consequence of diseases such as various forms of enteropathy. Different methods have been used to assess intestinal mucosal barrier function. The methods have been developed based on the conception that under intestinal homeostasis, translocation of bacteria and antigens are prevented by the intestinal barrier function. Orally administered large molecules and bacterial products (e.g. D-lactate) are not normally absorbed or their absorption is limited under homeostasis and cannot be metabolised by human and animals. Damage or loss of intestinal barrier function may result in translocation of bacteria, their products and orally administered sugar markers into the circulation. Further, these markers will appear in urine, thus, plasma or

urinary presence and/or concentration of these substances can give information on the status of mucosal barrier function (Grootjans *et al.,* 2010).

Evaluation of mucosal barrier function in a specific segment of the GIT is possible by using appropriate markers. Bacterial products and some types of orally administered sugar markers are often used as intestinal (small intestine and colon) *in vivo* permeability markers. Presence of bacteria in circulation is also an indication of intestinal barrier loss or impairment. Thus, translocation rate of bacteria is used as an *in vivo* marker for assessment of intestinal mucosal barrier status. Orally administered sugar markers that are not digested by digestive enzymes and not fermentable by intestinal bacteria are used as *in vivo* permeability markers for assessment of colonic mucosal barrier function in mammals.

In this thesis, bacterial products and orally administered sugar markers are referred to as *in vivo* permeability markers. The presence of bacteria in plasma was also used as a method for evaluation of intestinal mucosal barrier integrity *in vivo*. The large molecular sugar markers appear in urine after translocation into the circulation; as a result, also urine samples can be taken to measure these markers in human and mammalian models. In fish, however, due to practical reasons, plasma samples were used to detect and measure the level of these markers (Paper I).

In vivo measurement of intestinal barrier permeability

Plasma levels of orally administered sugar markers and bacterial products, endotoxin and D-lactate were measured to assess intestinal barrier permeability *in vivo*. Sugar markers have been used in human and mammals as an "active" assessment of mucosal barrier function (Grootjans *et al.,* 2010). In Paper I, sucralose, lactulose and l-rhamnose were added to the diets as orally administered sugar markers. High-pressure liquid chromatography (HPLC) is commonly performed to detect sugar markers for *in vivo* permeability tests. In Paper I, high-performance anion exchange chromatography (HPAEC) combined with pulsed amperometric detection (PAD) (Dionex) was used to analyse sugar markers in plasma. This system has been used as a powerful technique to separate different classes of carbohydrates in food science (Morales *et al.,* 2008; Pico *et al.,* 2015). Hydroxyl group of carbohydrates are transformed into oxyanion at high pH, which are then separated by HPAEC column. PAD oxidises and detect the separated molecules as they pass through the detector. In this study (Paper I), dietary

inclusion levels of sugar markers was the first issue to address. The amount of each sugar marker per percentage of body weight in human studies was used as a reference in Paper I. However, this amount was doubled in the feed to ensure sufficiently high intake of each marker for detection. After determination of sugar marker levels in plasma, the ratio of disaccharides (lactulose and sucralose) to monosaccharide (l-rhamnose) were calculated and used as an indication of intestinal barrier function in line with previous experiments in human (Anderson *et al.*, 2004; van Wijck *et al.*, 2013).

The limulus amebocyte lysate (LAL) assay was used to determine plasma endotoxin levels. This method is regarded as a "passive" assessment of mucosal barrier function (Grootjans *et al.*, 2010). Endotoxins (lipopolysaccharides, LPS) form part of the outer membrane of Gram-negative bacteria and are known to be toxic. Endotoxins cause coagulation in the haemolymph of horseshoe crab (*Limulus Polyphemus*) through activation of enzymes in primitive blood cells (amebocytes) (Cohen 2000). This principle has been used to produce LAL assays for determination of endotoxins. Originally, detection of endotoxin has been based on formation of gel clot after incubation with lysate. A more recently developed and precise chromogenic LAL test (Iwanaga 2007) was used in the present work (Paper I). This method is based on activation of a proenzyme upon the presence of endotoxin leading to the release of *p*-nitroaniline (*p*NA) from a chromogenic substrate (a synthetic peptide). The free *p*NA exhibits a colour, which is measured photometrically. Endotoxin levels in samples are calculated from a standard curve of known endotoxin concentrations.

D-lactate is produced by intestinal bacteria through fermentation of non-absorbed carbohydrates. D-lactate cannot be metabolised and is thus excreted in urine. This has made D-lactate a commonly used *in vivo* permeability marker in human and mammals. The absorption of small amounts of D-lactate has been reported in healthy humans, but if intestinal barrier function is impaired or lost, higher amounts of D-lactate cross the intestinal mucosa. Thus, plasma D-lactate level could be used as an estimate for intestinal barrier function (Paper I). D-Lactate is measured by using a specific enzyme, D-lactate dehydrogenase, which does not react with L-lactate and generates a proportional colorimetric product measured at 450 nm.

PCR-based bacterial translocation

PCR has proven to be more sensitive than conventional culture methods in detecting bacteria (Kane *et al.,* 1998; Schoeffel *et al.,* 2000). In Paper I, nested PCR was utilised which is a two-step PCR, resulting in increased sensitivity of the detection method. This process starts with amplification of a larger bacterial 16S rDNA fragment followed by amplification of a smaller targeted DNA fragment within the first fragment. The target bacterial DNA sequence in Paper I was the hypervariable (V) 3 region of 16S rDNA. 16S rDNA is considered as a tool for classification of bacteria (Woese 1987) which has been commonly targeted for bacterial analysis. Along the 16S rDNA, sequence divergence is not evenly distributed but concentrated in the so-called "V-regions". Thus, these regions have been evaluated for phylogenetic analysis (Stackebrandt & Goebel 1994; Kim *et al.,* 2011). DNA samples from each fish were subjected to primary PCR aiming at amplification of a larger outer fragment, which contained the smaller targeted fragment (V3 region of 16S rDNA). PCR products of the first round were subjected to amplification of the V3 region of the bacterial 16S rDNA (intended fragment; nested PCR).

Immunohistochemical analysis

Immunohistochemistry is a method used for identification and localisation of proteins in tissue sections. The principle of this method is that labelled antibody binds to target antigen and this interaction can be detected microscopically. In this thesis (Paper III), primary monoclonal antibodies (mAb), where directed against target antigens and primary antibody-antigen interaction was visualised with the use of secondary antibody conjugated with avidin/ biotinylated enzyme-horseradish peroxidase (HRP) complex.

The two primary antibodies used in Paper III were anti- proliferating cell nuclear antigen (PCNA) mouse mAb (Dako, Oslo, Norway) and anti-cytokeratin mouse mAb (Zymed® Laboratories, San Francisco, CA, USA). PCNA is a nuclear protein and a co-factor of DNA polymerase δ and is essential for DNA replication. PCNA expression is increased at the S phase of the cell cycle (Maga & Hubscher 2003). Anti-PCNA mouse mAb has been used in salmonids in previous experiments (Romarheim *et al.,* 2011; Venold *et al.,* 2012). Cytokeratins are keratin-containing proteins, predominantly produced by epithelial cells; thus, anti-cytokeratin antibodies are used as markers for detection and localization of epithelial cells. These markers have been used widely to detect tumor cells of epithelial origin

in human. In this thesis (Paper III), anti-cytokeratin mouse mAb (AE1/AE3) was used. AE1/AE3 is a mixture of two different clones of anti-cytokeratin mAb, allowing detection of various types of cytokeratins (except cytokeratin 18). This antibody has been used previously to identify cytokeratins in rainbow trout (Markl *et al.*, 1989) and in a study of adenocarcinoma in Atlantic salmon (Dale *et al.*, 2009).

Results and discussion

In addition to the challenges related to aquafeed production and specifically the use of plant ingredients, aquaculture is also challenged by changes in the environment such as alterations in temperature, acidity or DO. This thesis is based on the hypothesis that exposure to suboptimal environment aggravates the effect of a challenging plant-based diet on digestive function and intestinal homeostasis in rainbow trout. To address possible interactive effects on digestive function, macronutrient digestibility were measured over time after exposure to dietary and environmental challenges (Paper II). The status of intestinal homeostasis was evaluated by monitoring the progression of SBMIE and *in vivo* assessment of intestinal mucosal barrier function in rainbow trout over time (Paper III). The knowledge about *in vivo* assessment of intestinal mucosal barrier permeability in fish was limited before starting this thesis. Furthermore, evaluation of intestinal mucosal barrier function in response to dietary and environmental challenges required suitable markers. Thus, the results from the dose response study (Paper I) are important and provide information about the use of selected *in vivo* markers in rainbow trout and also intestinal mucosal barrier function under SBMIE condition (Paper I).

Evaluation of *in vivo* markers

Sugar markers

In human and mammals, sugar molecules are given orally to individuals in solution followed by collection of urine samples at different time points. Thus, the amount of sugar molecules consumed by each individual is known, which allows accurate estimation of intestinal barrier permeability under different conditions. In fish, sugar molecules were given to a group of fish within each tank which does not allow for registration of individual consumption of feed containing these molecules and thus the assessment of intestinal barrier is less accurate. To overcome this problem, fish could be kept individually in separate tanks, but this is often not practical or economically justified. Variation in feed intake among fish within each tank in the present study could confound the results in this experiment (Paper I). Thus, the large individual variation in level of sugar markers in plasma could partially be explained by individual variation in feed intake.

In Paper I, the level of sucralose was below the detection limit in many fish and as a result calculation of the S:R ratio was limited to six individuals: three from FM diet and three from 37.5% SBM diet. Sucralose with three chlorine ions is a highly electronegative molecule while lactulose and l-rhamnose are highly hydroxylated. This difference in chemical properties of the markers may affect sensitivity of their detection, possibly, explaining the non-significant results for sucralose.

Translocation of bacteria and their products

Gut translocation of bacteria and their products across intestinal mucosa are used as methods to assess mucosal barrier function. In healthy individuals, translocation of bacteria at low rates occurs which has beneficial effects on function and regulation of immune system (Sedman *et al.,* 1994; Balzan *et al.,* 2007). It has been reported that the incidence of bacterial translocation ranges from 5 to 10% among healthy humans (Balzan *et al.,* 2007). Establishing a baseline for mucosal barrier permeability and bacterial translocation rate is considered as an important step in clinical research. In fish, there is no information about the baseline translocation of bacteria or mucosal barrier permeability. In Paper I, bacterial detection rate in plasma in certain groups was based on the number of PCR-DGGE positive individuals (i.e. bacterial DNA fragment detected and further identified by DGGE).

Many studies also investigate translocation of bacterial products across mucosal barrier as bacteria translocation is not the only factor with potential harmful consequences. It is also known that bacterial products can translocate across the mucosal barrier independent of bacteria itself (Balzan *et al.,* 2007). Endotoxin and D-lactate were the two bacteria-derived substances selected as *in vivo* permeability markers in Paper I. Endotoxin has shown to translocate into circulation in healthy human at levels below 1 EU/ml (Nadhazi *et al.,* 2002). Feeding increasing levels of SBM to fish did not change plasma endotoxin levels significantly and the level of this marker was below 0.1 EU/ml. There are various factors affecting gut microflora (including gram negative bacteria) composition and population. Diet, body temperature and also environmental factors may affect gram negative bacteria population and thus affecting luminal endotoxin production. It is also possible that endotoxins are cleared by the function of the mucosal immune system. Plasma D-lactate was significantly increased in fish fed the 37.5% SBM diet and statistical analysis showed significant linear increase in plasma D-lactate with increasing SBM inclusion level. This led to the hypotheses that

translocation of D-lactate may have occurred in response to dietary treatment, independent of any intestinal morphological changes or impaired barrier integrity. For example, under certain clinical conditions, such as bacterial overgrowth and carbohydrate malabsorption, plasma D-lactate level has shown to increase up to a level causing acidosis (Hove & Mortensen 1995). However, analysis of D-lactate in DI contents of fish fed the 37.5% SBM diet did not show increased concentration of this marker compared to those fed the FM diet (Paper I). This strengthened the hypothesis that there is a relationship between SBMIE and increased translocation of D-lactate into circulation. In some experiments, D-lactate has shown to correlate with plasma endotoxin levels (Sun *et al.,* 2001), however in this study such correlation was not found which may be explained, at least partly, by the lack of significant differences among treatment groups in endotoxin level.

Assessment of intestinal mucosal barrier in relation to SBMIE

Possible changes in intestinal barrier permeability in response to SBMIE was investigated (Paper I). Significant increase in the mean score of the classic morphological parameters was observed for the fish fed 37.5% SBM (Paper I). The mean score corresponded to a moderate degree of inflammation. Ten of 15 fish in this treatment developed a classic SBMIE with varying degrees. Only one fish from the 25% SBM treatment showed a classic SBMIE at moderate level. This could be explained by differences in individual feed intake among fish within the same treatment group. Differences in susceptibility to SBM could also cause individual variation in development of inflammation. Among different species of fish, response to a dietary challenge may also differ. For example, it has been shown previously that rainbow trout is more resistant to pathophysiological effects of SBM (Refstie *et al.,* 2000). One of the aims of the study was to understand the relation between SBMIE and the function of intestinal mucosal barrier *in vivo*. Thus, all the fish with SBMIE were compared to non-SBMIE fish on individual basis, regardless of their dietary treatment. Many SBM-fed fish, including five individuals in 37.5% SBM dietary group did not develop SBMIE, and thus these fish along with fish fed the FM control were included in non-SBMIE group.

Despite the large individual variation in sugar markers level in the plasma of rainbow trout in Paper I, fish with SBMIE, showed higher plasma L:R ratio compared to fish with no signs of SBMIE (Paper I). The increased plasma L:R ratio was in agreement with previous publications assessing mucosal barrier in small intestine of human (van Wijck *et al.,* 2013).

Plasma S:R ratio, however, was not increased in the fish with SBMIE in contrary to human inflammatory bowel disease (IBD) studies (Anderson *et al.,* 2004; van Wijck *et al.,* 2013). However, sucralose was not detected in most of the fish in this study. L-rhamnose is a monosaccharide, which is absorbed by enterocytes under normal/healthy conditions. Reduced plasma level of this sugar in fish with SBMIE (Paper I) is in agreement with human studies where small intestinal inflammation or injury reduced plasma level of l-rhamnose (Bjarnason *et al.,* 1995). This could be a consequence of cellular damage or immaturity leading to impairment in monosaccharide intracellular transport.

Bacterial translocation rate in fish with SBMIE (28%) tended to be higher than that in the fish without SBMIE (8%). This is in accordance with previous publications showing increased bacterial translocation rate under intestinal inflammation or injury conditions in human (Wiest & Rath 2003; Balzan *et al.,* 2007). An odds ratio (OR) was also performed to determine the relative probability or risk of bacterial translocation in SBMIE and non-SBMIE fish (Paper I). The odds of bacterial translocation was found to be 4.5-fold higher in fish with SBMIE than that in non-SBMIE fish. This indicates that under experimental conditions in Paper I, the risk of bacterial translocation was 4.5 times higher in fish with SBMIE. It is not yet fully known how bacteria or their products can cross the mucosal barrier; however, scientific evidences suggest that translocation could occur through both of the known routes of paracellular (through tight junctions) and transcellular (through IECs).

Plasma level of endotoxin did not differ significantly between SBMIE and non-SBMIE groups of fish (Paper I). It is possible that translocating endotoxin under SBMIE were cleared by phagocytic activity of mucosal immune cells before entering the circulation. Gut associated lymph tissue (GALT) in teleost fish is more diffuse compared to mammals and gut mucosa of these fishes are equipped with large number of intestinal epithelial T-lymphocytes enabling effective local immune response (Rombout *et al.,* 2011). Plasma level of endotoxin did not increase significantly in PCR-positive group of fish compared to PCR-negative group. This may be due to the smaller number of PCR-positive (n=7) than PCR-negative (n=53) individuals.

D-lactate was found to increase significantly in fish with SBMIE compared to that in non-SBMIE fish (Paper I). Most of the fish in SBMIE group was fed 37.5% SBM (10 of 11); however, the lack of increased luminal level of D-lactate in response to high dietary SBM

inclusion rules out the effect of diet-induced luminal fermentation on plasma level of D-lactate. Thus, it is likely that impaired mucosal barrier function has led to elevated plasma D-lactate under SBMIE conditions. A weak but significant correlation was also observed between D-lactate and degree of SBMIE implying that other factors than SBMIE could also be involved in translocation of this marker.

Overall these results showed that SBMIE was associated with impaired intestinal mucosal barrier function in rainbow trout. D-lactate and bacterial translocation were increased under SBMIE condition and are suggested to be suitable markers of *in vivo* mucosal barrier permeability in rainbow trout. Furthermore, these results suggest that feed-added markers such as sugar molecules may not give reliable estimates in group-feeding system.

Effect of dietary challenge on digestive function at suboptimal environment

In this thesis (Paper II), digestive function of the GIT was evaluated using ADC values of macronutrients. Optimal environment was created by optimal water flow rate (7.5 L min^{-1}) leading to DO level of above 8 mg L^{-1}in the outlet. Suboptimal environment was induced by reduction in water flow rate (2.25 L min^{-1}). This in turn resulted in water DO level of below 6 mg L^{-1} in the outlet. Reduced ADC of lipid is a known consequence of feeding SBM to salmonids (Krogdahl *et al.*, 2003; Romarheim *et al.*, 2006). In line with previous publications, SBM resulted in significant reduction of ADC of lipid in period 1, when all the fish was kept under optimal conditions (Paper II). ADC of starch, however, was not significantly affected. Exposure of FM-fed fish to suboptimal conditions in period 2 neither aggravated ADC of nutrients nor resulted in development of SBMIE. However, compared to the fish fed SBM but kept at optimal environment, the environmental challenge resulted in further reduction of ADC of lipid and starch at the end of period 2. The degree of SBMIE did not differ among all the three SBM-fed treatments (regardless of their environmental conditions). These results indicate that there is an interaction between dietary challenge and suboptimal environment on ADC of lipid and starch (Paper II) and this pattern of change was not related to the degree of SBMIE. The increased water concentration of TAN at suboptimal environment during week 5 of period 2 was small but significant. Rainbow trout at suboptimal conditions may have been more sensitive to any additional challenge even at slight levels. This could explain the reduction of feed intake (percentage of body weight) during the last two weeks of the experiment. However, no significant correlation was found between feed intake and ADC of

nutrients, which may imply that the changes in ADC values were also independent of the changes in the feed intake. Overall, these results indicate that the change in ADC of lipid and starch among the fish fed SBM and kept at different environments in Paper II is related to the environmental conditions. The fish was observed to have reduced activity under these conditions compared to the fish kept under optimal conditions, which is in line with a previous observations on Nile tilapia (*Oreochromis niloticus*) (Tran-Duy *et al.*, 2012). As biological activities such as respiration and swimming are oxygen demanding, the fish under hypoxic conditions may reduce these activities as a response to the challenge of reduced water DO level (Kramer 1987). Reduced activity of the fish may result in slower peristaltic movement of the GIT. As a result, interaction of ANFs with lipid and starch may have increased due to prolonged retention of the digesta in the GIT of rainbow trout kept at suboptimal environment. The suboptimal environment may also have increased the interactions between carbohydrates and lipids in the GIT, resulting in amylose-lipid complexes, which has shown to increase resistance of amylose to α-amylase (Holm *et al.*, 1983).

Although the same faeces collection method was used for all treatments in this study, it cannot be ruled out that leaching rate of the nitrogenous compounds was higher from the faeces of SBM-fed fish compared to FM-fed fish. This may be partially explained by the differences in faecal consistency as salmonids fed SBM have shown to have reduced dry matter content in the faeces (Refstie *et al.*, 2000). Thus, the increased ADC of crude protein of SBM diet compared to that of the FM diet might be a result of a leaching effect. However, it has been shown that ADC of lipid does not change in response to different methods of faeces collection due to their insolubility in aqueous environment (Storebakken *et al.*, 1998; Vandenberg & De La Noüe 2001). Furthermore, in this study (Paper II), ADC of starch in period 1 did not differ between FM and SBM diets, indicating that, as with ADC of lipid, starch digestibility may not be affected by the possible leaching effect of the faeces collection method.

Overall these results suggest that the suboptimal environment did not induce or aggravate SBMIE or adversely affect the ADC of nutrients in rainbow trout. Feeding a challenging diet to rainbow trout under suboptimal environmental conditions further reduced digestibility of starch and lipid without change in the degree of SBMIE compared to the fish fed the same diet but kept at optimal environment. This indicates that there was an interaction between plant-based diet and exposure to suboptimal environmental conditions on digestive function of rainbow trout.

Effect of dietary challenge on intestinal inflammation and barrier permeability at suboptimal environment

Histology results from the dose-response study (Paper I) was used as a basis for the formulation of the SBM-based diet used in Paper II and III. The inclusion of 37.5% SBM in diets led to a moderate SBMIE in DI of rainbow trout. Thus 40% SBM was used in Paper II and III aiming for a moderate inflammatory response in DI of rainbow trout to allow studying the interactive effects of dietary and environmental challenges on intestinal mucosal barrier function and the morphological changes in DI. Suboptimal environment alone did not adversely affect the morphological parameters, as it is evident in FM-fed fish kept at suboptimal environment. Combination of environmental and dietary challenge (i.e. SBM) did not aggregate the effect of SBM on the degree of morphological parameters. This is in contrary to what was found for ADC of starch and lipid (Paper II). In the present study, however, fish expressed more severe SBMIE, which may have concealed any additional effect of the environment. The mean score of classic parameters of SBMIE (leukocyte infiltration, supranuclear vacuolisation of epithelial cells and atrophy of intestinal folds) was higher than 2 (score 2 indicated a moderate change) in all groups fed SBM (Paper III).

Detailed study of SBMIE revealed pathological changes that have not been commonly reported under SBMIE conditions (Paper III). In addition to classic morphological changes often reported in tissue samples with SBMIE, granulomatous response characterised by presence of MGCs, foamy macrophages and proliferation of fibroblasts in the lamina propria were also observed. Foamy macrophages are monocytes engulfing material of endogenous origin. These macrophages were mostly found positive for acidic (blue) mucins, however, a few were also positive for neutral (red) mucins indicating that they could contain mucins. Thus, these cells may represent or resemble muciphages, a fraction of foamy macrophages containing mucins, which have been described previously in human in connection with tissue injury (Sagaert *et al.*, 2012). Epithelial cells with vacuolar degeneration were also identified after AB-PAS staining of DI tissue sections. Substantial cell extrusion into the intestinal lumen resulting in denudation of lamina propria were also evident. The epithelial origin of the extruded cells was further confirmed by immunohistochemistry against cytokeratins (Paper III). Extrusion of apoptotic IECs occur in healthy tissue as a part of epithelial turnover

process (Blander 2016). However, under inflammatory conditions, the degree of cell death and further extrusion is increased, which may disturb mucosal barrier integrity. Fusion of intestinal folds and epithelial cysts formation was observed in many individuals. Cytokeratin-positive material was detected in some cysts, suggesting that they contained debris of dead epithelial cells. In a few cases irregularity in morphology of cells and their nuclei was characterised as dysplastic changes in epithelium.

Granulomatous response and vacuolar degeneration developed more slowly than the classic parameters of SBMIE during period 2. These features were observed in a large fraction of the individuals with SBMIE. The significant increase in vacuolar degeneration occurred a week earlier than granulomatous response (Paper III). This pathological feature is an indication of a non-lethal cellular damage, which results in necrosis when the stimuli is persistent (Kumar *et al.,* 2010). This feature has been reported in mammalian liver and intestinal tissue under various toxic and infection conditions, such as LPS (Liu *et al.,* 2008) and gram-positive bacterial challenge (Reeves *et al.,* 2012). Vacuolar degeneration has also been reported in Nile tilapia (*Oreochromis niloticus*) intestine in response to toxic material (Younis *et al.,* 2015). Granulomatous response can be associated with use of vaccine adjuvants in animals (Spickler & Roth 2003). It has also been reported and studied in relation to mycobacteriosis in human (Pavlik *et al.,* 2009) and fish (Novotny *et al.,* 2010). Granulomatous response could also be associated with human autoimmune diseases and chronic intestinal inflammation models (Williams & Williams 1983; Lee *et al.,* 1997; Johns *et al.,* 2011). However, they were not previously reported in association with SBMIE in fish. DI tissue sections with granulomatous response were negative for Ziehl-Neelsen staining which indicates that mycobacteria, as a known pathogen inducing this response, was not present in tissues. Granulomatous response was also present in fish fed SBM at optimal environment and the degree of change was not altered by the type of environment. Furthermore, DI tissue sections of the fish fed FM and kept at suboptimal environment did not result in such response. These findings indicate that granulomatous response was likely an effect of SBM diet. However, rainbow trout with SBMIE fed the 37.5% SBM diet in the previous experiment (Paper I) did not show such response. A major difference between Paper I and III in relation to the environment (despite water DO level) was water temperature. Water temperature was higher in Paper III (14 ºC) than in Paper I (average 9 ºC). Cystic absorptive vacuoles (Sealey *et al.,* 2009) and epithelial hyper-vacuolisation with pronounced extrusion of mucosal contents into the lumen (Burrells *et al.,* 1999) were observed previously in rainbow trout fed diets

containing high levels of SBM (43 & 80-89%,respectively) and kept at relatively high temperatures (14 & 14.8 ºC, respectively). Moreover, in Atlantic salmon fed 20% SBM, increase in temperature induced a higher degree of SBMIE (Uran *et al.,* 2008). Histopathological evaluation in Paper III was more detailed compared to the aforementioned publications, using additional staining and immunohistochemistry to characterise the uncommon pathological features. Further studies are required to clarify the potential effect of high temperatures on pathological conditions associated with SBMIE in rainbow trout. Temperatures beyond a certain level may intensify the effects of dietary and/ or environmental harmful factors. Cellular function, metabolism and biological processes could be affected by temperature. This is also relevant to the immune system which has a key role in development and orchestration of the inflammation. For example, it has been shown that sockeye salmon (*Oncorhynchus nerka*) becomes more dependent on specific immune function at higher temperatures (Alcorn *et al.,* 2002).

Increased proliferation of IECs has been reported to occur in association with SBMIE (Romarheim *et al.,* 2011; Chikwati *et al.,* 2013a) and mammalian models of intestinal inflammation (Safatle-Ribeiro *et al.,* 1999; Kaushik & Kaur 2005). This is also evident from PCNA reactivity score in Paper III, which increased significantly in response to SBM feeding. Increased proliferation of IECs is a known response to mucosal cell damage induced by various factors and has shown to increase the risk of epithelial neoplasia in human (Gupta *et al.,* 2007). Exposure of rainbow trout to suboptimal environment reduced PCNA reactivity score in fish fed FM. PCNA reactivity score was not changed within the first two weeks after exposure to suboptimal environment in the fish subjected to change from FM to SBM diet. These results may imply that suboptimal environment may have delayed the process of increased proliferation of epithelial cells in this group of fish. However, continuous challenge with SBM diet has overcome this possible effect of the environment raising the PCNA score in this fish after two weeks at suboptimal environment. Reduced water DO level is a key factor associated with suboptimal environment created in Paper III and may be suggested as a potential factor reducing cellular proliferation. These results suggest that the suboptimal environment created in this study, did not induce or aggravated the morphological changes commonly reported in association with SBMIE. Feeding SBM, however, resulted in an uncommon pathological condition including a pronounced macrophage response. This condition was not induced or aggravated in response to the suboptimal environment.

Plasma D-lactate level were much lower than the range reported in Paper I and the level was not significantly different between FM- and SBM-fed fish during period 2. Plasma D-lactate was even higher in FM-fed fish in period I. SBMIE was more severe in Paper III than that reported in Paper I with increased degree of tissue damage. Dietary composition and environmental conditions are among parameters affecting intestinal fermentation activity, however, it is possible that sampling time in this study was at least a contributing factor. Sampling was performed 1 hr after feeding and finished in about three hours (four hours after feeding). Considering the short time between feeding and sampling, the intestinal fermentation activity may have been reduced significantly due to limitation on time and availability of intestinal digesta to microflora. The range of plasma D-lactate in healthy fish without pathophysiological changes in their gut morphology is not known. The results from Paper I may give some suggestions but more experiments are required under different dietary and environmental conditions to produce a more reliable baseline. Thus, insignificant change in plasma D-lactate should not be interpreted as evidence that there was no change in mucosal barrier integrity and function. Delayed sampling time or use of more appropriate *in vivo* marker for this specific condition could produce strong evidence of mucosal barrier impairment. However, significant epithelial damage evident from histopathological evaluation along with pronounced immune response within lamina propria could at least indicate that the mucosal integrity is seriously challenged.

Conclusions

- Plasma D-lactate and PCR-based bacterial detection were found to be suitable markers under the conditions described in Paper I. *In vivo* markers, however, may behave differently under different conditions.

- As in mammalian intestinal inflammation, SBMIE, was associated with increased mucosal barrier permeability based on increased plasma D-lactate level and higher risk of bacterial translocation based on PCR-based bacterial detection.

- Digestive function may be a more sensitive parameter than morphological changes to detect interactive effect of plant-based diet and suboptimal environmental conditions. The effect of SBM inclusion in diet to induce a dietary challenge on digestive function of rainbow trout was intensified when the fish was also exposed to low water oxygen level as an environmental challenge. This additional effect of a suboptimal environment, however, was not evident for the diet-induced enteropathy in distal intestine of rainbow trout.

- SBMIE was associated with uncommon pathological features such as granulomatous response and vacuolar degeneration of epithelial cells in addition to the commonly known morphological changes. Reduced water oxygen level as an environmental challenge did not induce or aggravate such pathological features.

- Overall, diet-induced enteropathy is associated with disturbed gut mucosal barrier function in rainbow trout. Interaction of SBM-based diet and reduced water oxygen level as an environmental challenge aggravated the digestive function of rainbow trout while the degree of SBMIE was unaffected. Plasma D-lactate did not increase in response to dietary and environmental challenges but this might, at least partly, be explained by the short sampling time after feeding. SBMIE was associated with uncommon pathological features such as granulomatous enteritis. Reduced water flow rate did not induce or aggravated such pathological features. It is possible that environmental factors such as temperature, which were not associated with reduced water flow rate, may have contributed to the development of these features.

Implications and future perspectives

The thesis revealed the following areas requiring further investigations for salmonid fish:

- Study of translocation of bacteria or their products under different dietary and environmental conditions needs further investigation.

- The relationship between diet-induced enteropathy and loss or impaired distal intestine mucosal barrier function may differ among different salmonid species, thus further specie-specific studies is needed.

- It is largely unknown how different environmental challenges may interact with various plant-based diets. Further research is needed to address the interactive effect of different dietary challenges and environmental conditions such as temperature, salinity and acidification. Detailed study of the mechanisms of the interactive effects on digestive function and gut homeostasis should be the aim of the future studies. It is also important to investigate such interactive effects on health and homeostasis of other organs than the gut.

- More knowledge about environmental effects on fish digestive function and gut homeostasis enables aquaculture management to optimise diet formulation or use dietary supplements to counteract the challenges associated with specific environmental conditions.

- Sensitivity of different species of salmonids to the interaction of different dietary and environmental challenges should be further examined.

- Further experiments studying the interactive effect of dietary and environmental challenges on enteropathy and tissue homeostasis, should be carefully designed to induce moderate tissue and immune responses. This may give more clarification of the potential additional effect of environmental factors on these parameters.

Reference list

Ait-Belgnaoui, A., Bradesi, S., Fioramonti, J., Theodorou, V. & Bueno, L. (2005). Acute stress-induced hypersensitivity to colonic distension depends upon increase in paracellular permeability: role of myosin light chain kinase. *Pain,* **113,** 141-147.

Alcorn, S.W., Murray, A.L. & Pascho, R.J. (2002). Effects of rearing temperature on immune functions in sockeye salmon (Oncorhynchus nerka). *Fish Shellfish Immunol.,* **12,** 303-334.

Anderson, A.D.G., Jain, P.K., Fleming, S., Poon, P., Mitchell, C.J. & Macfie, J. (2004). Evaluation of a triple sugar test of colonic permeability in humans. *Acta Physiol. Scand.,* **182,** 171-177.

Anderson, J.M. & Van Itallie, C.M. (2009). Physiology and Function of the Tight Junction. *Cold Spring Harb. Perspect. Biol.,* **1,** a002584.

Arrieta, M.C., Bistritz, L. & Meddings, J.B. (2006). Alterations in intestinal permeability. *Gut,* **55,** 1512-20.

Baeverfjord, G. & Krogdahl, A. (1996). Development and regression of soybean meal induced enteritis in Atlantic salmon, *Salmo salar* L., distal intestine: a comparison with the intestines of fasted fish. *J. Fish Dis.,* **19,** 375-387.

Bagherie-Lachidan, M., Wright, S.I. & Kelly, S.P. (2008). Claudin-3 tight junction proteins in Tetraodon nigroviridis: cloning, tissue-specific expression, and a role in hydromineral balance. *Am. J. Physiol. Regul. Integr. Comp. Physiol.,* **294,** R1638-R1647.

Balzan, S., De Almeida Quadros, C., De Cleva, R., Zilberstein, B. & Cecconello, I. (2007). Bacterial translocation: overview of mechanisms and clinical impact. *J. Gastroenterol. Hepatol.,* **22,** 464-471.

Bergelson, J.M. (2009). Intercellular Junctional Proteins as Receptors and Barriers to Virus Infection and Spread. *Cell Host & Microbe,* **5,** 517-521.

Bjarnason, I., Macpherson, A. & Hollander, D. (1995). Intestinal permeability: An overview. *Gastroenterology,* **108,** 1566-1581.

Blander, J.M. (2016). Death in the intestinal epithelium—basic biology and implications for inflammatory bowel disease. *FEBS J.,* **283,** 2720-2730.

Buddington, R.K. & Diamond, J.M. (1987). Pyloric ceca of fish: a "new" absorptive organ. *Am. J. Physiol.,* **252,** G65-76.

Burrells, C., Williams, P.D., Southgate, P.J. & Crampton, V.O. (1999). Immunological, physiological and pathological responses of rainbow trout (Oncorhynchus mykiss) to increasing dietary concentrations of soybean proteins. *Vet. Immunol. Immunopathol.,* **72,** 277-288.

Buttle, L.G., Burrells, A.C., Good, J.E., Williams, P.D., Southgate, P.J. & Burrells, C. (2001). The binding of soybean agglutinin (SBA) to the intestinal epithelium of Atlantic salmon, Salmo salar and Rainbow trout, Oncorhynchus mykiss, fed high levels of soybean meal. *Vet. Immunol. Immunopathol.,* **80,** 237-244.

Cain, K. & Swan, C. (2010). Barrier function and immunology. In*: Fish Physiol.* ed. Grosell, M., Farrell, A. P. & Brauner, C. J., *pp.*111-134. Academic Press, San Diego, USA.

Chikwati, E., Gu, J., Penn, M., Bakke, A. & Krogdahl, Å. (2013a). Intestinal epithelial cell proliferation and migration in Atlantic salmon, Salmo salar L.: effects of temperature and inflammation. *Cell Tissue Res.,* **353,** 123-137.

Chikwati, E.M., Sahlmann, C., Holm, H., Penn, M.H., Krogdahl, Å. & Bakke, A.M. (2013b). Alterations in digestive enzyme activities during the development of diet-induced enteritis in Atlantic salmon, *Salmo sala*r L. *Aquaculture,* **402–403,** 28-37.

Chikwati, E.M., Venold, F.F., Penn, M.H., Rohloff, J., Refstie, S., Guttvik, A., Hillestad, M. & Krogdahl, Å. (2012). Interaction of soyasaponins with plant ingredients in diets for Atlantic salmon, Salmo salar L. *Br. J. Nutr.,* **107,** 1570-1590.

Clements, K. & Raubenheimer, D. (2006). Feeding and nutrition. In*: The Physiology of Fishes.* 3rd ed. Evans, D. H. & Claiborne, J. B., *pp.*47-82. Taylor and Francis Group, Boca Raton, FL, USA.

Cohen, J. (2000). The detection and interpretation of endotoxaemia. *Intensive Care Med.,* **26,** S051-S056.

Collins, S.A., Desai, A.R., Mansfield, G.S., Hill, J.E., Van Kessel, A.G. & Drew, M.D. (2012). The effect of increasing inclusion rates of soybean, pea and canola meals and their protein concentrates on the growth of rainbow trout: concepts in diet formulation and experimental design for ingredient evaluation. *Aquaculture,* **344–349,** 90-99.

Dabrowski, K., Leray, C., Nonnotte, G. & Colin, D.A. (1986). Protein digestion and ion concentrations in rainbow trout (*Salmo gairdnerii* rich.) digestive tract in sea- and fresh water. *Comp. Biochem. Physiol. A Physiol.,* **83,** 27-39.

Dabrowski, K., Poczyczynski, P., Kock, G. & Berger, B. (1989). Effect of partially or totally replacing fish meal protein by soybean meal protein on growth, food utilization and proteolytic enzyme activities in rainbow trout (*Salmo gairdneri*). New in vivo test for exocrine pancreatic secretion. *Aquaculture,* **77,** 29-49.

Dale, O.B., Tørud, B., Kvellestad, A., Koppang, H.S. & Koppang, E.O. (2009). From chronic feed-induced intestinal inflammation to adenocarcinoma with metastases in salmonid fish. *Cancer Res.,* **69,** 4355-4362.

Ellis, A.E. (2001). Innate host defense mechanisms of fish against viruses and bacteria. *Dev Comp Immunol,* **25,** 827-39.

Ferrier, L., Mazelin, L., Cenac, N., Desreumaux, P., Janin, A., Emilie, D., Colombel, J.F., Garcia-Villar, R., Fioramonti, J. & Bueno, L. (2003). Stress-induced disruption of colonic epithelial barrier: role of interferon-gamma and myosin light chain kinase in mice. *Gastroenterology,* **125,** 795-804.

Francis, G., Makkar, H.P.S. & Becker, K. (2001). Antinutritional factors present in plant-derived alternate fish feed ingredients and their effects in fish. *Aquaculture,* **199,** 197-227.

Førde-Skjærvik, O., Refstie, S., Aslaksen, M. & Skrede, A. (2006). Digestibility of diets containing different soyabean meals in Atlantic cod (*Gadus morhua*); comparison of collection methods and mapping of digestibility in different sections of the gastrointestinal tract. *Aquaculture,* **261,** 241-258.

Gatlin, D.M., Barrows, F.T., Brown, P., Dabrowski, K., Gaylord, T.G., Hardy, R.W., Herman, E., Hu, G., Krogdahl, Å., Nelson, R., Overturf, K., Rust, M., Sealey, W., Skonberg, D., J

Souza, E., Stone, D., Wilson, R. & Wurtele, E. (2007). Expanding the utilization of sustainable plant products in aquafeeds: a review. *Aquacult. Res.,* **38,** 551-579.

Goto, Y. & Kiyono, H. (2012). Epithelial barrier: an interface for the cross-communication between gut flora and immune system. *Immunol. Rev.,* **245,** 147-163.

Groot, J., Bijlsma, P., Kalkeren, A.V., Kiliaan, A., Saunders, P. & Perdue, M. (2000). Stress-Induced Decrease of the Intestinal Barrier Function: The Role of Muscarinic Receptor Activation. *Ann. N. Y. Acad. Sci.,* **915,** 237-246.

Grootjans, J., Thuijls, G., Verdam, F., Derikx, J.P.M., Lenaerts, K. & Buurman, W.A. (2010). Non-invasive assessment of barrier integrity and function of the human gut. *World J. Gastrointest. Surg.,* **2,** 61-69.

Gue, M., Bonbonne, C., Fioramonti, J., More, J., Del Rio-Lacheze, C., Comera, C. & Bueno, L. (1997). Stress-induced enhancement of colitis in rats: CRF and arginine vasopressin are not involved. *Am. J. Physiol. Gastrointest. Liver Physiol.,* **272,** G84-G91.

Gupta, R.B., Harpaz, N., Itzkowitz, S., Hossain, S., Matula, S., Kornbluth, A., Bodian, C. & Ullman, T. (2007). Histologic inflammation is a risk factor for progression to colorectal neoplasia in ulcerative colitis: a cohort study. *Gastroenterology,* **133,** 1099-105; quiz 1340-1.

Hidalgo, M.C., Urea, E. & Sanz, A. (1999). Comparative study of digestive enzymes in fish with different nutritional habits. Proteolytic and amylase activities. *Aquaculture,* **170,** 267-283.

Holm, J., Björck, I., Ostrowska, S., Eliasson, A.C., Asp, N.G., Larsson, K. & Lundquist, I. (1983). Digestibility of Amylose-Lipid Complexes in-vitro and in-vivo. *Starch - Stärke,* **35,** 294-297.

Hossain, A.M. & Dutta, H.M. (1996). Phylogeny, ontogeny, structure and function of digestive tract appendages (caeca) in teleost fish. In*: Fish Morphology Horizon of New Research.* ed. Munshi, J. S. D. & Dutta, H. M., *pp.*59–76. A. A. Balkema Publishers, Brookfield, USA.

Hove, H. & Mortensen, P. (1995). Colonic lactate metabolism andd-lactic acidosis. *Dig. Dis. Sci.,* **40,** 320-330.

Iwanaga, S. (2007). Biochemical principle of Limulus test for detecting bacterial endotoxins. *Proc. Jpn. Acad. Ser. B Phys. Biol. Sci.,* **83,** 110-119.

Jirillo, F., Passantino, G., Massaro, M.A., Cianciotta, A., Crasto, A., Perillo, A., Passantino, L. & Jirillo, E. (2007). In vitro elicitation of intestinal immune responses in teleost fish: evidence for a type IV hypersensitivity reaction in rainbow trout. *Immunopharmacol. Immunotoxicol.,* **29,** 69-80.

Johns, C.E., Topping, J.H., Bloxham, C. & Dhar, A. (2011). Coeliac disease and granulomatous ileocolitis: an association or chance occurrence? *J. R. Coll. Physicians Edinb.,* **41,** 319-22.

Kane, T.D., Alexander, J.W. & Johannigman, J.A. (1998). The detection of microbial DNA in the blood: a sensitive method for diagnosing bacteremia and/or bacterial translocation in surgical patients. *Ann. Surg.,* **227,** 1-9.

Kaushik, S. & Kaur, J. (2005). Effect of chronic cold stress on intestinal epithelial cell proliferation and inflammation in rats. *Stress-the International Journal on the Biology of Stress,* **8,** 191-197.

Kim, M., Morrison, M. & Yu, Z. (2011). Evaluation of different partial 16S rRNA gene sequence regions for phylogenetic analysis of microbiomes. *J. Microbiol. Methods,* **84,** 81-87.

Kim, Y. & Ho, S. (2010). Intestinal Goblet Cells and Mucins in Health and Disease: Recent Insights and Progress. *Curr. Gastroenterol. Rep.,* **12,** 319-330.

Knudsen, D., Jutfelt, F., Sundh, H., Sundell, K., Koppe, W. & Frøkiær, H. (2008). Dietary soya saponins increase gut permeability and play a key role in the onset of soyabean-induced enteritis in Atlantic salmon (*Salmo salar* L.). *Br. J. Nutr.,* **100,** 120-129.

Komatsu, K., Tsutsui, S., Hino, K., Araki, K., Yoshiura, Y., Yamamoto, A., Nakamura, O. & Watanabe, T. (2009). Expression profiles of cytokines released in intestinal epithelial cells of

the rainbow trout, Oncorhynchus mykiss, in response to bacterial infection. *Dev Comp Immunol,* **33,** 499-506.

Kramer, D.L. (1987). Dissolved oxygen and fish behavior. *Environ. Biol. Fishes,* **18,** 81-92.

Krogdahl, A., Gajardo, K., Kortner, T.M., Penn, M., Gu, M., Berge, G.M. & Bakke, A.M. (2015). Soya Saponins Induce Enteritis in Atlantic Salmon (Salmo salar L.). *J. Agric. Food Chem.,* **63,** 3887-3902.

Krogdahl, Å., Bakke-Mckellep, A. & Baeverfjord, G. (2003). Effects of graded levels of standard soybean meal on intestinal structure, mucosal enzyme activities, and pancreatic response in Atlantic salmon (*Salmo salar* L.). *Aquacult. Nutr.,* **9,** 361-371.

Krogdahl, Å., Penn, M., Thorsen, J., Refstie, S. & Bakke, A.M. (2010). Important antinutrients in plant feedstuffs for aquaculture: an update on recent findings regarding responses in salmonids. *Aquacult. Res.,* **41,** 333-344.

Kumar, V., Abbas, A., Fausto, N. & Aster, J. (2010). Cellular responses to stress and toxic insults: adaptation, injury and death. In*: Robbins & Cotran Pathologic Basis of Disease.* 8th ed., *pp.*13-14,. Saunders and Elsevier, Philadelphia.

Kuz'mina, V.V. & Gelman, A.G. (1997). Membrane-linked digestion in fish. *Rev. Fish. Sci.,* **5,** 99-129.

Lee, F.D., Maguire, C., Obeidat, W. & Russell, R.I. (1997). Importance of cryptolytic lesions and pericryptal granulomas in inflammatory bowel disease. *J. Clin. Pathol.,* **50,** 148-152.

Leenhouwers, J.I., Adjei-Boateng, D., Verreth, J.a.J. & Schrama, J.W. (2006). Digesta viscosity, nutrient digestibility and organ weights in African catfish (*Clarias gariepinus*) fed diets supplemented with different levels of a soluble non-starch polysaccharide. *Aquacult. Nutr.,* **12,** 111-116.

Liu, L.-M., Zhang, J.-X., Luo, J., Guo, H.-X., Deng, H., Chen, J.-Y. & Sun, S.-L. (2008). A Role of Cell Apoptosis in Lipopolysaccharide (LPS)-induced Nonlethal Liver Injury in d-galactosamine (d-GalN)-sensitized Rats. *Dig. Dis. Sci.,* **53,** 1316-1324.

Lobel, P.S. (1981). Trophic biology of herbivorous reef fishes: alimentary pH and digestive capabilities. *J. Fish Biol.,* **19,** 365-397.

Løkka, G., Austb∅, L., Falk, K., Bjerkås, I. & Koppang, E.O. (2013). Intestinal morphology of the wild atlantic salmon (Salmo salar). *J. Morphol.,* **274,** 859-876.

Maga, G. & Hubscher, U. (2003). Proliferating cell nuclear antigen (PCNA): a dancer with many partners. *J. Cell Sci.,* **116,** 3051-3060.

Manera, M. & Dezfuli, B.S. (2004). Rodlet cells in teleosts: a new insight into their nature and functions. *J. Fish Biol.,* **65,** 597-619.

Markl, J., Winter, S. & Franke, W.W. (1989). The catalog and the expression complexity of cytokeratins in a lower vertebrate - biochemical-identification of cytokeratins in a teleost fish, the rainbow-trout. *Eur. J. Cell Biol.,* **50,** 1-16.

Mcguckin, M.A., Lindén, S.K., Sutton, P. & Florin, T.H. (2011). Mucin dynamics and enteric pathogens. *Nat Rev Micro,* **9,** 265-278.

Meddings, J.B. & Swain, M.G. (2000). Environmental stress–induced gastrointestinal permeability is mediated by endogenous glucocorticoids in the rat. *Gastroenterology,* **119,** 1019-1028.

Morales, V., Corzo, N. & Sanz, M.L. (2008). HPAEC-PAD oligosaccharide analysis to detect adulterations of honey with sugar syrups. *Food Chem.,* **107,** 922-928.

Nadhazi, Z., Takats, A., Offenmuller, K. & Bertok, L. (2002). Plasma endotoxin level of healthy donors. *Acta Microbiol. Immunol. Hung.,* **49,** 151-7.

Niklasson, L., Sundh, H., Fridell, F., Taranger, G.L. & Sundell, K. (2011). Disturbance of the intestinal mucosal immune system of farmed Atlantic salmon (*Salmo salar*), in response to long-term hypoxic conditions. *Fish Shellfish Immunol.,* **31,** 1072-1080.

Nordrum, S., Bakke-Mckellep, A.M., Krogdahl, A. & Buddington, R.K. (2000a). Effects of soybean meal and salinity on intestinal transport of nutrients in Atlantic salmon (*Salmo salar* L.) and rainbow trout (*Oncorhynchus mykiss*). *Comp. Biochem. Physiol. B Biochem. Mol. Biol.,* **125,** 317-335.

Nordrum, S., Krogdahl, Å., Røsjø, C., Olli, J.J. & Holm, H. (2000b). Effects of methionine, cysteine and medium chain triglycerides on nutrient digestibility, absorption of amino acids

along the intestinal tract and nutrient retention in Atlantic salmon (*Salmo salar* L.) under pair-feeding regime. *Aquaculture,* **186,** 341-360.

Novotny, L., Halouzka, R., Matlova, L., Vavra, O., Bartosova, L., Slany, M. & Pavlik, I. (2010). Morphology and distribution of granulomatous inflammation in freshwater ornamental fish infected with mycobacteria. *J. Fish Dis.,* **33,** 947-955.

Olli, J.J. & Krogdahl, Å. (1995). Alcohol soluble components of soybeans seem to reduce fat digestibility in fish-meal-based diets for Atlantic salmon, Salmo salar L. *Aquac. Res.,* **26,** 831-835.

Opstvedt, J., Nygârd, E., Samuelsen, T.A., Venturini, G., Luzzana, U. & Mundheim, H. (2003). Effect on protein digestibility of different processing conditions in the production of fish meal and fish feed. *J. Sci. Food Agric.,* **83,** 775-782.

Pavlik, I., Falkinham, J.O. & Kazda, J. (2009). Potentially Pathogenic Mycobacteria. In*: The Ecology of Mycobacteria: Impact on Animal's and Human's Health.* ed., *pp.*21-79. Springer Netherlands, Dordrecht.

Pearce, S.C., Mani, V., Boddicker, R.L., Johnson, J.S., Weber, T.E., Ross, J.W., Baumgard, L.H. & Gabler, N.K. (2012). Heat stress reduces barrier function and alters intestinal metabolism in growing pigs. *J. Anim. Sci.,* **90,** 257-259.

Penn, M.H., Bendiksen, E.Å., Campbell, P. & Krogdahl, Å. (2011). High level of dietary pea protein concentrate induces enteropathy in Atlantic salmon (Salmo salar L.). *Aquaculture,* **310,** 267-273.

Pico, J., Martinez, M.M., Martin, M.T. & Gomez, M. (2015). Quantification of sugars in wheat flours with an HPAEC-PAD method. *Food Chem.,* **173,** 674-681.

Reeves, A.E., Koenigsknecht, M.J., Bergin, I.L. & Young, V.B. (2012). Suppression of Clostridium difficile in the Gastrointestinal Tracts of Germfree Mice Inoculated with a Murine Isolate from the Family Lachnospiraceae. *Infect. Immun.,* **80,** 3786-3794.

Refstie, S., Korsøen, Ø.J., Storebakken, T., Baeverfjord, G., Lein, I. & Roem, A.J. (2000). Differing nutritional responses to dietary soybean meal in rainbow trout (Oncorhynchus mykiss) and Atlantic salmon (Salmo salar). *Aquaculture,* **190,** 49-63.

Refstie, S., Landsverk, T., Bakke-Mckellep, A.M., Ringø, E., Sundby, A., Shearer, K.D. & Krogdahl, Å. (2006). Digestive capacity, intestinal morphology, and microflora of 1-year and 2-year old Atlantic cod (*Gadus morhua*) fed standard or bioprocessed soybean meal. *Aquaculture,* **261,** 269-284.

Romarheim, O.H., Hetland, D.L., Skrede, A., Overland, M., Mydland, L.T. & Landsverk, T. (2013). Prevention of soya-induced enteritis in Atlantic salmon (*Salmo salar*) by bacteria grown on natural gas is dose dependent and related to epithelial MHC II reactivity and CD8 alpha(+) intraepithelial lymphocytes. *Br. J. Nutr.,* **109,** 1062-1070.

Romarheim, O.H., Skrede, A., Gao, Y., Krogdahl, Å., Denstadli, V., Lilleeng, E. & Storebakken, T. (2006). Comparison of white flakes and toasted soybean meal partly replacing fish meal as protein source in extruded feed for rainbow trout (*Oncorhynchus mykiss*). *Aquaculture,* **256,** 354-364.

Romarheim, O.H., Øverland, M., Mydland, L.T., Skrede, A. & Landsverk, T. (2011). Bacteria Grown on Natural Gas Prevent Soybean Meal-Induced Enteritis in Atlantic Salmon. *J. Nutr.,* **141,** 124-130.

Rombout, J.H.W.M., Abelli, L., Picchietti, S., Scapigliati, G. & Kiron, V. (2011). Teleost intestinal immunology. *Fish & Shellfish Immunology,* **31,** 616-626.

Rumsey, G., Siwicki, A., Anderson, D. & Bowser, P. (1994). Effect of soybean protein on serological response, non-specific defense mechanisms, growth, and protein utilization in rainbow trout. *Vet. Immunol. Immunopathol.,* **41,** 323-339.

Rust, M.B. (2002). Nutritional Physiology In*: Fish Nutrition (Third Edition).* ed. Halver, J. E. & Hardy, R. W., *pp.*367-452. Academic Press, San Diego, USA.

Safatle-Ribeiro, A.V., Ribeiro, U., Jr., Clarke, M.R., Sakai, P., Ishioka, S., Garrido, A.B., Jr., Gama-Rodrigues, J., Safatle, N.F. & Reynolds, J.C. (1999). Relationship between persistence of Helicobacter pylori and dysplasia, intestinal metaplasia, atrophy, inflammation, and cell proliferation following partial gastrectomy. *Dig Dis Sci,* **44,** 243-52.

Sagaert, X., Tousseyn, T., De Hertogh, G. & Geboes, K. (2012). Macrophage-related diseases of the gut: a pathologist's perspective. *Virchows Archiv,* **460,** 555-567.

Schneeberger, E.E. & Lynch, R.D. (2004). The tight junction: a multifunctional complex. *Am. J. Physiol. Cell Physiol.,* **286,** C1213-28.

Schoeffel, U., Pelz, K., Haring, R.U., Amberg, R., Schandl, R., Urbaschek, R., Von Specht, B.U. & Farthmann, E.H. (2000). Inflammatory consequences of the translocation of bacteria and endotoxin to mesenteric lymph nodes. *Am. J. Surg.,* **180,** 65-72.

Sealey, W.M., Barrows, F.T., Smith, C.E., Overturf, K. & Lapatra, S.E. (2009). Soybean meal level and probiotics in first feeding fry diets alter the ability of rainbow trout Oncorhynchus mykiss to utilize high levels of soybean meal during grow-out. *Aquaculture,* **293,** 195-203.

Sedman, P.C., Macfie, J., Sagar, P., Mitchell, C.J., May, J., Mancey-Jones, B. & Johnstone, D. (1994). The prevalence of gut translocation in humans. *Gastroenterology,* **107,** 643-9.

Shephard, K.L. (1994). Functions for fish mucus. *Rev. Fish Biol. Fish.,* **4,** 401-429.

Smit, H. (1968). Gastric secretion in the lower vertebrates and birds. In*: Handbook of Physiology, sec. 6.* ed. Code, C. F., *pp.*2791-2805. American Physiological Society, Washington DC, USA.

Spickler, A.R. & Roth, J.A. (2003). Adjuvants in Veterinary Vaccines: Modes of Action and Adverse Effects. *J. Vet. Intern. Med.,* **17,** 273-281.

Stackebrandt, E. & Goebel, B.M. (1994). Taxonomic note: a place for DNA-DNA reassociation and 16S rRNA sequence analysis in the present species definition in bacteriology. *Int. J. Syst. Bacteriol.,* **44,** 846-849.

Storebakken, T., Kvien, I.S., Shearer, K.D., Grisdale-Helland, B., Helland, S.J. & Berge, G.M. (1998). The apparent digestibility of diets containing fish meal, soybean meal or bacterial meal fed to Atlantic salmon (*Salmo salar*): evaluation of different faecal collection methods. *Aquaculture,* **169,** 195-210.

Stroband, H.W.J. & Kroon, A.G. (1981). The development of the stomach in Clarias lazera and the intestinal absorption of protein macromolecules. *Cell Tissue Res.,* **215,** 397-415.

Sun, X.Q., Fu, X.B., Zhang, R., Lu, Y., Deng, Q., Jiang, X.G. & Sheng, Z.Y. (2001). Relationship between plasma D-lactate and intestinal damage after severe injuries in rats. *World J. Gastroenterol.,* **7,** 555-8.

Sundh, H., Kvamme, B.O., Fridell, F., Olsen, R.E., Ellis, T., Taranger, G.L. & Sundell, K. (2010). Intestinal barrier function of Atlantic salmon (Salmo salar L.) post smolts is reduced by common sea cage environments and suggested as a possible physiological welfare indicator. *BMC Physiol.,* **10,** 1-13.

Thorburn, A.N., Macia, L. & Mackay, C.R. (2014). Diet, metabolites, and "western-lifestyle" inflammatory diseases. *Immunity,* **40,** 833-42.

Thornton, D.J., Rousseau, K. & Mcguckin, M.A. (2008). Structure and function of the polymeric mucins in airways mucus. *Annu Rev Physiol,* **70,** 459-86.

Tipsmark, C.K. & Madsen, S.S. (2012). Tricellulin, occludin and claudin-3 expression in salmon intestine and kidney during salinity adaptation. *Comp Biochem Physiol Part A Mol Integr Physiol,* **162,** 378-385.

Tipsmark, C.K., Sorensen, K.J., Hulgard, K. & Madsen, S.S. (2010). Claudin-15 and-25b expression in the intestinal tract of Atlantic salmon in response to seawater acclimation, smoltification and hormone treatment. *Comp Biochem Physiol Part A Mol Integr Physiol,* **155,** 361-370.

Tran-Duy, A., Van Dam, A.A. & Schrama, J.W. (2012). Feed intake, growth and metabolism of Nile tilapia (*Oreochromis niloticus*) in relation to dissolved oxygen concentration. *Aquacult. Res.,* **43,** 730-744.

Tsukita, S. & Furuse, M. (1999). Occludin and claudins in tight-junction strands: leading or supporting players? *Trends Cell Biol.,* **9,** 268-273.

Urán, P.A., Gonçalves, A.A., Taverne-Thiele, J.J., Schrama, J.W., Verreth, J.a.J. & Rombout, J.H.W.M. (2008). Soybean meal induces intestinal inflammation in common carp (*Cyprinus carpio* L.). *Fish Shellfish Immunol.,* **25,** 751-760.

Uran, P.A., Schrama, J.W., Jaafari, S., Baardsen, G., Rombout, J.H.W.M., Koppe, W. & Verreth, J.a.J. (2009). Variation in commercial sources of soybean meal influences the severity of enteritis in Atlantic salmon (Salmo salar L.). *Aquacult. Nutr.,* **15,** 492-499.

Uran, P.A., Schrama, J.W., Rombout, J., Obach, A., Jensen, L., Koppe, W. & Verreth, J.a.J. (2008). Soybean meal-induced enteritis in Atlantic salmon (Salmo salar L.) at different temperatures. *Aquacult. Nutr.,* **14,** 324-330.

Van Den Ingh, T.S.G.a.M., Krogdahl, Å., Olli, J.J., Hendriks, H.G.C.J.M. & Koninkx, J.G.J.F. (1991). Effects of soybean-containing diets on the proximal and distal intestine in Atlantic salmon (*Salmo salar*): a morphological study. *Aquaculture,* **94,** 297-305.

Van Itallie, C.M. & Anderson, J.M. (2004). The molecular physiology of tight junction pores. *Physiology (Bethesda),* **19,** 331-8.

Van Wijck, K., Verlinden, T.J.M., Van Eijk, H.M.H., Dekker, J., Buurman, W.A., Dejong, C.H.C. & Lenaerts, K. (2013). Novel multi-sugar assay for site-specific gastrointestinal permeability analysis: A randomized controlled crossover trial. *Clin. Nutr.,* **32,** 245-251.

Vandenberg, G.W. & De La Noüe, J. (2001). Apparent digestibility comparison in rainbow trout (Oncorhynchus mykiss) assessed using three methods of faeces collection and three digestibility markers. *Aquacult. Nutr.,* **7,** 237-245.

Veillette, P.A., White, R.J., Specker, J.L. & Young, G. (2005). Osmoregulatory physiology of pyloric ceca: regulated and adaptive changes in chinook salmon. *J. Exp. Zool. A Comp. Exp. Biol.,* **303,** 608-13.

Velin, Å.K., Ericson, A.-C., Braaf, Y., Wallon, C. & Söderholm, J.D. (2004). Increased antigen and bacterial uptake in follicle associated epithelium induced by chronic psychological stress in rats. *Gut,* **53,** 494-500.

Venold, F.F., Penn, M.H., Krogdahl, Å. & Overturf, K. (2012). Severity of soybean meal induced distal intestinal inflammation, enterocyte proliferation rate, and fatty acid binding protein (Fabp2) level differ between strains of rainbow trout (Oncorhynchus mykiss). *Aquaculture,* **364–365,** 281-292.

Watanabe, Y. (1984). An Ultrastructural Study of Intracellular Digestion of Horseradish Peroxidase by the Rectal Epithelium Cells in Larvae of a Freshwater Cottid Fish *Cottus nozawae*. *Nippon Suisan Gakkaishi,* **50,** 409-416.

Wiest, R. & Rath, H.C. (2003). Bacterial translocation in the gut. *Best Practice & Research Clinical Gastroenterology,* **17,** 397-425.

Williams, G.T. & Williams, W.J. (1983). Granulomatous inflammation--a review. *J. Clin. Pathol.,* **36,** 723-733.

Woese, C.R. (1987). Bacterial evolution. *Microbiol. Rev.,* **51,** 221-271.

Xavier, R.J. & Podolsky, D.K. (2007). Unravelling the pathogenesis of inflammatory bowel disease. *Nature,* **448,** 427-434.

Yamamoto, T., Suzuki, N., Furuita, H., Sugita, T., Tanaka, N. & Goto, T. (2007). Supplemental effect of bile salts to soybean meal-based diet on growth and feed utilization of rainbow trout Oncorhynchus mykiss. *Fish. Sci.,* **73,** 123-131.

Younis, E., Abdel-Warith, A.-W., Al-Asgah, N. & Ebaid, H. (2015). Histopathological alterations in the liver and intestine of Nile tilapia Oreochromis niloticus exposed to long-term sublethal concentrations of cadmium chloride. *Chin. J. Oceanol. Limnol.,* **33,** 846-852.

Zhao, Y., Qin, G., Sun, Z., Che, D., Bao, N. & Zhang, X. (2011). Effects of soybean agglutinin on intestinal barrier permeability and tight junction protein expression in weaned piglets. *Int. J. Mol. Sci.,* **12,** 8502-8512.

Øverland, M., Sørensen, M., Storebakken, T., Penn, M., Krogdahl, Å. & Skrede, A. (2009). Pea protein concentrate substituting fish meal or soybean meal in diets for Atlantic salmon (*Salmo salar*)-Effect on growth performance, nutrient digestibility, carcass composition, gut health, and physical feed quality. *Aquaculture,* **288,** 305-311.

Papers

I

JNS
JOURNAL OF NUTRITIONAL SCIENCE

RESEARCH ARTICLE

Bacterial translocation and *in vivo* assessment of intestinal barrier permeability in rainbow trout (*Oncorhynchus mykiss*) with and without soyabean meal-induced inflammation

Peyman Mosberian-Tanha[1], Margareth Øverland[1], Thor Landsverk[2], Felipe E. Reveco[1], Johan W. Schrama[3], Andries J. Roem[3], Jane W. Agger[4] and Liv T. Mydland[1]*

[1]*Department of Animal and Aquacultural Sciences, Norwegian University of Life Sciences, PO Box 5003, NO-1432 Ås, Norway*
[2]*Department of Basic Sciences and Aquatic Medicine, Norwegian University of Life Sciences, N-0033 Oslo, Norway*
[3]*Aquaculture and Fisheries Group, Wageningen Institute of Animal Sciences, PO Box 338, 6700 AH Wageningen, The Netherlands*
[4]*Department of Chemistry, Biotechnology and Food Science, Norwegian University of Life Sciences, PO Box 5003, NO-1432 Ås, Norway*

(Received 15 January 2016 – Final revision received 11 February 2016 – Accepted 15 February 2016)

Journal of Nutritional Science (2016), vol. 5, e26, page 1 of 10 doi:10.1017/jns.2016.7

Abstract

The primary aim of this experiment was to evaluate the intestinal barrier permeability *in vivo* in rainbow trout (*Oncorhynchus mykiss*) fed increasing levels of soyabean meal (SBM). The relationship between SBM-induced enteritis (SBMIE) and the permeability markers was also investigated. Our results showed that the mean score of morphological parameters was significantly higher as a result of 37·5 % SBM inclusion in the diet, while the scores of fish fed 25 % SBM or lower were not different from those of the fish meal-fed controls ($P < 0·05$). SBMIE was found in the distal intestine (DI) in 18 % of the fish (eleven of sixty): ten in the 37·5 % SBM-fed group and one in the 25 % SBM-fed group. Sugar markers in plasma showed large variation among individuals probably due to variation in feed intake. We found, however, a significant linear increase in the level of plasma D-lactate with increasing SBM inclusion level ($P < 0·0001$). Plasma concentration of endotoxin was not significantly different in groups with or without SBMIE. Some individual fish showed high values of endotoxin in blood, but the same individuals did not show any bacterial translocation. Plasma bacterial DNA was detected in 28 % of the fish with SBMIE, and 8 % of non-SBMIE fish ($P = 0·07$). Plasma concentration of D-lactate was significantly higher in fish with SBMIE ($P < 0·0001$). To conclude, SBMIE in the DI of rainbow trout was associated with an increase in bacterial translocation and plasma D-lactate concentration, suggesting that these permeability markers can be used to evaluate intestinal permeability *in vivo*.

Key words: **Rainbow trout: Soyabean meal: Enteritis: Intestinal permeability: Permeability markers**

Inclusion of sustainable ingredients as substitutes of traditional fish meal (FM) in fish diet is crucial to ensure further growth in the aquaculture sector[1]. Plant protein ingredients can serve as potential alternatives to replace FM[2]. As a result, substitution of FM by these ingredients has been reported and discussed in several publications[3–5]. Plant proteins contain anti-nutritional factors which can cause nutritional and health issues in salmonid fish such as inflammatory response in the distal intestine (DI) and lowered macronutrient digestibility[6–8]. The most widely used plant protein in animal production is soyabean meal (SBM)[2] which has also been studied in carnivorous fish. SBM, however, has shown to cause inflammation in the DI of salmonid fish, often referred to as SBM-induced enteritis (SBMIE)[7], the cause of which is not yet fully known. SBMIE has been used as a model to study plant ingredient-induced enteropathy in salmonids[8,9].

Abbreviations: DGGE, denaturing gradient gel electrophoresis; DI, distal intestine; FCR, feed conversion ratio; FM, fish meal; L:R, lactulose:L-rhamnose; S:R, sucralose:L-rhamnose; SBM, soyabean meal; SBMIE, soyabean meal-induced enteritis.

* **Corresponding author**: L. T. Mydland, email liv.mydland@nmbu.no

The gastrointestinal tract acts as a barrier between the external and internal environments. The integrity of the gut barrier is crucial to maintain homeostasis, that is, to prevent pathogens or toxins from entering the bloodstream while maintaining nutrient absorption function[10,11]. The barrier function of the gut is supported by epithelial cells, mucus and tight junction proteins[12–14]. Increased gut permeability due to the loss of barrier function potentiates systemic absorption of pathogens and toxic molecules which has been shown to be associated with intestinal inflammation in mammals and fish[15,16].

Epithelial permeability function has been assessed in mammals by *in vitro* methods such as transepithelial electrical resistance and *in vivo* tests such as transepithelial passage of sugar markers, endotoxins and D-lactate[13,14]. The *in vivo* methods are based on the assumption that microbes, large molecules and bacterial products cannot pass through the epithelial barrier and be absorbed in blood when the intestinal integrity is maintained[14]. Urinary or plasma levels of orally administered sugars such as sucrose, mannitol, rhamnose, lactulose and sucralose have been used as markers in mammalian intestinal permeability evaluations[17,18]. In these studies the ratio of disaccharides to monosaccharides in samples are calculated and used to assess barrier function[18]. Degradability of sugar molecules in different regions of the gastrointestinal tract has led to region-specific permeability experiments[13]. For example, the lactulose:L-rhamnose ratio (L:R) has been used for small-intestinal permeability evaluation because lactulose is fermentable in the colon[19]. In humans, inflammatory bowel disease and coeliac disease are two examples of intestinal inflammation which have been shown to be associated with increased urinary levels of sugar markers[20,21].

Blood or plasma measurement of bacteria and their products is another *in vivo* method used for the evaluation of bacterial translocation and intestinal permeability. Measurement of plasma endotoxin, D-lactate and detection of bacterial DNA using PCR-based methods have been used to assess the function of the intestinal barrier. Lipopolysaccharides are endotoxins which partially form the outer membrane of Gram-negative bacteria and are known to be toxic to humans and animals[22,23]. For quantitative measurement of endotoxin levels in plasma samples, the limulus amebocyte lysate assays (LAL), such as chromogenic LAL, have been widely used as a sensitive method[24]. Intestinal inflammation has shown to be associated with increased endotoxin levels in the circulation which could be a result of epithelial barrier hyperpermeability[25,26]. Many bacteria in the gastrointestinal tract produce D-lactate which has been used as a permeability marker in humans and animals due to the fact that it cannot be metabolised by mammals[27–29]. In healthy individuals, a low concentration of D-lactate is found in plasma, but the level is known to increase as a result of increased intestinal permeability[14,30]. PCR is a sensitive method which has been used for the detection of bacterial DNA in blood to assess intestinal barrier function in a number of experiments[31–33]. PCR has proven to be more sensitive than conventional culture methods in detecting bacteria and it is also able to detect dead bacteria in samples[31,34].

The effect of plant ingredients on intestinal barrier permeability and function is not yet fully understood in fish. Experiments on intestinal barrier permeability in fish has been mainly based on *in vitro* and molecular studies such as studies of gene expression[35–38]. SBM or SBM-extracted alcohol-soluble substances are examples of dietary factors which have been shown to increase intestinal permeability in fish *in vitro*[15,39] and alter morphology of brush borders leading to tight junction exposure to the luminal components[40]. To our knowledge, there is no information available on *in vivo* assessment of intestinal permeability in salmonids fed SBM. Thus, this experiment was designed to evaluate intestinal barrier permeability *in vivo* in rainbow trout fed with increasing levels of SBM by using plasma endotoxin, D-lactate, sugar molecules and detection of bacterial DNA as markers. Furthermore, the change in intestinal permeability was investigated in relation to SBMIE.

Materials and methods

Fish husbandry and experimental diets

The experiment was performed at the fish laboratory located at the Norwegian University of Life Sciences (Ås, Norway), which is an approved research facility by the Norwegian Animal Research Authority and operates in accordance with the Norwegian Regulations of 17 June 2008 no. 822: Regulations relating to Operation of Aquaculture Establishments (Aquaculture Operation Regulations). A total of 300 rainbow trout (*Oncorhynchus mykiss*) with mean initial body weight of 236 g were randomly allocated into twelve tanks. Each tank (300 litres) was supplied with recirculated fresh water at a flow rate of 7·5 litres/min under continuous light. Water temperature ranged from 8 to 11°C. Daily measurement of dissolved O_2 levels was performed and kept above 8·0 mg/l in the outlet water. Four iso-energetic experimental diets were formulated and consisted of a FM-based control and three experimental diets containing SBM at levels of 12·5, 25 and 37·5 % (Table 1). The total experimental period lasted for 31 d, and a mixture of sugar markers, consisting of 10 g lactulose, 10 g sucralose and 5 g L-rhamnose (Sigma-Aldrich), was added per kg of each diet and fed during the last 3 d. Fish were fed 30 % in excess and uneaten feed was collected from the tank outlets after each feeding period. Feed preparation and daily feed intake calculations were performed as described in Øverland *et al.*[41]. The fish were fed until the time of sampling to avoid an empty intestine in fish used for analysis.

Fish sampling

On day 28, before the addition of sugar markers to the diets, nine fish per treatment (three fish/tank) were randomly selected and anaesthetised with Aquacalm (12 mg/l) for blood sampling. Blood samples were collected from the caudal vein in heparinised sterile syringes, transferred to Eppendorf tubes, and centrifuged (3000 ***g*** for 5 min) to obtain plasma. The plasma was then stored at −80°C for sugar marker analysis to determine any possible concentration of these molecules which was not due to the consumption of sugar marker-containing diets. After blood sampling fish were killed

Table 1. Formulation and chemical composition (as-is) of fish meal (FM) and experimental diets

	FM	SBM 12·5 %	SBM 25 %	SBM 37·5 %
Ingredients (g/kg, as-fed)				
Fish meal*	620·0	500·0	370·0	229·0
Soyabean meal†	–	125·0	250·0	375·0
Fish oil‡	183·9	178·9	183·9	199·9
Gelatinised potato starch§	110·0	110·0	110·0	110·0
Gelatin‖	80·0	80·0	80·0	80·0
Premix¶	6·0	6·0	6·0	6·0
Y_2O_3**	0·1	0·1	0·1	0·1
Analysed content				
DM	950	935	927	944
Crude protein (g/kg DM)	512	489	462	432
Crude lipid (g/kg DM)	240	229	256	227
Starch (g/kg DM)	112	115	108	116
Ash (g/kg DM)	109	95	83	69
Gross energy (MJ/kg DM)	23·1	23·0	23·2	23·2

SBM, soyabean meal.
* NorseaMink.
† Denofa.
‡ Skretting Norway.
§ Lygel F 60, Lyckeby Culinar AB.
‖ Rousselot™ 250 PS, Rousselot SAS.
¶ Provided the following (per kg diet): Ca 1·2 g, Mn_2SO_4 14·7 mg, $ZnSO_4$ 117 mg, $CuSO_4$ 4·90 mg, $CoSO_4$ 980 µg, $Ca(IO_3)_2$ 3·6 mg, retinol 2450 IU, cholecalciferol 1470 IU, tocopherol 196 mg, menadione 9·80 mg, thiamine 14·7 mg, riboflavin 24·5 mg, pyridoxine 14·7 mg, cobalamine 19·6 µg, pantothenic acid 29·4 mg, folic acid 4·90 mg, niacin 73·5 mg, biotin 245 µg, vitamin C 1·75 (Rovimix® Stay-C® 35, DSM Nutritional Products), AS Norsk Mineralnæring.
** Di-yttrium trioxide (Y_2O_3) (Metal Rare Earth, Ltd).

by a sharp blow to the head. At the end of the experiment and after feeding sugar-containing diets, five fish per tank were individually weighed and anaesthetised with Finquel (60 mg/l) prior to blood sampling, as described above. The anaesthetised fish were killed by a sharp blow to the head prior to dissection. Digesta samples from the DI were collected by carefully scraping with a sterile spatula into sterile containers, and stored on dry ice until transfer to −80°C. Tissue samples were also taken from the DI of each of the five fish and cut lengthways for morphological evaluation and fixed in neutral buffered formalin (4 % formaldehyde) for 48 h and then dehydrated in 70 % ethanol before embedding in paraffin following standard routines.

Chemical analysis

Diets were analysed for DM by drying at 105°C to constant weight, ash by incineration at 550°C overnight, crude protein by the Kjeldahl method (N × 6·25), crude fat by HCl hydrolysis followed by diethyl ether extraction, starch by α-amylase and amyloglucosidase hydrolysis and gross energy by bomb calorimetry (Parr 1271 bomb calorimeter; Parr).

Histology

Dehydrated DI tissues were embedded in paraffin and stained by haematoxylin and eosin (H&E) following a standard procedure. Blinded evaluation of four morphological parameters (Table 2) was performed on each tissue. A score was given to each parameter which ranged from 0 (no morphological change) to 2 (extreme changes). Scores of 0·5 and 1 were given to very slight changes (assessed as normal morphology) and mild changes, respectively. Based on this protocol at least a score of 1 should be given to the lamina propria, epithelial changes and atrophy to confirm occurrence of SBMIE. The total histological score was calculated by taking the average of the scores of the parameters to express the degree of SBMIE.

Table 2. Scoring system used to evaluate the degree of morphological changes in the distal intestine of soyabean meal-fed rainbow trout (*Oncorhynchus mykiss*)

Parameters	Score range	Description
Lamina propria	0–2	Leucocyte (e.g. lymphocyte, granulocytes and eosinophilic granular cells) infiltration and accumulation in the lamina propria
Epithelial changes	0–2	Reduced supranuclear vacuolisation Reduced height of epithelial cells Increased cytoplasmic basophilia
Atrophy	0–2	Shortening of the intestinal folds
Oedema	0–2	Accumulation of fluid in the lamina propria

DNA extraction

Genomic DNA was extracted from plasma with the QIAamp DNA Blood Mini Kit (Qiagen) according to the manufacturer's protocol. Extracted DNA was then quantified and the purity was measured with a NanoDrop™ 8000 spectrophotometer (Thermo Scientific) before it was stored at −20°C for further analysis.

Nested PCR protocol

Amplification of 16S rRNA genes from bacteria was performed using universal bacterial primers in a nested PCR. Primary amplification reactions were performed using primers 357F (5′-CCT AGG GGA GGC AGC AG-3′) and 1369R 5′-GCCCGGGAACGTATTCACCG-3′) in a 25 µl reaction mixture containing 500 nM of each of the primers, 90 ng of DNA template, 1 × reaction buffer, 1·75 mM-$MgCl_2$, 300 µM of each deoxyribonucleotide triphosphate (dNTP), 1·25 U Platinum® Taq DNA polymerase (Invitrogen) and 0·1 % bovine serum albumin. Negative controls (DNA-free water) were included in all sets of PCR reactions to provide a contamination check. Reaction mixtures were subjected to the following cycling conditions: 94°C for 4 min then 59°C for 60 s and 72°C for 90 s followed by seven cycles of touch down PCR (30 s at 94°C, 30 s with 1°C/cycle decrement from 59°C and 1 min at 72°C). This was further followed by thirty cycles of 94°C for 30 s, 53°C for 30 s and 72°C for 90 s with a final extension step of 10 min at 72°C. The secondary (nested) PCR was conducted using primers 357F (5′-CCT AGG GGA GGC AGC AG-3′) containing a 40-bp GC clamp at the 5′ end and 519R (5′-ATT ACC GCG GCK GCT GG-3′) in a

50 µl reaction mixture for amplification of the V3 region of the bacterial 16S rRNA genes. Nested PCR reaction mixtures contained: 200 µM of each dNTP, 1·75 mM-$MgCl_2$, 500 nM of each primer, 1× PCR buffer, 1·25 U Platinum® Taq DNA polymerase (Invitrogen) and PCR products from the first round. A re-amplified negative control from the first-round PCR and a new negative control using water were also included. PCR conditions were as follows: 4 min at 94°C, 1·5 min at 64°C and 1·5 min at 72°C followed by seven cycles of touchdown PCR (30 s at 94°C, 30 s with an 1°C/cycle decrement from 64°C and 60 s at 72°C) and followed by twenty-seven cycles of 45 s at 94°C, 45 s at 58°C, 60 s at 72°C, and a final extension step of 10 min at 72°C. To confirm successful amplification, 8 µl of PCR products from each amplification step were analysed by gel electrophoresis (1·5 % agarose, stained with RedSafe™ Nucleic Acid Staining Solution from iNtRON Biotechnology, Inc.), and images were taken using the Gel Doc XR System (Bio-Rad Laboratories).

Denaturing gradient gel electrophoresis analysis

Denaturing gradient gel electrophoresis (DGGE) was performed to separate PCR products of 16S rRNA genes. Polyacrylamide gels (7·5 % (w/v) acrylamide) were made according to the manufacturer's instructions and were run on an Ingeny PhorU apparatus (Ingeny International BV) in a 0·5× TAE buffer (containing Tris base, acetic acid and EDTA). Denaturing gradients ranged from 42 to 58 % (where 100 % is defined as 7 M-urea and 40 % (v/v) formamide). Electrophoresis was performed at 75 V for 16 h at 60°C and gels were stained with SYBR Gold nucleic acid gel stain (Invitrogen) in 1× TAE for 10 min and photographed with Gel Doc XR System (Bio-Rad Laboratories).

Denaturing gradient gel electrophoresis band sequencing

Selected DGGE bands were excised from the gel with sterile pipette tips. Each piece was then transferred into 50 µl of sterile water and eluted overnight at 4°C. Eluted DNA (3 µl) was subject to re-amplification applying the secondary (nested) PCR conditions as described previously, but with the following changes: eighteen cycles of PCR using 357F primer without the GC clamp and the volume of reaction was 25 µl. Amplification products were visualised as described previously prior to purification using the MultiScreen 96-well filtration plate (Millipore). Sequencing was carried out using the BigDye® Terminator v3.1 Cycle Sequencing Kit, 357F and 519R primers on an ABI 3730 DNA analyser (Applied Biosystems). The BLAST (Basic Local Alignment Search Tool) program was used to search for the species with the closest known relationship with the 16S rRNA gene sequences.

Biochemical assays

Endotoxin concentration in plasma samples was measured using ToxinSensor™ Chromogenic LAL Endotoxin Assay Kit (GenScript) under sterile conditions. The plasma samples were diluted at 1:1 (v/v) in endotoxin-free water and heated to 80°C for 10 min to remove non-specific endotoxin inhibitors. Endotoxin levels in samples were calculated from a standard curve of known endotoxin concentrations according to the manufacturer's instructions. Heparinised plasma was deproteinised by centrifugation through 10 K spin columns before the D-lactate concentration was measured using a commercial kit (D-lactate colorimetric assay; Sigma-Aldrich). The absorbance at 450 nm was read on a Wallac Victor 3 Multi-well Plate Reader (Perkin Elmer). D-Lactate concentration in distal intestinal content was determined using the same kit. In brief, an accurately weighed 200 mg sample of digesta was mixed well with two volumes (400 µl) of the D-lactate assay buffer. The digesta suspension was centrifuged through 10 K spin columns and the D-lactate concentration was assayed in 1:5 dilutions of the intestinal filtrate.

Plasma analysis of sugar markers

Plasma was filtrated by centrifugation through a 10 K spin column and diluted 1:1 with water before analysis by high-performance anion exchange chromatography (HPAEC) using a Dionex ICS3000 connected to a CarboPac PA1 column ($2 \times 250\ mm^2$) equipped with a guard of the same type ($2 \times 50\ mm^2$) (Dionex). The HPAEC system was operated with a flow rate of 0·25 ml/min. Start eluent conditions was 10 % eluent A (0·1 M-NaOH) and 90 % eluent C (MQ-water) over 5 min, then 100 % A for 9 min, from 14 to 19 min an increase in eluent B (0·1 M-NaOH + 1 M-NaOAc) from 0 to 50 %, along with a decrease in eluent A from 100 to 50 %, and thereafter back to 10 % eluent A for 25 min. Eluted sugar markers (L-rhamnose, lactulose, sucralose) were monitored by the pulsed amperometric detector fitted with disposable gold working electrodes to increase the sensitivity, chromatograms were recorded using Chromeleon software (Dionex), and quantification was performed using known external standards at multiple concentrations.

Calculations and statistics

Specific growth rate (SGR) of fish was calculated according to the following equation:

$$\mathrm{SGR} = 100 \times \left[\ln(\text{final body weight}) - \ln(\text{initial BW})\right]/\text{days fed}.$$

Feed conversion ratio (FCR) was calculated as:

$$\mathrm{FCR} = \text{feed intake}(\mathrm{g, DM})/\text{fish weight gain (g)}.$$

Daily feed intake per fish was calculated on a DM basis as:

$$\text{Feed intake}(\mathrm{g,\ DM})\text{over the experimental period/days fed}.$$

Data were analysed by a one-way ANOVA using the general linear model (PROC GLM) and, when appropriate, by the χ^2 test in SAS 9.4 (SAS Institute, Inc.). Tukey's honestly significant difference (HSD) test was performed for *post hoc* analysis. In addition, orthogonal contrasts for linear, quadratic and

Table 3. Feed intake and growth performance of rainbow trout (*Oncorhynchus mykiss*) fed the experimental diets for 31 d
(Mean values with pooled standard errors; *n* 3)

	FM	SBM 12·5 %	SBM 25 %	SBM 37·5 %	SEM	*P*
Initial weight (g)	235·8	236·2	235·2	235·2	2·51	0·91
Final weight (g)	334·3	327·9	344·2	330·5	9·13	0·13
Specific growth rate (%)	1·1	1·1	1·2	1·1	0·11	0·14
Feed intake (g/d)	2·77[a]	2·23[a,b]	2·47[a,b]	2·16[b]	0·263	0·04
Feed conversion ratio	0·87[a]	0·75[b]	0·70[b]	0·70[b]	0·021	<0·0001

FM, fish meal; SBM, soyabean meal.
[a,b] Mean values within a row with unlike superscript letters were significantly different (*P*<0·05).

cubic effects of the diets were determined using the ESTIMATE statement in PROC GLM. The OR was calculated (PROC LOGISITIC) as the ratio of the odds of bacterial translocation (PCR-positive) when SBMIE was present to the odds of bacterial translocation when SBMIE was absent. Data from histological evaluation and plasma lactulose and DNA level were not normally distributed after log 10-transformation; and thus the analysis was performed using a non-parametric Kruskal–Wallis test by ranks followed by the Wilcoxon rank-sum test. The level of significance was set at $P < 0·05$.

Results

Growth rate and feed conversion

Feed intake, growth rate and FCR are given in Table 3. There was a significant reduction in feed intake with the inclusion of 37·5 % SBM in the diet compared with the FM diet ($P = 0·04$). Adding SBM to the diets had a significant effect on FCR ($P < 0·001$). Fish fed the FM control diet had significantly higher FCR than those fed SBM-containing diets. Fish fed the 37·5 % SBM diet had the lowest FCR, while the fish fed the 25 % SBM diet had lower FCR than those fed the 12·5 % SBM diet. There were no differences among the diets for final weight and specific growth rate (SGR).

Morphological evaluation of the distal intestine

The mean scoring of morphological parameters is shown in Fig. 1. Diets containing 12·5 and 25 % SBM showed minor morphological changes, but were not statistically different from the FM control diet. Fish fed the 37·5 % SBM diet showed significantly increased changes in all morphological parameters ($P < 0·05$). These changes were characterised by reduced supranuclear vacuoles and height of epithelial cells, reduced height of intestinal folds (atrophy) and widening of the lamina propria due to oedema and increased numbers of leucocytes (Table 2; Fig. 2). Histological evaluation revealed SBMIE in ten fish with varying degrees of morphological changes from the group fed 37·5 % SBM and in one fish displaying a moderate SBMIE from the group fed 25 % SBM.

PCR-denaturing gradient gel electrophoresis analysis

A total number of seven plasma samples were positive for bacterial 16S rDNA detection. DGGE analysis of the PCR products from these samples is presented in Fig. 3. The results from sequence analysis of excised bands from the DGGE gel are shown in Table 4. There was a total number of fourteen bands sequenced, of which four were short sequences (138–141 bp) and represented unspecific amplification (not shown), six

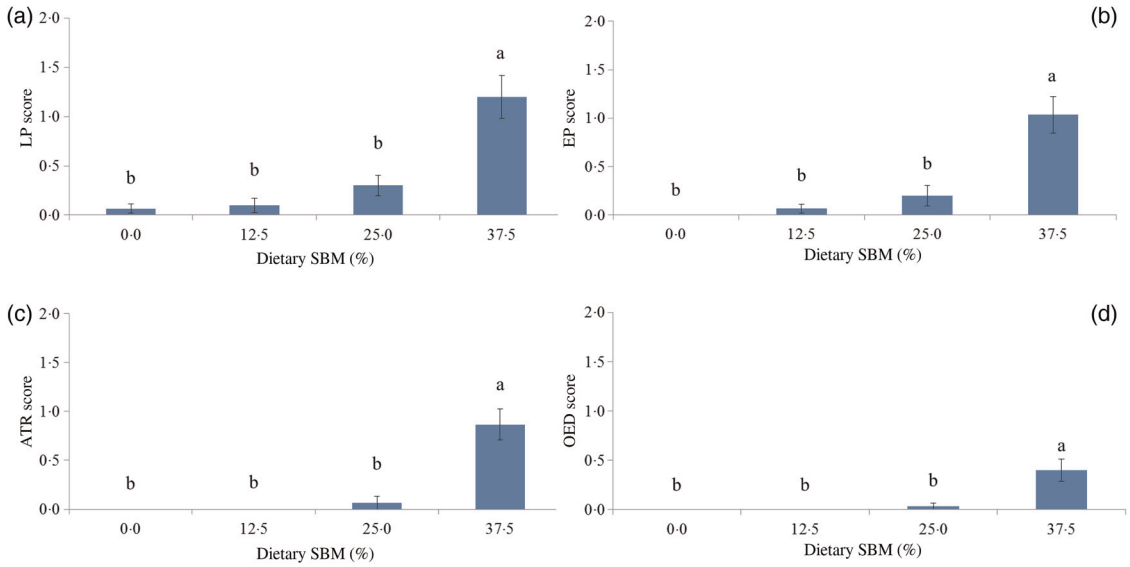

Fig. 1. Morphological evaluation of the distal intestine of rainbow trout (*Oncorhynchus mykiss*) fed a fish meal-based diet and three experimental diets containing soyabean meal (SBM) at levels of 12·5, 25 and 37·5 %. Changes in the leucocyte infiltrates in the lamina propria and submucosa (LP) (a); changes in the epithelium (EP) (b); atrophy of the intestinal folds (ATR) (c); and accumulation of protein-rich fluid in the lamina propria defined as oedema (OED) (d). Values are means (*n* 15), with standard errors represented by vertical bars. [a,b] Mean values with unlike letters were significantly different ($P < 0·05$).

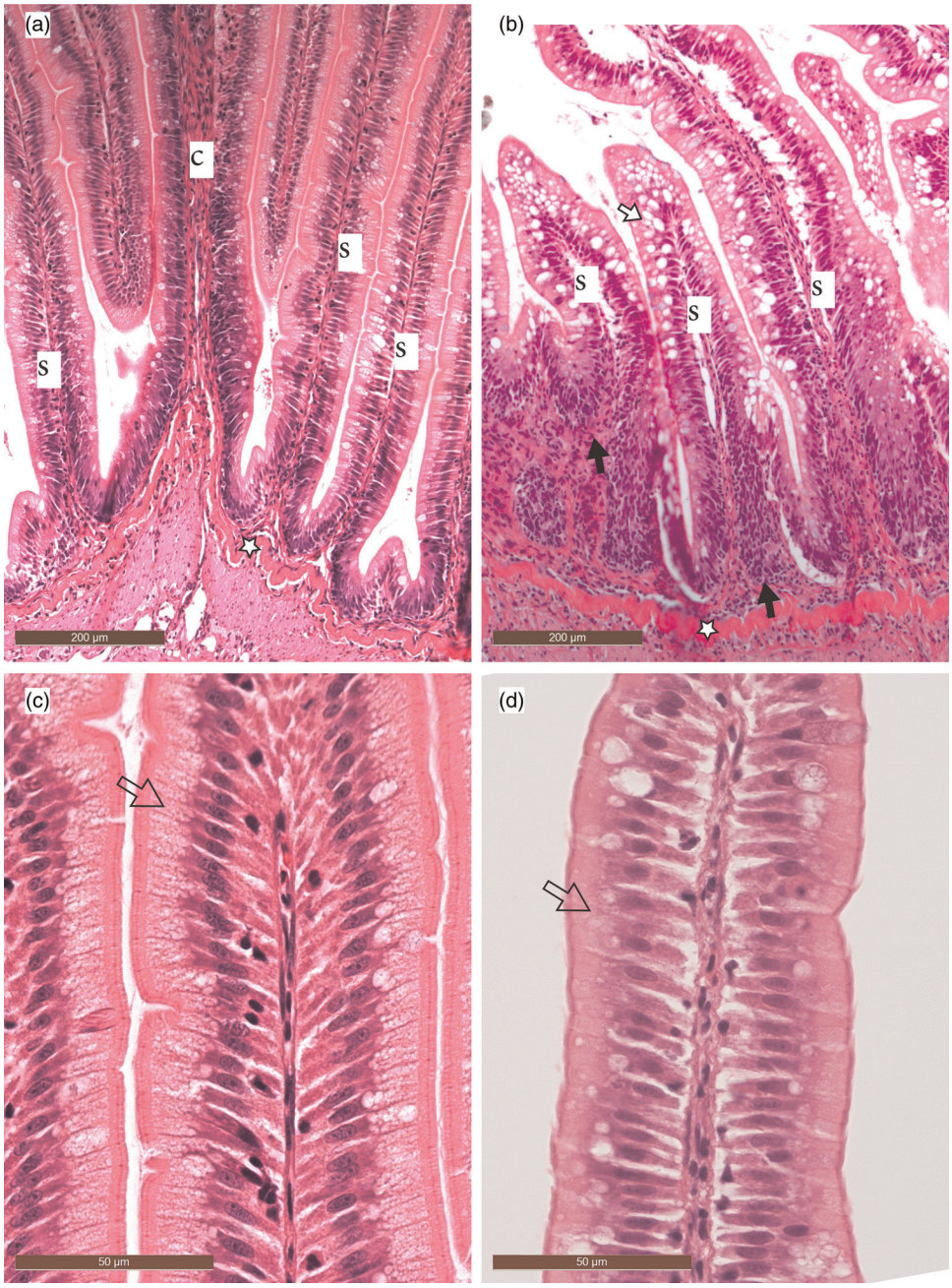

Fig. 2. Morphology of the distal intestine in rainbow trout (*Oncorhynchus mykiss*) stained with haematoxylin and eosin (H&E) at low and high magnifications, respectively. Bars indicate the actual magnification. (a) Low magnification: fish meal control (non-soyabean meal-induced enteritis; non-SBMIE) – a normal intestine without subepithelial infiltrates of inflammatory leucocytes and slender simple (s) and complex (c) folds outlined by regular, high and finely vacuolated columnar epithelial cells. (b) Low magnification: soyabean meal 37·5 % (SBMIE) – an inflamed intestine with atrophy of complex and simple folds and heavy infiltration of the subepithelial intestinal mucosa (black arrows) with inflammatory leucocytes and proliferation of fibroblasts, indicating a subacute state of inflammation. Note the many large, clear vacuoles in the epithelium (white arrow) which is probably due to the proliferation of goblet cells. The point stars on (a) and (b) indicate the stratum compactum. (c) High magnification: fish meal control (non-SBMIE) – a normal, high columnar epithelium with a finely vacuolated supranuclear cytoplasm (arrow) and a distinct brush border. (d) High magnification: soyabean meal 37·5 % (SBMIE) – the epithelial cells have a denser cytoplasm (arrow), are lower in height and lack the finely vacuolated supranuclear zone seen in the normal tissue, although some clear and quite large intracytoplasmic vacuoles can be seen, probably due to the presence of goblet cells. The brush border is less distinct compared with the control.

represented *Staphylococcus* spp., while the remaining four bands were identified by BLAST (Basic Local Alignment Search Tool) as different *Escherichia coli* strains.

Plasma levels of intestinal permeability markers

Increasing dietary SBM inclusion resulted in non-significant changes in plasma endotoxin and total genomic DNA concentration (Table 5). None of the sugar markers could be detected in plasma from fish fed control and experimental diets on day 28 before the addition of dietary sugar markers. Variation in plasma sugar marker concentration was generally large among individuals; however, the variation was found to be somewhat lower for L-rhamnose (Table 5). Plasma sucralose levels were below the detection limit in many individuals and for all fish fed the 12·5 and 25 % SBM diets. The plasma

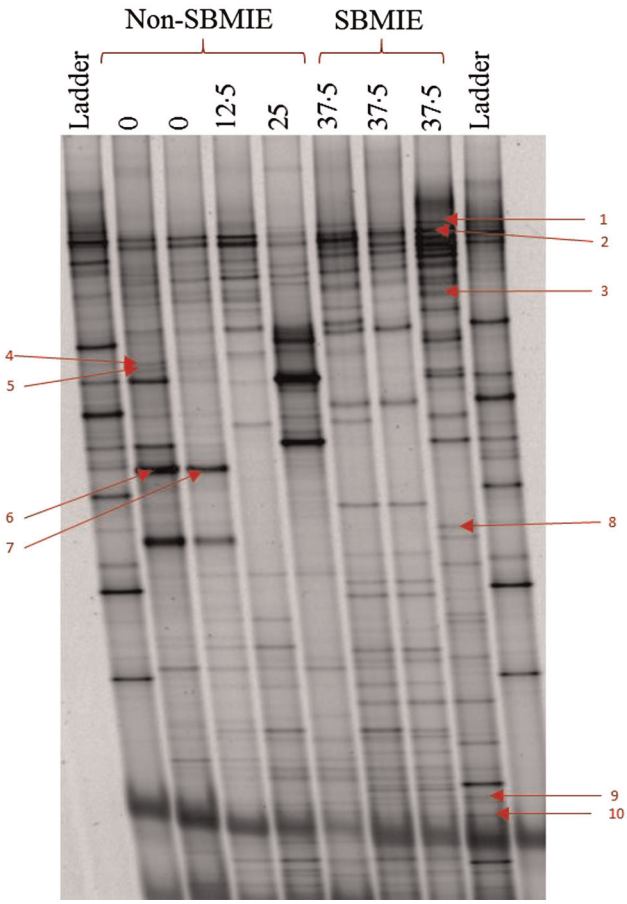

Fig. 3. Denaturing gradient gel electrophoresis (DGGE) profile of 16S rDNA amplicons from the plasma of PCR positive rainbow trout (*Oncorhynchus mykiss*) fed diets with different soyabean meal (SBM) inclusion levels: 0, 12·5, 25 and 37·5 %. Bands 1–10 are excised DGGE bands used for sequence analysis. See Table 4 for details of each band's identification. SBMIE, SBM-induced enteritis.

levels of sucralose were not significantly different between FM- and 37·5 % SBM-fed fish. Plasma L-rhamnose levels were, however, significantly reduced in the group fed 37·5 % SBM ($P = 0·01$). The variation was more prominent for lactulose and the plasma level of this sugar was not significantly different between FM-fed and 37·5 % SBM-fed fish. Plasma L:R and sucralose:L-rhamnose (S:R) ratios in 37·5 % SBM-fed fish were not different from those in the control FM fish. Mean plasma D-lactate concentration was significantly higher in 37·5 % SBM-fed fish compared with the other groups ($P < 0·0001$) (Table 5). The ESTIMATE statement revealed a linear increase in the plasma level of D-lactate with increasing level of SBM inclusion in the diet ($P < 0·0001$) while no linear, quadratic and cubic effects were observed for other permeability markers.

Relationship between soyabean meal-induced enteritis, plasma permeability markers and PCR

Differences in plasma endotoxin and genomic DNA concentration were found to be insignificant between SBMIE and non-SBMIE fish (Table 6). Three of eleven fish with SBMIE were shown to be PCR-positive (28 %) while this rate tended to be lower in non-SBMIE group, with only four of forty-nine (8 %) being PCR-positive ($P = 0·07$). Three of seven PCR-positive fish (43 %) had also SBMIE while this ratio was only eight of fifty-three (15 %) in PCR-negative fish ($P = 0·074$) (Table 6). The OR of positive PCR in fish with SBMIE was 4·5 (95 % CI 1·92–10·34) relative to the non-SBMIE fish ($P = 0·0005$). The plasma L:R ratio was found to be higher in fish with SBMIE than that in non-SBMIE fish, but variation was high in this category (Table 6). Plasma L-rhamnose was, however, reduced in the SBMIE group ($P = 0·03$). Fish with SBMIE demonstrated a higher plasma D-lactate level than non-SBMIE fish ($P < 0·05$). A positive but weak correlation was also found between the plasma level of D-lactate and degree of SBMIE (n 60, $F = 24·6$, r^2 0·30, $P < 0·001$).

Discussion

The growth of fish fed increasing levels of SBM was comparable with that of the fish fed FM, as the SGR did not change in response to SBM inclusion. FCR gradually decreased as a result of increased SBM inclusion, which is not consistent with previous studies[42,43]. Lower FCR in this experiment may be due to the lower feed consumption by SBM-fed fish or a reduced passage rate of the feed and thus increasing the time for nutrient uptake in these fish. While increased inflammatory response was evident in the group fed 37·5 % SBM, no adverse effect was observed on fish growth, which is in accordance with previous studies[44]. Moreover, the histological evaluation revealed a moderate degree of inflammation in fish fed

Table 4. Identification of denaturing gradient gel electrophoresis bands obtained from plasma based on 16S rDNA sequencing of the V3 region

Band no.	Sequence length (bp)	Identification by BLAST	Homology (%)	GenBank accession no.
1	161	*Staphylococcus* sp. *ECBMB15*	100	KJ425241.1
2	161	*Staphylococcus* sp. *ECBMB11*	100	KJ425241.1
3	161	*Staphylococcus cohnii strain BDA10*	94	HQ641334.1
4	161	*Escherichia coli strain E417-1*	99	KJ477010.1
5	163	*Escherichia coli strain G3T64*	94	GU646103.1
6	161	*Escherichia coli strain E417-1*	99	KJ477010.1
7	161	*Escherichia coli strain E417-1*	99	KJ477010.1
8	162	*Staphylococcus* sp. *ECBMB15*	97	KJ425241.1
9	162	*Staphylococcus* sp. *ECBMB15*	99	KJ425241.1
10	161	*Staphylococcus* sp. *ECBMB15*	100	KJ425241.1

BLAST, Basic Local Alignment Search Tool.

Table 5. Effect of diets on the level of intestinal permeability markers in plasma
(Mean values with pooled standard errors; fifteen fish per diet)

	FM	SBM 12·5 %	SBM 25 %	SBM 37·5 %	SEM	*P*
Permeability markers						
Endotoxin (EU/ml)	0·09	0·08	0·09	0·08	0·019	0·621
DNA concentration (μg/ml)*	1·30	1·09	1·14	1·06	0·296	0·263
D-Lactate (μg/ml)	6·19[b]	7·01[b]	6·80[b]	8·69[a]	1·288	<0·0001
Sugar markers (μg/ml)						
Lactulose†	9·20[a,b]	2·00[b]	2·89[b]	10·26[a]	3·949	0·012
Sucralose	0·71	ND	ND	1·19	0·951	0·421
L-Rhamnose	15·65[a,b]	17·09[a]	14·86[a,b]	10·25[b]	3·648	0·013
L:R†	0·54[a,b]	0·16[b]	0·22[b]	1·70[a]	1·013	0·010
S:R	0·04	ND	ND	0·08	0·041	0·189

FM, fish meal; SBM; soyabean meal; EU, endotoxin units; ND, not detected; L:R, lactulose:L-rhamnose ratio; S:R, sucralose:L-rhamnose ratio.
[a,b] Mean values within a row with unlike superscript letters were significantly different ($P < 0·05$).
* Genomic DNA measured after extraction.
† The Kruskal–Wallis test was performed for this parameter.

37·5 % SBM, which may further indicate that rainbow trout seems to be less sensitive to SBM than Atlantic salmon[45]. A higher number of fish with SBMIE as a result of increased SBM inclusion is also consistent with previous reports[6].

The relationship between gut barrier disturbance and the development of SBMIE is not yet known in fish. In this experiment, we hypothesised that SBMIE is associated with increased intestinal permeability which further promotes translocation of micro-organisms and/or their products into the bloodstream. In humans and mammals, bacterial translocation from the lumen into the circulation has been reported in subjects with intestinal inflammation[46,47]. Translocation of bacteria into the blood indicates a loss or impaired gut barrier function which may occur under different conditions. Under homeostatic conditions, some bacterial translocation may occur but is cleared by the organism's immune system[48]. The rate of normal bacterial translocation has been reported to be in the range of 5–10 % in humans[49] and 10–20 % in animals[50]. When gut homeostasis is disturbed, however, a rise in the rate of bacterial translocation may occur[49]. In fish, the normal rate of bacterial translocation and its association with SBMIE is not known; however, there is evidence that gut bacteria translocate into enterocytes in larvae, fry and adult fish[51]. In this study, we used PCR-DGGE to detect and identify circulating bacterial DNA in fish. Our results indicate that the detection of bacterial DNA in plasma is more frequently associated with the incidence of SBMIE (OR 4·5) which may suggest a link between SBMIE and bacterial translocation. Disruption of the gut barrier has shown to be associated with bacterial translocation in a number of human studies[27,33,34]. The PCR-DGGE analyses in the present experiment identified several strains of two species of bacteria, *Staphylococcus* spp. and *E. coli*, and the latter has been known as a common translocating bacteria in humans[52]. Some strains of both *E. coli* and *Staphylococcus* spp. are known to cause infection, but PCR only detects bacterial DNA and does not differentiate between dead or living bacteria.

Table 6. PCR results and plasma levels of intestinal permeability markers in soyabean meal (SBM)-induced enteritis (SBMIE) and non-SBMIE groups of rainbow trout (*Oncorhynchus mykiss*)
(Mean values with pooled standard errors)

Group	SBMIE*	Non-SBMIE	SEM	*P*
n	11	49		
PCR-positive samples	3	4		
Genomic DNA (μg/ml)	0·92	1·04	0·150	0·52
Endotoxin (EU/ml)	0·08	0·07	0·011	0·71
Sugar markers (μg/ml)				
L:R†	1·06[a]	0·47[b]	0·325	0·02
S:R	0·08	0·04	0·031	0·23
L-Rhamnose	11·01[b]	15·24[a]	1·969	0·03
D-Lactate	8·91[a]	6·77[b]	0·490	<0·0001

EU, endotoxin units; L:R, lactulose:L-rhamnose ratio; S:R, sucralose:L-rhamnose ratio.
[a,b] Mean values within a row with unlike superscript letters were significantly different ($P < 0·05$).
* Includes ten fish from the 37·5 % SBM-fed group and one fish from the 25 % SBM-fed group.
† The Kruskal–Wallis test was performed for this parameter.

In this experiment, an increasing level of SBM inclusion and the occurrence of SBMIE did not increase plasma levels of endotoxins compared with FM-fed and non-SBMIE fish. The reason could be that endotoxins are cleared rapidly by the mucosal immune system, while trying to cross the epithelium under SBMIE.

Increased intestinal permeability, reflected by elevated urinary levels of sugar markers, has been reported in humans with impaired intestinal barrier integrity[17,18]. A high urinary or plasma L:R ratio is often used as an indication of small-intestinal hyperpermeability in mammals. Our results, however, do not show increased plasma L:R and S:R ratios as a result of increased SBM inclusion and revealed large variation among individuals in all dietary groups (Table 5). The L:R ratio was significantly increased in the SBMIE group, while the increase in the S:R ratio was not significant, presumably because of the small number of observations for sucralose (*n* 6). The elevated L:R ratio in the SBMIE group is in accordance with previous findings in humans[18] and may indicate that intestinal inflammation is associated with DI hyperpermeability; however, the variation was also found to be large for this parameter. Sugar markers were added to the diets; consequently, any variation in feed intake could reflect differences in the absorption of these molecules. Contrary to humans and model animals, the group feeding system is practised to feed the fish without monitoring the

individual consumption of diets. Thus it is likely that individual fish used for plasma sugar analysis had consumed unequal amounts of these molecules before sampling. Based on these results, it seems that feed-added markers may not be suitable for the evaluation of intestinal permeability in fish that are group-fed. In this experiment, however, the SBMIE group had significantly lower plasma L-rhamnose levels which may be due to the epithelial changes as a result of SBMIE, with consequent adverse effect on L-rhamnose absorption. Most of the fish (ten of fifteen) from the group fed 37·5 % SBM had SBMIE which consequently resulted in a reduced mean of plasma L-rhamnose level in this group. A reduction in excretion levels of L-rhamnose as a result of increased gut permeability has been reported previously in human subjects[53]. The possible explanation is that the intestinal absorptive area may be reduced in response to inflammation which in turn can decrease the uptake of L-rhamnose into the bloodstream[54].

Increased plasma levels of D-lactate have been shown in humans and model animals with intestinal barrier injury[55–57]. In fish with SBMIE, plasma D-lactate concentrations increased compared with the non-SBMIE fish, which suggests that increased intestinal permeability may have occurred as a result of inflammation. Furthermore, an increased degree of SBMIE showed a weak but significant correlation with plasma levels of D-lactate. This may suggest that other factors than SBMIE can also contribute to the increased plasma level of D-lactate. It has been shown, for example, that the increase in bacterial fermentation in the lumen as a result of bacterial overgrowth or carbohydrate malabsorption may also increase the level of D-lactate in the circulation independent of inflammation[58,59]. We also found a significant linear increase in plasma D-lactate as a result of increased SBM inclusion level, which raised the question whether there is a dietary effect on plasma D-lactate level independent of inflammation. However, we did not observe an increased D-lactate concentration in DI content from fish fed 37·5 % SBM compared with the control group (data not shown), which may suggest that there is a relationship between SBMIE and increased gut permeability.

In conclusion, our results show that SBMIE resulted in increased plasma levels of D-lactate and an increased incidence of bacterial translocation. The plasma lactulose:L-rhamnose ratio was found to increase in fish with SBMIE; however, the analysis revealed a large variation among individuals, probably due to unequal feed consumption. This indicates that feed added markers are less reliable under the group-feeding strategy. Based on our results, D-lactate and PCR-based detection of bacteria are more suitable estimates for *in vivo* permeability assessment under SBMIE conditions in rainbow trout.

Acknowledgements

This study was supported by the Norwegian University of Life Sciences and Foods of Norway, a Centre for Research-based Innovation (the Research Council of Norway; grant no. 237841/030).

P. M.-T., M. Ø., J. W. S., A. J. R. and L. T. M. designed the experiment. P. M.-T. was involved in feed production, conducting the experiment, performing endotoxin and nested PCR analysis, statistical analysis and the writing of the manuscript. T. L. performed the histological evaluation. F. E. R. was involved in DGGE analysis and sequencing. J. W. A. performed high-performance anion exchange chromatography (HPAEC)-based sugar analysis and L. T. M. performed the D-lactate analysis and with M. Ø. contributed to the writing of the manuscript. All authors contributed to and approved the manuscript.

The authors have no conflict of interest to declare.

References

1. Naylor R, Hardy R, Bureau D, *et al.* (2009) Feeding aquaculture in an era of finite resources. *Proc Natl Acad Sci U S A* **106**, 15103–15110.
2. Gatlin DM, Barrows FT, Brown P, *et al.* (2007) Expanding the utilization of sustainable plant products in aquafeeds: a review. *Aquacult Res* **38**, 551–579.
3. Francis G, Makkar HPS & Becker K (2001) Antinutritional factors present in plant-derived alternate fish feed ingredients and their effects in fish. *Aquaculture* **199**, 197–227.
4. Krogdahl Å, Penn M, Thorsen J, *et al.* (2010) Important antinutrients in plant feedstuffs for aquaculture: an update on recent findings regarding responses in salmonids. *Aquacult Res* **41**, 333–344.
5. Sahlmann C, Sutherland BJG, Kortner TM, *et al.* (2013) Early response of gene expression in the distal intestine of Atlantic salmon (*Salmo salar* L.) during the development of soybean meal induced enteritis. *Fish Shellfish Immunol* **34**, 599–609.
6. Krogdahl Å, Bakke-McKellep A & Baeverfjord G (2003) Effects of graded levels of standard soybean meal on intestinal structure, mucosal enzyme activities, and pancreatic response in Atlantic salmon (*Salmo salar* L.). *Aquacult Nutr* **9**, 361–371.
7. Baeverfjord G & Krogdahl A (1996) Development and regression of soybean meal induced enteritis in Atlantic salmon, *Salmo salar* L., distal intestine: a comparison with the intestines of fasted fish. *J Fish Dis* **19**, 375–387.
8. Penn MH, Bendiksen EÅ, Campbell P, *et al.* (2011) High level of dietary pea protein concentrate induces enteropathy in Atlantic salmon (*Salmo salar* L.). *Aquaculture* **310**, 267–273.
9. Chikwati EM, Sahlmann C, Holm H, *et al.* (2013) Alterations in digestive enzyme activities during the development of diet-induced enteritis in Atlantic salmon, *Salmo sala*r L. *Aquaculture* **402–403**, 28–37.
10. Rogler G & Rosano G (2014) The heart and the gut. *Eur Heart J* **35**, 426–430.
11. Shen L, Su L & Turner JR (2009) Mechanisms and functional implications of intestinal barrier defects. *Dig Dis* **27**, 443–449.
12. Suzuki T (2013) Regulation of intestinal epithelial permeability by tight junctions. *Cell Mol Life Sci* **70**, 631–659.
13. Arrieta MC, Bistritz L & Meddings JB (2006) Alterations in intestinal permeability. *Gut* **55**, 1512–1520.
14. Grootjans J, Thuijls G, Verdam F, *et al.* (2010) Non-invasive assessment of barrier integrity and function of the human gut. *World J Gastrointest Surg* **2**, 61–69.
15. Knudsen D, Jutfelt F, Sundh H, *et al.* (2008) Dietary soya saponins increase gut permeability and play a key role in the onset of soyabean-induced enteritis in Atlantic salmon (*Salmo salar* L.). *Br J Nutr* **100**, 120–129.
16. Sanchez de Medina F, Romero-Calvo I, Mascaraque C, *et al.* (2014) Intestinal inflammation and mucosal barrier function. *Inflamm Bowel Dis* **20**, 2394–2404.
17. Prager M, Durmus T, Buttner J, *et al.* (2014) Myosin IXb variants and their pivotal role in maintaining the intestinal barrier: a study in Crohn's disease. *Scand J Gastroenterol* **49**, 1191–1200.
18. van Wijck K, Verlinden TJM, van Eijk HMH, *et al.* (2013) Novel multi-sugar assay for site-specific gastrointestinal permeability analysis: a randomized controlled crossover trial. *Clin Nutr* **32**, 245–251.
19. DeMeo MT, Mutlu EA, Keshavarzian A, *et al.* (2002) Intestinal permeation and gastrointestinal disease. *J Clin Gastroenterol* **34**, 385–396.

20. Cox MA, Lewis KO & Cooper BT (1999) Measurement of small intestinal permeability markers, lactulose, and mannitol in serum – results in celiac disease. *Dig Dis Sci* **44**, 402–406.
21. Mankertz J & Schulzke JD (2007) Altered permeability in inflammatory bowel disease: pathophysiology and clinical implications. *Curr Opin Gastroenterol* **23**, 379–383.
22. Redl H, Bahrami S, Schlag G, *et al.* (1993) Clinical detection of LPS and animal models of endotoxemia. *Immunobiology* **187**, 330–345.
23. Guidet B, Barakett V, Vassal T, *et al.* (1994) Endotoxemia and bacteremia in patients with sepsis syndrome in the intensive care unit. *Chest* **106**, 1194–1201.
24. Hurley JC (1995) Endotoxemia: methods of detection and clinical correlates. *Clin Microbiol Rev* **8**, 268–292.
25. Jin W, Wang H, Ji Y, *et al.* (2008) Increased intestinal inflammatory response and gut barrier dysfunction in Nrf2-deficient mice after traumatic brain injury. *Cytokine* **44**, 135–140.
26. Luan Z-G, Zhang H, Ma X-C, *et al.* (2010) Role of high-mobility group box 1 protein in the pathogenesis of intestinal barrier injury in rats with severe acute pancreatitis. *Pancreas* **39**, 216–223.
27. Qiao Z, Li ZL, Li JY, *et al.* (2009) Bacterial translocation and change in intestinal permeability in patients after abdominal surgery. *J Huazhong Univ Sci Technolog Med Sci* **29**, 486–491.
28. Szalay L, Umar F, Khadem A, *et al.* (2003) Increased plasma D-lactate is associated with the severity of hemorrhagic/traumatic shock in rats. *Shock* **20**, 245–250.
29. Wang LK, Wang LW, Li X, *et al.* (2013) Ethyl pyruvate prevents inflammatory factors release and decreases intestinal permeability in rats with D-galactosamine-induced acute liver failure. *Hepatobiliary Pancreat Dis Int* **12**, 180–188.
30. Poeze M, Froon AHM, Greve JWM, *et al.* (1998) D-Lactate as an early marker of intestinal ischaemia after ruptured abdominal aortic aneurysm repair. *Br J Surg* **85**, 1221–1224.
31. Schoeffel U, Pelz K, Haring RU, *et al.* (2000) Inflammatory consequences of the translocation of bacteria and endotoxin to mesenteric lymph nodes. *Am J Surg* **180**, 65–72.
32. Ammori BJ, Fitzgerald P, Hawkey P, *et al.* (2003) The early increase in intestinal permeability and systemic endotoxin exposure in patients with severe acute pancreatitis is not associated with systemic bacterial translocation: molecular investigation of microbial DNA in the blood. *Pancreas* **26**, 18–22.
33. Frances R, Benlloch S, Zapater P, *et al.* (2004) A sequential study of serum bacterial DNA in patients with advanced cirrhosis and ascites. *Hepatology* **39**, 484–491.
34. Kane TD, Alexander JW & Johannigman JA (1998) The detection of microbial DNA in the blood: a sensitive method for diagnosing bacteremia and/or bacterial translocation in surgical patients. *Ann Surg* **227**, 1–9.
35. Tipsmark CK & Madsen SS (2012) Tricellulin, occludin and claudin-3 expression in salmon intestine and kidney during salinity adaptation. *Comp Biochem Physiol Part A Mol Integr Physiol* **162**, 378–385.
36. Syakuri H, Adamek M, Brogden G, *et al.* (2013) Intestinal barrier of carp (*Cyprinus carpio* L.) during a cyprinid herpes virus 3-infection: molecular identification and regulation of the mRNA expression of claudin encoding genes. *Fish Shellfish Immunol* **34**, 305–314.
37. Olsen RE, Sundell K, Mayhew TM, *et al.* (2005) Acute stress alters intestinal function of rainbow trout, *Oncorhynchus mykiss* (Walbaum). *Aquaculture* **250**, 480–495.
38. Sundh H, Kvamme BO, Fridell F, *et al.* (2010) Intestinal barrier function of Atlantic salmon (*Salmo salar* L.) post smolts is reduced by common sea cage environments and suggested as a possible physiological welfare indicator. *BMC Physiol* **10**, 22.
39. Johnson IT, Gee JM, Price K, *et al.* (1986) Influence of saponins on gut permeability and active nutrient transport *in vitro*. *J Nutr* **116**, 2270–2277.
40. Merrifield DL, Dimitroglou A, Bradley G, *et al.* (2009) Soybean meal alters autochthonous microbial populations, microvilli morphology and compromises intestinal enterocyte integrity of rainbow trout, *Oncorhynchus mykiss* (Walbaum). *J Fish Dis* **32**, 755–766.
41. Øverland M, Karlsson A, Mydland LT, *et al.* (2013) Evaluation of *Candida utilis, Kluyveromyces marxianus* and *Saccharomyces cerevisiae* yeasts as protein sources in diets for Atlantic salmon (*Salmo salar*). *Aquaculture* **402–403**, 1–7.
42. Romarheim OH, Skrede A, Gao Y, *et al.* (2006) Comparison of white flakes and toasted soybean meal partly replacing fish meal as protein source in extruded feed for rainbow trout (*Oncorhynchus mykiss*). *Aquaculture* **256**, 354–364.
43. Collins SA, Desai AR, Mansfield GS, *et al.* (2012) The effect of increasing inclusion rates of soybean, pea and canola meals and their protein concentrates on the growth of rainbow trout: concepts in diet formulation and experimental design for ingredient evaluation. *Aquaculture* **344–349**, 90–99.
44. Heikkinen J, Vielma J, Kemiläinen O, *et al.* (2006) Effects of soybean meal based diet on growth performance, gut histopathology and intestinal microbiota of juvenile rainbow trout (*Oncorhynchus mykiss*). *Aquaculture* **261**, 259–268.
45. Refstie S, Korsøen ØJ, Storebakken T, *et al.* (2000) Differing nutritional responses to dietary soybean meal in rainbow trout (*Oncorhynchus mykiss*) and Atlantic salmon (*Salmo salar*). *Aquaculture* **190**, 49–63.
46. Lee KK & Yum KS (2012) Association of endotoxins and colon polyp: a case–control study. *J Korean Med Sci* **27**, 1062–1065.
47. Guzman-de la Garza FJ, Ibarra-Hernandez JM, Cordero-Perez P, *et al.* (2013) Temporal relationship of serum markers and tissue damage during acute intestinal ischemia/reperfusion. *Clinics* **68**, 1034–1038.
48. Sedman PC, Macfie J, Sagar P, *et al.* (1994) The prevalence of gut translocation in humans. *Gastroenterology* **107**, 643–649.
49. Balzan S, De Almeida Quadros C, De Cleva R, *et al.* (2007) Bacterial translocation: overview of mechanisms and clinical impact. *J Gastroenterol Hepatol* **22**, 464–471.
50. Berg RD & Garlington AW (1979) Translocation of certain indigenous bacteria from the gastrointestinal tract to the mesenteric lymph nodes and other organs in a gnotobiotic mouse model. *Infect Immun* **23**, 403–411.
51. Ringø E, Myklebust R, Mayhew TM, *et al.* (2007) Bacterial translocation and pathogenesis in the digestive tract of larvae and fry. *Aquaculture* **268**, 251–264.
52. O'Boyle CJ, MacFie J, Mitchell CJ, *et al.* (1998) Microbiology of bacterial translocation in humans. *Gut* **42**, 29–35.
53. Van Nieuwenhoven MA, Geerling BJ, Deutz NEP, *et al.* (1999) The sensitivity of the lactulose/rhamnose gut permeability test. *Eur J Clin Invest* **29**, 160–165.
54. Bjarnason I, Macpherson A & Hollander D (1995) Intestinal permeability: an overview. *Gastroenterology* **108**, 1566–1581.
55. Sun XQ, Fu XB, Zhang R, *et al.* (2001) Relationship between plasma D-lactate and intestinal damage after severe injuries in rats. *World J Gastroenterol* **7**, 555–558.
56. Assadian A, Assadian O, Senekowitsch C, *et al.* (2006) Plasma D-lactate as a potential early marker for colon ischaemia after open aortic reconstruction. *Eur J Vasc Endovasc Surg* **31**, 470–474.
57. Zhao Y, Qin G, Sun Z, *et al.* (2011) Effects of soybean agglutinin on intestinal barrier permeability and tight junction protein expression in weaned piglets. *Int J Mol Sci* **12**, 8502–8512.
58. Dahhak S, Uhlen S, Mention K, *et al.* (2008) D-Lactic acidosis in a child with short bowel syndrome [article in French]. *Arch Pediatr* **15**, 145–148.
59. Hove H & Mortensen P (1995) Colonic lactate metabolism and D-lactic acidosis. *Dig Dis Sci* **40**, 320–330.

II

The effect of plant-based diet and suboptimal environmental conditions on digestive function and diet-induced enteropathy in rainbow trout (*Oncorhynchus mykiss*)

Peyman Mosberian-Tanha [1], Johan W Schrama [2], Thor Landsverk [3], Liv T Mydland [1],

Margareth Øverland*[1]

[1] *Department of Animal and Aquacultural Sciences, Norwegian University of Life Sciences, Ås, Norway*

[2] *Aquaculture and Fisheries Group, Wageningen Institute of Animal Sciences, Wageningen, the Netherlands*

[3] *Department of Basic Sciences and Aquatic Medicine, School of Veterinary Medicine, Norwegian University of Life Sciences, Oslo, Norway*

[*] Correspondence: Margareth Øverland, Norwegian University of Life Sciences, NO-1432 Ås, Norway, Email: margareth.overland@nmbu.no

Running title:

Plant-based diet at suboptimal environment

Key words: apparent digestibility coefficients, hypoxia, enteritis, digestive function, rainbow trout, soybean meal

Abstract

The aim of this experiment was to investigate intestinal enteropathy and digestive function of rainbow trout challenged with a soybean meal (SBM)-based diet at optimal or suboptimal environments created by normal or reduced water flow respectively. Triplicate groups of fish were fed restrictively fishmeal- (FM) or SBM-based diet at optimal environment in period 1 (28 days). At the start of period 2 (42 days), fish were either subjected to a change from FM to SBM diet or remained on the same diet as used in period 1. The fish were also exposed to a change from optimal to suboptimal environment or remained under optimal conditions. During period 2, the fish subjected to change from FM to SBM, irrespective of their environment, showed similar degree of enteropathy from day 14 and onward. Digestibility of lipid and starch was lower in fish fed SBM and kept at suboptimal environment compared to fish fed the same diet but kept at optimal environment. Digestibility of crude protein, however, was highest in these fish throughout period 2. In conclusion, in rainbow trout fed SBM, exposure to suboptimal environment did not change the degree of enteropathy, however, lipid and starch digestibility were further reduced.

Introduction

The use of plant ingredients in salmonid feed to improve sustainability of aquaculture, may lead to challenges including impaired digestive function, reduced growth, and increased risk of developing gastro-intestinal disorders such as soybean meal-induced enteritis (SBMIE). The negative effects of plant ingredients are attributed to the presence of non-starch polysaccharides (NSP) and anti-nutritional factors (ANF). SBM has been used as a model to study the effect of plant ingredients on gut health and function of salmonids (Krogdahl *et al.* 2003; Romarheim *et al.* 2008; Urán *et al.* 2008; Mosberian-Tanha *et al.* 2016). The inclusion of SBM have shown to adversely affect the apparent digestibility coefficients (ADC) of nutrients and energy (Opstvedt *et al.* 2003; Romarheim *et al.* 2006). Furthermore, it has been shown that SBM can reduce activity of digestive enzymes in the distal intestine (DI) of Atlantic salmon (*Salmo salar*) (Krogdahl *et al.* 2003; Chikwati *et al.* 2013). The reduced activity of digestive function may partly be due to the morphological changes caused by SBMIE. Although DI is not the main site for macronutrient absorption, some important components such as taurine and bile acids have been shown to be re-absorbed in the DI (Nordrum *et al.* 2000) with possible implications for the absorption of lipid in the proximal parts of the intestine. Morphological changes associated with SBMIE may disturb the capacity of digestion and re-absorption of nutritionally important substances in the DI and thus contribute to the lower ADC of nutrients. ADC of lipid in particular has shown to be reduced in Atlantic salmon fed SBM (Krogdahl *et al.* 2003; Romarheim *et al.* 2006). The reduction in ADC of lipid could be a result of the reduction in bile acid concentration in intestinal content (Romarheim *et al.* 2006; Yamamoto *et al.* 2012). Changes in digestive function appears to be a more sensitive parameter than changes in the gut morphology as observed in Atlantic cod (*Gadus morhua*), where feeding SBM reduced lipid digestibility (Førde-Skjærvik *et al.* 2006) in the absence of SBMIE (Refstie *et al.* 2006).

Aquaculture is also facing challenges from the environment. Sub-optimal environmental conditions are partly caused by seasonal changes in water temperature and consequently dissolved oxygen (DO) (Oppedal *et al.* 2011) or on a long-term basis by global warming leading to alterations in water quality parameters such as increased temperature and CO_2 level (Lough & Hobday 2011). However, the adverse conditions may also be induced by some production procedures such as reduced water flow/exchange rate in intensive fish farming (Ellis *et al.* 2002).

Water DO level is one of the important environmental factors affected by change in temperature or reduced water flow rate. Low water DO level may induce environmental hypoxia with physiological consequences in fish (Wu 2002). Adverse effect of low water DO on feed intake and growth has been reported in Nile tilapia (*Oreochromis niloticus*) (Tran-Duy *et al.* 2012) and rainbow trout (Glencross 2009). Exposure of the fish to low DO level induced by reduction in water flow, impaired intestinal barrier function and also induced morphological changes in the distal intestine in Atlantic salmon (Sundh *et al.* 2010). Reduced water flow rate is not only associated with stress or low water DO but also increased accumulation of fish excretions such as ammonia in the ambient water (Ellis *et al.* 2002). High ambient ammonia concentration has been reported to reduce feed intake and increase mortality in juvenile lake trout (*Salvelinus namayeush*) (Beamish & Tandler 1990) and under chronic exposure it also causes gill damage and hyperplasia (Meade 1985). In contrary, in another experiment, chronic exposure to sublethal levels of ammonia did not change feed intake in Atlantic salmon kept at 12 ºC (Kolarevic *et al.* 2013).

It is unknown whether there is an interaction between suboptimal environmental conditions and plant-based diets on digestive function and intestinal health in rainbow trout. An experiment was, therefore, conducted to evaluate if exposure to suboptimal environment will aggravate the effect of feeding a SBM-based diet as a dietary challenge on digestive function and intestinal health of rainbow trout.

Materials and methods

Fish and rearing conditions

Six hundred juvenile rainbow trout with mean initial body weight (± SE) of 74.1 ± 0.3g were randomly allocated into 12 tanks (50 fish per tank) at the start of the experiment.

Two isoenergetic and isonitrogenous diets were formulated; one fishmeal-based control (FM) and one containing 40% soybean meal (SBM) as experimental diet. Cellulose was added to the diets as a filler. Yttrium oxide (Y_2O_3) was added to the diets as inert marker for digestibility calculations (Austreng *et al.* 2000). The formulation and composition of the diets are shown in Table 1. The ingredients were ground in a hammer mill (Condux LHM20/16, Hanau, Germany)

fitted with a 1-mm sieve. The diets were produced by Research Diet Service (Wijk bij Duurstede, The Netherlands) by using a twin-screw extruder (Clextral, Firminy, France) equipped with a 3 mm die. The pellets were then dried in a tray-drier at 70 ˚C for 3 hours and cooled to ambient temperature. Each diet was assigned randomly to triplicate tanks (200 L capacity) according to the treatments and fed to the fish manually twice daily throughout the experiment at 9:00 and 16:00 hours for maximum 1 hour. The water flow rate was set at 7.5 L min^{-1} for all tanks during period 1. The fish were kept at photoperiod of 12 L: 12 D, water temperature of 14.0±0.5˚C and pH between 7.0 and 7.5.

Experimental design

The experiment consisted of four treatments and divided into two periods; Period 1; was adaptation period of 28 days to diets and all fish were kept under optimal conditions by setting the water flow rate at 7.5 L min^{-1} and Period 2; an experimental period of 42 days where fish were subjected to either a dietary challenge and/or exposed to suboptimal environment by reducing the water flow rate from 7.5 L min^{-1} to 2.25 L min^{-1}. Water DO level is the key limiting factor when the water flow rate is reduced, however, this treatment also leads to accumulation of metabolites or fish excretions such as ammonia. To simplify nomenclature, low water flow rate is termed hypoxia (HY) and optimal water flow rate is termed normoxia (NO). The four treatments tested in this experiment are as shown in Table 2. Treatment 1 was designed to evaluate if exposure to hypoxia alone would affect digestive function and impair intestinal health. Treatments 2 and 3 were designed to evaluate if change from FM to SBM is more detrimental to digestive function and SBMIE, as an indicator of diet-induced enteropathy, at hypoxia compared to normoxia. Treatment 4 was designed to evaluate if under steady state dietary challenge any change in the environment from normoxia to hypoxia will aggravate digestive function and SBMIE.

The feeding rate was reduced from 1.5% of mean biomass of 12 tanks to 1.25% at the start of period 2. Normoxia resulted in a mean water DO level of above 8 mg L^{-1} in the outlet (>78% saturation). If necessary, pure oxygen was injected into the inlet to maintain the intended DO level. Photoperiod was maintained at 12 L: 12 D, water temperature at 14.0±0.5˚C and pH between 7.0 and 7.5 throughout the experiment. Hypoxia resulted in a mean water DO level of below 6 mg L^{-1} in the outlet (< 55% saturation). The minimum DO level in the outlet, however,

was maintained above 3.8 mg L^{-1} to avoid extreme reduction in feed intake and increased mortality. The mean of DO level (mean ±SD) in the inlet was 10.3±0.3 mg L^{-1}. Water parameters including daily oxygen concentration and pH and also during week five of period 2, total ammonium nitrogen (TAN), nitrite and nitrate were measured for each tank by the method described elsewhere (Saravanan *et al.* 2012).

Sampling procedure

Faeces collection was performed daily throughout the last two weeks of the period 1 and pooled to determine digestibility of nutrients in this period. The faeces collection continued throughout period 2 at four sampling time points, days 0-7, 8-14, 15-21 and 22-42 (faeces samples collected daily and were pooled within these periods). Each tank was connected to one settling tank as previously described (Saravanan *et al.* 2012). A faecal collection bottle (250 ml) was attached to the bottom of the settling tank while placed in a thermostatic box connected to a cooling system to avoid the bacterial degradation of nutrients in the faeces. The faeces collected within weeks from each tank was pooled in the same tray and stored at -20˚C in an aluminium box until further analysis. The settling tank was also used to check and count the uneaten pellets in the respective respiration tank at every feeding for accurate calculation of feed intake. For this purpose another set of 250 ml-bottles were attached to the settling tanks during feeding.

DI tissue samples from 3 fish were taken per tank on days 0, 7, 14, 21 and 42 of period 2. The tissue samples were fixed in neutral buffered formalin (4% formaldehyde) and embedded in paraffin before staining by hematoxylin and eosin (H&E). Blinded evaluation and scoring of the following five morphological parameters was performed on each tissue:

1) Subepithelial infiltration of leukocytes: increased accumulation of leukocytes in the subepithelial area down to stratum compactum.
2) Supranuclear vacuolisation (SNV) of epithelial cells: reduced vacuolisation of the epithelial cells.
3) Atrophy of intestinal folds.
4) Vacuolar degeneration of the epithelial cells: increased vacuolar degeneration in the base of the intestinal folds.

5) The presence, if any, of granulomatous response and the degree of this response: increased proliferation of fibroblasts and aggregation of enlarged macrophages and multi-nucleated giant cells (MGC) along with lymphocytes in the subepithelial tissues.

A score was given to each parameter which ranged from 0 to 3. Increase in the score of each parameter indicates a more severe morphological changes. The overall histopathology score for each fish was calculated by taking the average score of the morphological parameters to express the degree of change in that individual.

Analytical procedure

Feed and oven-dried faeces samples were ground in a blender before further analysis. Dry matter was determined by drying the samples for 4 hours at 103 ˚C until a constant weight was obtained. Crude protein was determined by the Kjeldahl method based on N content × 6.25 (ISO 5983/NEN 3145). Feed and faecal samples were hydrolysed by 3N HCl before crude fat analysis as described in Saravanan *et al.* (2012). Crude fat content was measured following petroleum-ether extraction (Soxhlet method). Gross energy content was determined using a bomb calorimeter (IKA-C7000, IKA-Aanalysentechnik, Weitersheim, Germany). Gross ash was determined after combustion of dried samples in a muffle furnace at 550 ˚C (ISO 5984/NEN 3323). Yttrium was measured by inductively coupled plasma mass spectrometry (ICP-OES). Starch content was determined enzymatically as glucose, liberated by α-amylase and amyloglucosidase hydrolysis (AOAC Method 996.11).

Calculations and statistics

Apparent digestibility coefficients (ADC; %) were calculated as:

$$ADC_X = (1 - Y_{diet}/Y_{faeces} \times X_{faeces}/X_{diet}) \times 100$$

where X represents dry matter, crude protein, crude lipid, starch or energy, Y_{diet} and Y_{faeces} represent the yttrium content (in % of dry matter) in the diet and faeces, respectively, and X_{diet} and X_{faeces} are the content of X (in % of dry matter) in the diet and faeces respectively.

Feed conversion ratio was calculated as:

$$FCR = \text{Feed intake (g, DM)} \times \text{fish weight gain (g)}^{-1}$$

Daily feed intake is expressed as % of the current BW. Current BW was calculated as: $BW_n = BW_{n-1}$ + (current daily DM feed intake × FCR^{-1}).

Statistical analyses were performed using SAS 9.4 (SAS Institute, Cary, NC, USA). All data were tested for normality and homogeneity by Kolmogorov-Smirnov and Bartlett tests. Data from ADC of dry matter in period 1 and overall histopathological score violated the normal distribution assumption after log10-transformation; and thus these data were subjected to non-parametric Kruskal-Wallis test followed by multiple pairwise comparisons (Dwass-Steel-Critchlow-Fligner) if the test was significant. ADC of crude protein, lipid, starch, ash and energy were subjected to one-way analysis of variance (ANOVA) in GLM procedure to test the effect of diet in period 1. The effect of treatment and sampling time on ADC of dry matter, crude protein and ash in period 2 was analysed using a two-way ANOVA in GLM procedure. ADC of lipid and starch at the end of period 2 (day 22-42) were subjected to a one-way ANOVA. Least square means comparison was used to determine which groups differed significantly from each other. Regression analysis was performed to determine the variables that correlated with feed intake at the end of period 2. Differences were declared statistically significant if $P < 0.05$.

Results

Water quality parameters

The water pH level remained stable (ranged from 7.0 to 7.5) throughout the experiment (period 1 and 2) for all treatment groups and hypoxia did not change the pH level (P>0.05). The water DO level (expressed as mg L^{-1}) was above 7.0 mg L^{-1} during period 1 in all tanks (Fig. 1). At the start of period 2, in the tanks assigned to hypoxia, water DO level was reduced to below 5 mg L^{-1} immediately after reduction of water flow rate and remained between 4 to 5 mg L^{-1} during this period (Fig. 2). Water DO level remained above 7.0 mg L^{-1} in period 2. Peaks on the oxygen curve correspond to the days that DI tissue samples were taken. The mean water concentration of TAN during week five of period 2 was significantly higher at hypoxia compared to that observed at normoxia (P=0.002) (Fig. 3). During the same week, water level of nitrite and nitrate at hypoxia were 0.008±0.0003 and 0.22±0.015 mg N L^{-1} (mean ± SE, n=9 tanks) respectively.

At normoxia the concentrations were 0.007 ±0.0009 and 0.18±0.016 mg N L^{-1} (mean ± SE, n=3 tanks). The difference in concentration of nitrite and nitrate was insignificant among treatments.

Feed intake and growth

Feed intake (% body weight) of FM-and SBM-fed fish remained stable throughout period 1 (Fig. 1). The mean feed intake over period 1 was not changed significantly in response to diet (P>0.05).

Feed intake of all treatment groups was not significantly changed during period 2, however, it was reduced in fish fed FM- and SBM-diets and kept at hypoxia during the last two weeks of period 2 (Fig. 2). Feed intake in fish subjected to change from FM to SBM at normoxia (FMNO → SBMNO) in period 2 remained unchanged for the whole period. The mean daily feed intake during period 2 was significantly higher in the fish fed SBM at normoxia (FMNO → SBMNO) than that in other treatment groups (i.e. fish kept at hypoxia) (P=0.005). There was no difference (P>0.05) among treatment groups in weight gain (g day^{-1}), SGR (% day^{-1}) and final body weight (g $fish^{-1}$) in both periods.

Regression analysis revealed that feed intake showed reduction with increasing TAN concentration (R^2= 0.45, P=0.02) (Fig. 4). However, no significant relation was found between changes in feed intake and the following parameters at the end of period 2:

Water DO level (R^2=0.25, P=0.1), pH (R^2=0.15, P=0.21), ADC of crude protein (R^2=0.08, P=0.36), dry matter (R^2=0.15, P=0.20), lipid (R^2=0.01, P=0.72) and starch (R^2=0.03, P=0.58).

Histopathological evaluation

The changes in histopathological scores over time are shown in Fig. 5. These changes were confined to the distal intestine and characterised by reduced apical SNV, reduced height of simple and complex intestinal folds (partial atrophy), and increased number of leukocytes (e.g. lymphocytes, granulocytes and eosinophilic granular cells) in the subepithelial area, the degree of vacuolar degeneration in the base of the folds and the degree of granulomatous change, if present. Exact mean histopathological scores for all treatment groups are given in Table S1.

Exposure to hypoxia did not exert adverse effect on morphological changes in fish fed FM throughout the experiment (steady state diet), but exposed to hypoxia during period 2 (FMNO → FMHY) (P>0.05). Fish fed the SBM diet during period 1, however, developed SBMIE in the DI. The degree of SBMIE remained unchanged in this treatment group over time during period 2

where the fish was exposed to hypoxia (SBMNO → SBMHY) (P>0.05). The two groups of fish subjected to change from FM to SBM, regardless of their environment (i.e. FMNO → SBMHY and FMNO → SBMNO) showed similarly increased histopathological score over time in period 2. By day 14, they reached the same degree of SBMIE as in fish fed SBM throughout the experiment but exposed to suboptimal condition (SBMNO → SBMHY) (Fig. 5). Thus, the degree of SBMIE was stable and similar from day 14 onwards among fish challenged with SBM during period 2, regardless of their environmental conditions.

Digestibility

There was no significant effect of diets on the ADC of starch in period 1 (Table 3), however, ADC of lipid was reduced in fish fed SBM compared to the fish fed FM (P=0.0001). The effect of treatments on ADC of dry matter, crude protein, ash and energy during period 1 are shown in Table 3. ADC of crude protein, ash and energy was higher in fish fed SBM (P <0.05) compared with those fed the FM diets, while the ADC of dry matter tended to increase in these fish (P=0.08).

During period 2, there was no significant difference in any of the ADC values of the fish subjected to change from FM to SBM diet and exposed to hypoxia (FMNO → SBMHY) and of the fish subjected to hypoxia and fed SBM diet throughout the experiment (SBMNO → SBMHY). The fish subjected simultaneously to changes in diet and environment (FMNO → SBMHY) and the fish fed SBM continuously (steady state), but subjected to hypoxia in period 2 (SBMNO → SBMHY) showed the lowest ADC of lipid and starch at the end of period 2 (Fig. 6). ADC of lipid and starch were highest in the group fed FM throughout the experiment, but exposed to hypoxia (FMNO → FMHY) (P=0.001). ADC values of lipid and starch were higher in the fish subjected to dietary change from FM to SBM and kept at normoxia (FMNO → SBMNO) than in the fish fed SBM and exposed to hypoxia during period 2 (FMNO → SBMHY and SBMNO → SBMHY) (P=0.002). In the fish fed FM throughout the experiment but exposed to hypoxia in period 2 (FMNO → FMHY), the ADC of dry matter reached its highest value by day 42. ADC of dry matter, was, however, gradually reduced from day 7 to 21 in the fish subjected to changes in both diet and environment (FMNO → SBMHY). Similar trend was also observed in the fish challenged by SBM but kept at normoxia (FMNO → SBMNO). There were, however, no differences in ADC of dry matter among any groups challenged by SBM regardless of the type

of the environment by day 42. ADC of crude protein and ash in all treatment groups remained unchanged throughout period 2. ADC of crude protein was, however, highest in groups fed SBM at hypoxia (FMNO → SBMHY and SBMNO → SBMHY) at all time points and lowest in fish fed FM (steady state), but subjected to change to hypoxia (FMNO → FMHY). At hypoxia, changing from FM to SBM increased the ADC of ash significantly at day 7 compared to steady state FM feeding (FMNO → FMHY). The difference in ADC of ash was insignificant among treatments by day 42. ADC of energy was found to be highest in the fish challenged by SBM and kept at normoxia (FMNO → SBMNO) (P=0.01), however, no significant difference was observed among other treatments (P >0.05).

Discussion

This study was performed to investigate if exposure to suboptimal environment (i.e. hypoxia) aggravates the effect of SBM on digestive function and intestinal enteropathy in rainbow trout over time. We evaluated the gastrointestinal status by monitoring digestive function and progression of SBMIE in rainbow trout in response to the challenges over time.

It is known that oxygen is less available to aquatic than air-breathing animals and the uptake of oxygen from water is more challenging (Kramer 1987). Thus, it is likely that reduction of DO level in this study was a challenging factor. We observed that the fish activity (locomotion) was lower in the hypoxia tanks. This is in accordance with previous observations of Nile tilapia kept at different degrees of hypoxia (Tran-Duy *et al.* 2012). Reduced activity of the fish could be a response to reduced DO level as a mechanism of adaptation (Kramer 1987). Reduction in feed intake is another response which is reported to occur under hypoxic conditions (Tran-Duy *et al.* 2012) as feed intake is an oxygen demanding process. In this study, however, the feed intake during the four weeks after exposure to hypoxia remained unchanged in all treatment groups, indicating that low DO level did not affect feed intake. Fish were fed restrictively which may explain why the low DO level did not adversely affect feed intake. Glencross (2009) reported that feed intake under hypoxia did not differ from normoxia when fish were fed restrictively for 28 days. The reduction in feed intake during the last two weeks of period 2, however, could be a response to accumulation of ammonia due to the reduced water flow rate. Previous publications have reported adverse effect of elevated environmental ammonia level on feed intake in rainbow

trout (Ortega *et al.* 2005) and European sea bass (*Dicentrarchus labrax*) (Dosdat *et al.* 2003) and juvenile lake trout (*Salvelinus namayeush*) (Beamish & Tandler 1990). The highest TAN concentration in this study was well below the levels tested in those experiments, however, the slight but significant accumulation of ammonia may have been a challenging factor to the fish already affected by reduced DO level at hypoxia. Thus, it is possible that the combination of increased TAN and reduced water DO level caused reduction in feed intake in this experiment. Kolarevic *et al.* (2013) also showed that exposure to sublethal levels of TAN at normoxic condition did not change feed intake significantly in Atlantic salmon.

The development of SBMIE in rainbow trout fed the SBM diet during period 1 was expected and coincided with previous findings (Baeverfjord & Krogdahl 1996; Romarheim *et al.* 2008). Exposure to hypoxia in this experiment did not aggravate SBMIE in fish fed SBM. Furthermore, feeding FM at hypoxia did not result in any signs of inflammation in the DI of rainbow trout. It is in contrary to the earlier publication reporting some morphological changes such as atrophy of intestinal folds in Atlantic salmon kept at hypoxia and temperature of 16 ºC (corresponding to 50% saturation) (Sundh *et al.* 2010). This may indicate that exposure to hypoxia alone did not induce pathological responses in rainbow trout. It is possible that rainbow trout is more resistant to the adverse changes in the environmental conditions such as hypoxia than Atlantic salmon. This may also be due to the high inclusion level of SBM (40%) used in the present experiment leading to histopathology score of 2 or higher in all fish from day 14. Thus, the effect of SBM diet may have concealed any possible additional effect of suboptimal environment on intestinal health. SBM diet induced significant morphological changes after 7 days of period 2 in fish subjected to SBM independent of the environment, which is in agreement with the study in Atlantic salmon (Urán *et al.* 2009). At day 14 and onward, all SBM-fed fish had similar histopathology score regardless of their environment, implying that there was no effect of feed intake, steady state SBM consumption and suboptimal conditions (reduced water flow rate) on this parameter, even at longer time of exposure.

The reduction in ADC of lipid in fish fed SBM compared to the fish fed FM in period 1 confirms previous reports (Refstie *et al.* 1998; Romarheim *et al.* 2006; Øverland *et al.* 2009). This trend was also observed 42 days after the change from the FM to SBM diet at normoxia and hypoxia. The ADC of starch in this study was close to the values previously reported in rainbow trout

(Krogdahl *et al.* 2004; Romarheim *et al.* 2006). Earlier publications have shown that starch can be highly digestible for carnivorous fish after hydrothermal treatment of the feed resulting in starch gelatinisation (Bergot & Breque 1983; Panserat 2009). Furthermore, lower intake of dietary starch under restrictive feeding has also been reported to improve ADC of starch (Bergot & Breque 1983). The fact that ADC of starch did not differ significantly between SBM and FM during period 1 is in accordance with some earlier studies (Romarheim *et al.* 2006; Romarheim *et al.* 2012). The further reduction in ADC of lipid and starch in two groups of fish kept at hypoxia and fed SBM (steady state and subject to change from FM to SBM), suggests that there is an adverse additive effect of dietary challenge and suboptimal environment in the present study on digestive function of the fish. The degree of SBMIE did not differ between hypoxia- and normoxia-treated fish. This indicates that the changes in ADC of lipid and starch is independent of SBMIE. A possible explanation is that reduced activity of the fish at hypoxia, may have led to slower gastrointestinal peristaltic movement than that at normoxia, which consequently increased the interaction time of lipids and starch with ANFs including NSPs in SBM diet. This in turn aggravated the adverse effect of ANFs on ADC of these nutrients. There are different types of ANFs in SBM, the function of which are not yet fully understood (Francis *et al.* 2001). Some fraction of ANFs may interact with components essential for lipid digestion and reduce the ADC of lipid. An example is saponins which have been suggested to reduce lipase activity, leading to reduced ADC of lipid (Han *et al.* 2000). NSPs may also reduce digestibility of different nutrients such as starch by increasing the viscosity of the digesta (Leenhouwers *et al.* 2006) or reducing brush border enzymes activity and bile acid concentration (Kraugerud *et al.* 2007). It is also possible that starch-lipid interaction was intensified to a significant level at hypoxia due to reduced transit time of the digesta. This in turn may have increased amylose-lipid complexes increasing amylose resistance to α-amylase (Holm *et al.* 1983). Overall this result also indicates that digestive function is more sensitive than the DI enteropathy in rainbow trout exposed to a dietary challenge under suboptimal conditions.

The lower ADC of crude protein in fish fed the FM diet during period 1 compared to the fish fed the SBM diet contradicts previous results (Øverland *et al.* 2009). Cellulose inclusion level was relatively high in the FM diet, but Hansen & Storebakken (2007) showed that cellulose does not affect ADC of protein, lipid and starch. Reduced ADC of FM compared to SBM may be due to the faeces collection method used in this experiment. In this experiment faeces was collected in

bottles mounted to the settling tanks and remained in the bottle for 23 hours which may result in leaching of nutrients. Leaching has been discussed previously as a problem associated with the use of columns for faeces collection (Storebakken *et al.* 1998; Vandenberg & De La Noüe 2001). The same method of faeces collection was used in this experiment for all treatment groups, however, leaching rate of nitrogen may differ for different diets. Physical and chemical properties of the faecal matter from SBM diet is different from that of FM diet. For example faecal matter from SBM diet has shown to contain less dry matter due to diarrhea (Refstie *et al.* 2000; Refstie *et al.* 2005). The properties of faecal matter from SBM diet may have resulted in a higher rate of nitrogen leaching than for that for FM diet. This proposed effect of faeces collection method, however, was not reflected in ADC of starch and lipid. The observed stability in ADC of crude protein during the first four weeks of period 2 may be explained by the stable feed intake during this period. However, reduction of feed intake during the last two weeks of period 2 did not affect ADC of crude protein in fish kept at hypoxia regardless of the diet. The finding is in accordance with a previous report of no change in ADC of crude protein in European sea bass with chronic exposure to high water TAN level (Dosdat *et al.* 2003).

The higher ADC of dry matter and energy in fish fed the SBM diet in the present experiment may be a result of the high inclusion level of cellulose in the FM diet. The results are in agreement with Glencross *et al.* (2012) whom also showed reduced ADC of dry matter and energy with higher percentage of cellulose in diet. However, the results show no significant difference in ADC of energy after 42 days of feeding in period 2 among the fish fed FM and SBM (steady state and subject to change from FM to SBM) at hypoxia. The reason for this observation may be the overall result of lower ADC of lipid and starch in fish subjected to SBM at hypoxia and reduced ADC of dry matter and crude protein in the fish fed FM at the same environment. Another observation in this experiment is the increasing trend of ADC of dry matter in period 2 which was started from day 14 and 21 in fish fed FM at hypoxia and in the fish fed SBM at hypoxia and normoxia, which may be an indication of adaptation in rainbow trout to the new environment and/or diet.

Conclusions

To conclude, the suboptimal environment used in this experiment did not induce or aggravate the changes associated with SBMIE or adversely affect the ADC of nutrients in rainbow trout. However, fish subjected to the dietary challenge at suboptimal environment showed further reduction in digestibility of starch and lipid without change in the degree of SBMIE when compared to the fish exposed to dietary challenge alone. These results indicate that there was an interaction between feeding plant-based diets and exposure to suboptimal environmental condition on digestive function of rainbow trout.

Acknowledgements

This study was funded by AQUAEXCEL (Aquaculture Infrastructures for Excellence in European Fish Research) project no 0071/05/13/30/A and also supported by Foods of Norway, a Centre for Research- based Innovation (the Research Council of Norway; grant no. 237841/030). We would like to thank Menno ter Veld for assistance in operating the experimental facility and also Ronald Booms and Tino Leffering for technical assistance during chemical analysis.

References

Austreng, E., Storebakken, T., Thomassen, M.S., Refstie, S. & Thomassen, Y. (2000). Evaluation of selected trivalent metal oxides as inert markers used to estimate apparent digestibility in salmonids. *Aquaculture,* **188,** 65-78.

Baeverfjord, G. & Krogdahl, A. (1996). Development and regression of soybean meal induced enteritis in Atlantic salmon, *Salmo salar* L., distal intestine: a comparison with the intestines of fasted fish. *J. Fish Dis.,* **19,** 375-387.

Beamish, F.W.H. & Tandler, A. (1990). Ambient ammonia, diet and growth in lake trout. *Aquat. Toxicol.,* **17,** 155-166.

Bergot, F. & Breque, J. (1983). Digestibility of starch by rainbow trout: Effects of the physical state of starch and of the intake level. *Aquaculture,* **34,** 203-212.

Chikwati, E.M., Sahlmann, C., Holm, H., Penn, M.H., Krogdahl, Å. & Bakke, A.M. (2013). Alterations in digestive enzyme activities during the development of diet-induced enteritis in Atlantic salmon, *Salmo sala*r L. *Aquaculture,* **402–403,** 28-37.

Dosdat, A., Ruyet, J.P.-L., Covès, D., Dutto, G., Gasset, E., Le Roux, A. & Lemarié, G. (2003). Effect of chronic exposure to ammonia on growth, food utilisation and metabolism of the European sea bass (Dicentrarchus labrax). *Aquat. Living Resour.,* **16,** 509-520.

Ellis, T., North, B., Scott, A.P., Bromage, N.R., Porter, M. & Gadd, D. (2002). The relationships between stocking density and welfare in farmed rainbow trout. *J. Fish Biol.,* **61,** 493-531.

Francis, G., Makkar, H.P.S. & Becker, K. (2001). Antinutritional factors present in plant-derived alternate fish feed ingredients and their effects in fish. *Aquaculture,* **199,** 197-227.

Førde-Skjærvik, O., Refstie, S., Aslaksen, M. & Skrede, A. (2006). Digestibility of diets containing different soyabean meals in Atlantic cod (*Gadus morhua*); comparison of collection methods and mapping of digestibility in different sections of the gastrointestinal tract. *Aquaculture,* **261,** 241-258.

Glencross, B., Rutherford, N. & Bourne, N. (2012). The influence of various starch and non-starch polysaccharides on the digestibility of diets fed to rainbow trout (*Oncorhynchus mykiss*). *Aquaculture,* **356–357,** 141-146.

Glencross, B.D. (2009). Reduced water oxygen levels affect maximal feed intake, but not protein or energy utilization efficiency of rainbow trout (*Oncorhynchus mykiss*). *Aquacult. Nutr.,* **15,** 1-8.

Han, L.K., Xu, B.J., Kimura, Y., Zheng, Y.N. & Okuda, H. (2000). Platycodi radix affects lipid metabolism in mice with high fat diet–induced obesity. *J. Nutr.,* **130,** 2760-2764.

Hansen, J.Ø. & Storebakken, T. (2007). Effects of dietary cellulose level on pellet quality and nutrient digestibilities in rainbow trout (*Oncorhynchus mykiss*). *Aquaculture,* **272,** 458-465.

Holm, J., Björck, I., Ostrowska, S., Eliasson, A.C., Asp, N.G., Larsson, K. & Lundquist, I. (1983). Digestibility of Amylose-Lipid Complexes in-vitro and in-vivo. *Starch - Stärke,* **35,** 294-297.

Kolarevic, J., Selset, R., Felip, O., Good, C., Snekvik, K., Takle, H., Ytteborg, E., Baeverfjord, G., Asgard, T. & Terjesen, B.F. (2013). Influence of long term ammonia exposure on Atlantic salmon (Salmo salar L.) parr growth and welfare. *Aquacult. Res.,* **44,** 1649-1664.

Kramer, D.L. (1987). Dissolved oxygen and fish behavior. *Environ. Biol. Fishes,* **18,** 81-92.

Kraugerud, O.F., Penn, M., Storebakken, T., Refstie, S., Krogdahl, Å. & Svihus, B. (2007). Nutrient digestibilities and gut function in Atlantic salmon (*Salmo salar*) fed diets with cellulose or non-starch polysaccharides from soy. *Aquaculture,* **273,** 96-107.

Krogdahl, Å., Bakke-Mckellep, A. & Baeverfjord, G. (2003). Effects of graded levels of standard soybean meal on intestinal structure, mucosal enzyme activities, and pancreatic response in Atlantic salmon (*Salmo salar* L.). *Aquacult. Nutr.,* **9,** 361-371.

Krogdahl, Å., Sundby, A. & Olli, J.J. (2004). Atlantic salmon (*Salmo salar*) and rainbow trout (*Oncorhynchus mykiss*) digest and metabolize nutrients differently. Effects of water salinity and dietary starch level. *Aquaculture,* **229,** 335-360.

Leenhouwers, J.I., Adjei-Boateng, D., Verreth, J.a.J. & Schrama, J.W. (2006). Digesta viscosity, nutrient digestibility and organ weights in African catfish (*Clarias gariepinus*) fed diets supplemented with different levels of a soluble non-starch polysaccharide. *Aquacult. Nutr.,* **12,** 111-116.

Lough, J.M. & Hobday, A.J. (2011). Observed climate change in Australian marine and freshwater environments. *Mar. Freshwater. Res. ,* **62,** 984-999.

Meade, J.W. (1985). Allowable Ammonia for Fish Culture. *Prog. Fish. Cult.,* **47,** 135-145.

Mosberian-Tanha, P., Øverland, M., Landsverk, T., Reveco, F.E., Schrama, J.W., Roem, A.J., Agger, J.W. & Mydland, L.T. (2016). Bacterial translocation and *in vivo* assessment of intestinal barrier permeability in rainbow trout (*Oncorhynchus mykiss*) with and without soyabean meal-induced inflammation. *J. Nutr. Sci.,* **5,** e26 (10 pages).

Nordrum, S., Krogdahl, Å., Røsjø, C., Olli, J.J. & Holm, H. (2000). Effects of methionine, cysteine and medium chain triglycerides on nutrient digestibility, absorption of amino acids along the intestinal tract and nutrient retention in Atlantic salmon (*Salmo salar* L.) under pair-feeding regime. *Aquaculture,* **186,** 341-360.

Oppedal, F., Dempster, T. & Stien, L.H. (2011). Environmental drivers of Atlantic salmon behaviour in sea-cages: A review. *Aquaculture,* **311,** 1-18.

Opstvedt, J., Nygârd, E., Samuelsen, T.A., Venturini, G., Luzzana, U. & Mundheim, H. (2003). Effect on protein digestibility of different processing conditions in the production of fish meal and fish feed. *J. Sci. Food Agric.,* **83,** 775-782.

Ortega, V.A., Renner, K.J. & Bernier, N.J. (2005). Appetite-suppressing effects of ammonia exposure in rainbow trout associated with regional and temporal activation of brain monoaminergic and CRF systems. *J. Exp. Biol.,* **208,** 1855-1866.

Panserat, S. (2009). Molecular Regulation of Intermediary Metabolism Focusing on Utilization of Dietary Carbohydrates. . In*: In: Molecular Research in Aquaculture (Overturf, K. ed.), pp. 261-278.* ed. Wiley-Blackwell, Oxford, UK.

Refstie, S., Korsøen, Ø.J., Storebakken, T., Baeverfjord, G., Lein, I. & Roem, A.J. (2000). Differing nutritional responses to dietary soybean meal in rainbow trout (Oncorhynchus mykiss) and Atlantic salmon (Salmo salar). *Aquaculture,* **190,** 49-63.

Refstie, S., Landsverk, T., Bakke-Mckellep, A.M., Ringø, E., Sundby, A., Shearer, K.D. & Krogdahl, Å. (2006). Digestive capacity, intestinal morphology, and microflora of 1-year and 2-year old Atlantic cod (*Gadus morhua*) fed standard or bioprocessed soybean meal. *Aquaculture,* **261,** 269-284.

Refstie, S., Sahlström, S., Bråthen, E., Baeverfjord, G. & Krogedal, P. (2005). Lactic acid fermentation eliminates indigestible carbohydrates and antinutritional factors in soybean meal for Atlantic salmon (*Salmo salar*). *Aquaculture,* **246,** 331-345.

Refstie, S., Storebakken, T. & Roem, A. (1998). Feed consumption and conversion in Atlantic salmon (*Salmo salar*) fed diets with fish meal, extracted soybean meal or soybean meal with

reduced content of oligosaccharides, trypsin inhibitors, lectins and soya antigens. *Aquaculture,* **162,** 301-312.

Romarheim, O.H., Hetland, D.L., Skrede, A., Øverland, M., Mydland, L.T. & Landsverk, T. (2012). Prevention of soya-induced enteritis in Atlantic salmon (*Salmo salar*) by bacteria grown on natural gas is dose dependent and related to epithelial MHC II reactivity and CD8α+ intraepithelial lymphocytes. *Br. J. Nutr.,* **109,** 1-9.

Romarheim, O.H., Skrede, A., Gao, Y., Krogdahl, Å., Denstadli, V., Lilleeng, E. & Storebakken, T. (2006). Comparison of white flakes and toasted soybean meal partly replacing fish meal as protein source in extruded feed for rainbow trout (*Oncorhynchus mykiss*). *Aquaculture,* **256,** 354-364.

Romarheim, O.H., Skrede, A., Penn, M., Mydland, L.T., Krogdahl, A. & Storebakken, T. (2008). Lipid digestibility, bile drainage and development of morphological intestinal changes in rainbow trout (*Oncorhynchus mykiss*) fed diets containing defatted soybean meal. *Aquaculture,* **274,** 329-338.

Saravanan, S., Geurden, I., Figueiredo-Silva, A.C., Kaushik, S.J., Haidar, M.N., Verreth, J.A. & Schrama, J.W. (2012). Control of voluntary feed intake in fish: a role for dietary oxygen demand in Nile tilapia (Oreochromis niloticus) fed diets with different macronutrient profiles. *Br. J. Nutr.,* **108,** 1519-29.

Storebakken, T., Kvien, I.S., Shearer, K.D., Grisdale-Helland, B., Helland, S.J. & Berge, G.M. (1998). The apparent digestibility of diets containing fish meal, soybean meal or bacterial meal fed to Atlantic salmon (*Salmo salar*): evaluation of different faecal collection methods. *Aquaculture,* **169,** 195-210.

Sundh, H., Kvamme, B.O., Fridell, F., Olsen, R.E., Ellis, T., Taranger, G.L. & Sundell, K. (2010). Intestinal barrier function of Atlantic salmon (*Salmo salar* L.) post smolts is reduced by common sea cage environments and suggested as a possible physiological welfare indicator. *BMC Physiol.,* **10,** 22.

Tran-Duy, A., Van Dam, A.A. & Schrama, J.W. (2012). Feed intake, growth and metabolism of Nile tilapia (*Oreochromis niloticus*) in relation to dissolved oxygen concentration. *Aquacult. Res.,* **43,** 730-744.

Urán, P.A., Aydin, R., Schrama, J.W., Verreth, J.a.J. & Rombout, J.H.W.M. (2008). Soybean meal-induced uptake block in Atlantic salmon, *Salmo salar*, distal enterocytes. *J. Fish Biol.,* **73,** 2571-2579.

Urán, P.A., Schrama, J.W., Rombout, J.H.W.M., Taverne-Thiele, J.J., Obach, A., Koppe, W. & Verreth, J.a.J. (2009). Time-related changes of the intestinal morphology of Atlantic salmon, *Salmo salar* L., at two different soybean meal inclusion levels. *J. Fish Dis.,* **32,** 733-744.

Vandenberg, G.W. & De La Noüe, J. (2001). Apparent digestibility comparison in rainbow trout (Oncorhynchus mykiss) assessed using three methods of faeces collection and three digestibility markers. *Aquacult. Nutr.,* **7,** 237-245.

Wu, R.S.S. (2002). Hypoxia: from molecular responses to ecosystem responses. *Mar. Pollut. Bull.,* **45,** 35-45.

Yamamoto, T., Murashita, K., Matsunari, H., Sugita, T., Furuita, H., Iwashita, Y., Amano, S. & Suzuki, N. (2012). Influence of dietary soy protein and peptide products on bile acid status and distal intestinal morphology of rainbow trout (*Oncorhynchus mykiss*). *Fish. Sci.,* **78,** 1273-1283.

Øverland, M., Sørensen, M., Storebakken, T., Penn, M., Krogdahl, Å. & Skrede, A. (2009). Pea protein concentrate substituting fish meal or soybean meal in diets for Atlantic salmon (*Salmo salar*)-Effect on growth performance, nutrient digestibility, carcass composition, gut health, and physical feed quality. *Aquaculture,* **288,** 305-311.

Figure legends

Fig. 1. Feed intake (expressed as % of bodyweight) of rainbow trout (*Oncorhynchus mykiss*) (means ± SE) fed fish meal (FM) or soybean meal (SBM) and kept at normoxia (high water flow rate) in period 1. Each data point on diet curves, is the mean of three tanks for one day. The DO level is the mean of all tanks (*n*=12).

Fig. 2. Feed intake (expressed as % of bodyweight) of rainbow trout (*Oncorhynchus mykiss*) (means ± SE) subjected to change in diet and/or environment (hypoxia) in period 2. (A) Treatment groups subjected to challenging environment (hypoxia). One treatment remained on the fish meal (FM) diet supplied in period 1 (steady state dietary condition) (FMNO → FMHY). One treatment group was subjected to change from FM diet to soybean meal (SBM) diet (FMNO→ SBMHY) and another treatment remained on SBM diet (steady state dietary challenge) (SBMNO→SBMHY). (B) Treatment group kept at normoxia. Fish in this group was subjected to change from FM diet supplied in period 1 to SBM diet (FMNO→SBMNO) in period 2. Each data point is the diet mean of three tanks for one day. The DO line in (A) is the mean of all low flow tanks in period 2 (*n*=9) and in (B) is the mean of high flow tanks (*n*=3).

Fig. 3. Total ammonia nitrogen (TAN) level in each treatment group during week five of period 2. Ambient TAN level increased (*P*=0.002) in the three treatments exposed to hypoxia regardless of their dietary regimen. Values are mean (*n*=3) ± SE.

Fig. 4. The regression of water total ammonia nitrogen (TAN) level against feed intake (% body weight) during week five of period 2.

Fig. 5. Morphological changes in the distal intestine of rainbow trout (*Oncorhynchus mykiss*) (*n*=9 fish treatment^{-1}) over time in period 2. Scores are based on average of the five parameters

used in evaluation of SBMIE; sub-epithelium infiltration of leukocytes, supranuclear vacuolisation of apical epithelial cells, atrophy of intestinal folds and the degree of basal-fold vacuolar degeneration and granuloma. Fish was challenged with soybean meal and/or hypoxia during period 2. NO, normoxia; HY, hypoxia. Values at day 0 are histopathological scores at the end of period 1.

Fig. 6. Apparent digestibility of starch and lipid of rainbow trout (*Oncorhynchus mykiss*) subjected to change in diet and/or hypoxia at the end of period 2. Values are means (n=3) ± SE.

Table 1 Diet formulation and chemical composition of experimental diets fed to rainbow trout (*Oncorhynchus mykiss*)

	FM	SBM
Ingredients (g kg^{-1})		
Fish meal [a]	540.0	250.0
Soybean meal [b]	-	400.0
Wheat flour [c]	170.0	140.0
Rapeseed oil	100.0	120.9
Fish oil [d]	40.0	40.0
Cellulose	143.4	30.0
Monocalcium phosphate [e]	-	10.0
DL-methionine [f]	-	2.5
Yttrium oxide [g]	0.1	0.1
Vitamin/mineral premix [h]	6.5	6.5
Proximate analysis		
Dry matter (g kg^{-1})	949.0	957.0
Crude protein (g kg^{-1})	430.0	427.0
Crude lipid (g kg^{-1})	206.0	220.0
Non-starch polysaccharides (g kg^{-1}) [i]	155.0	164.0
Starch (g kg^{-1})	130.0	113.0
Ash (g kg^{-1})	79.0	76.0
Gross energy (MJ kg^{-1})	23.0	23.2

FM, fishmeal; SBM, soybean meal

[a] TripleNine Fish Protein, Esbjerg, Denmark.

[b] Cargill, Amsterdam, The Netherlands.

[c] Meneba, Weert, The Netherlands.

[d] Coppens International, Helmond, The Netherlands.

[e] Tessenderlo Chemie, Rotterdam, The Netherlands.

[f] Evonik Industries AG, Hanau, Germany.

[g] Sigma–Aldrich, USA.

[h] Vitamin/mineral premix provided (kg^{-1} diet): α- tocopherol acetate, 100 IU; sodium menadione bisulphate, 10 mg; retinyl acetate, 3000 IU; cholecalciferol, 2400 IU; thiamin, 10 mg; riboflavin, 10 mg; pyridoxine, 10 mg; nicotinic acid, 20 mg; folic acid, 2 mg; ascorbyl phosphate,100 mg; inositol, 400 mg; biotin, 0.2 mg; pantothenic acid, 40 mg; cyanocobalamin, 0.015 mg; choline chloride, 2000 mg; anti-oxidant BHT (E300-321), 100 mg; calcium propionate, 1000 mg; Fe (as $FeSO_4.7H_2O$), 50 mg; Zn (as $ZnSO_4.7H_2O$), 30 mg; Co (as $CoSO_4.7H_2O$), 0·1 mg; Cu (as $CuSO_4.5H_2O$), 10 mg; Se (as Na_2SeO_3), 0.5 mg; Mn (as $MnSO_4.4H_2O$), 20 mg; Mg (as $MgSO_4.7H_2O$), 500 mg; Cr (as $CrCl_3.6H_2O$), 1 mg; I (as $CaIO_3.6H_2O$), 2 mg.

[i] Calculated non-starch polysaccharides=1000- (crude protein+ crude lipid+ starch+ ash).

Table 2 Experimental design to evaluate digestive function in rainbow trout (*Oncorhynchus mykiss*) subjected to change in diet and/or environment

Treatment	Period 1		Period 2	Abbreviation
1	FM at Normoxia[1]	→	FM at Hypoxia[2]	FMNO→FMHY
2	FM at Normoxia	→	SBM at Hypoxia	FMNO→SBMHY
3	FM at Normoxia	→	SBM at Normoxia	FMNO→SBMNO
4	SBM at Normoxia	→	SBM at Hypoxia	SBMNO→SBMHY

FM, fishmeal; SBM, soybean meal.

[1] Water DO level was above 8 mg L^{-1} in the outlet (>78% saturation).

[2] Water DO level was below 6 mg L^{-1} in the outlet (< 55% saturation).

Table 3 Apparent digestibility coefficients (ADC %) of nutrients and energy of rainbow trout (*Oncorhynchus mykiss*) subjected to change in diet and/or environment [1]

Treatments	FMNO → FMHY	FMNO→ SBMHY	FMNO→ SBMNO	SBMNO→ SBMHY	Pooled SEM	*P*-value
ADC Dry matter (%)						
Period 1[2,3]	72.3	72.1	72.0	79.2	2.5	0.079
Period 2						
Day 7	74.6^{B,c}	82.6$^{A, a}$	81.7$^{AB, a}$	80.3$^{B, b}$	2.3	<.0001
Day 14	75.5^{B,c}	81.7$^{B, a}$	81.1$^{AB, ab}$	79.7$^{B, b}$	0.8	<.0001
Day 21	75.9^{B,b}	80.6^{C,a}	80.7^{B,a}	80.7^{AB,a}	0.7	0.030
Day 42	78.0^{A,b}	81.9^{AB,a}	82.8^{A,a}	82.1^{A,a}	0.5	0.007
ADC Crude protein (%)						
Period 1	92.9^{b}	92.7^{b}	92.2^{b}	94.3^{a}	0.6	0.003
Period 2						
Day 7	94.3^{b}	96.2^{a}	95.0^{b}	95.9^{a}	0.4	0.0002
Day 14	94.4^{b}	95.9^{a}	94.8^{ab}	95.7^{a}	0.5	0.007
Day 21	94.4^{c}	95.7^{a}	94.6^{bc}	95.5^{ab}	0.5	0.009
Day 42	94.3^{b}	95.8^{a}	95.1^{ab}	95.5^{a}	0.4	0.002
ADC Ash (%)						
Period 1	51.2^{b}	50.9^{b}	50.5^{b}	57.8^{a}	0.9	0.002
Period 2						
Day 7	52.1^{B,b}	57.8^{B,a}	56.6^{a}	59.0^{a}	1.1	0.020
Day 14	55.8^{AB}	58.1^{B}	57.3	59.1	1.5	0.180
Day 21	56.1^{AB}	57.9^{B}	57.4	58.8	1.5	0.170
Day 42	57.9^{A}	60.4^{A}	58.6	60.2	1.3	0.059
ADC GE (%)[4]						
Period 1	80.5^{b}	80.0^{b}	80.2^{b}	83.4^{a}	0.7	0.001
Period 2						
Day 42	84.2^{b}	84.3^{b}	86.2^{a}	84.7^{ab}	0.6	0.010
ADC starch (%)						
Period 1	89.4	89.6	90.0	89.2	1.3	0.420
ADC lipid (%)						
Period 1	93.7^{a}	93.5^{a}	94.8^{a}	89.0^{b}	1.2	0.001

[1] Values represent the means (*n*=3) with pooled SEM. Means in a row with different lower case letters indicate significant difference among treatments within a row and means in each column with different capital letters indicate significant difference over time during the period 2 within a treatment ($P < 0.05$). Data from ADC of energy, starch and lipid was available only for period 1 and end of period 2 (day 22-42). ADC of starch and lipid for the end of period 2 (day 22-42) are presented in Fig. 6.

[2] Fish were fed either fish meal (FM) or soybean meal (SBM) for 4 weeks during period 1.

[3] A Kruskal-Wallis one-way ANOVA was used for ADC of dry matter in period 1.

[4] Mean of gross energy (GE) digestibility coefficient includes the effect of cellulose inclusion as an inert ingredient.

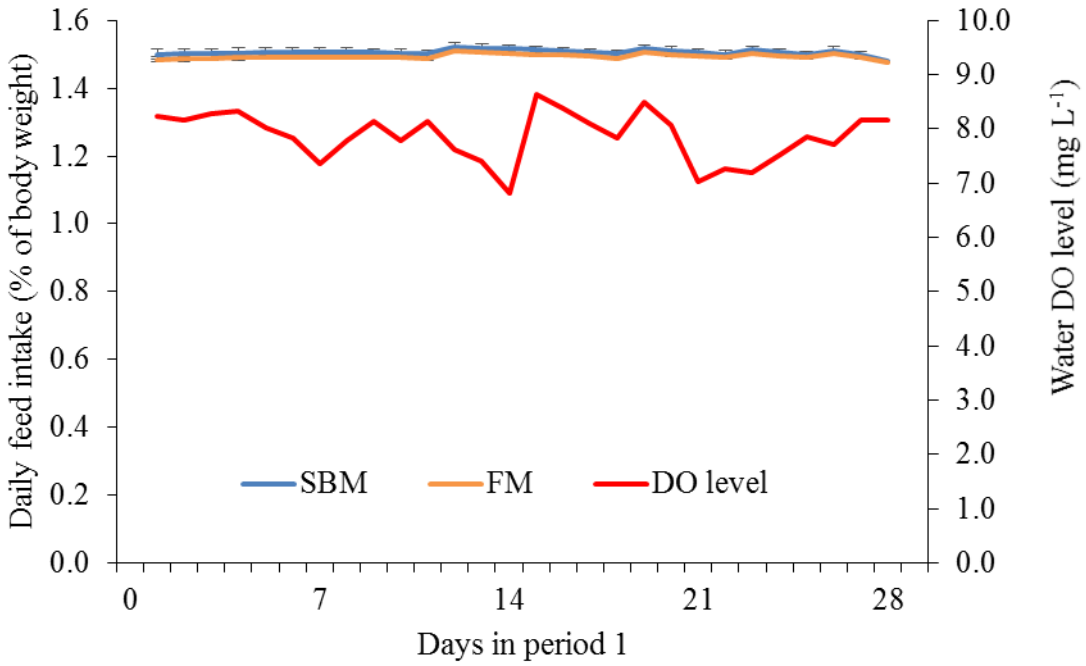
1.6
1.4
1.2
1.0
0.8
0.6
0.4
0.2
0.0
Daily feed intake (% of body weight)
10.0
9.0
8.0
7.0
6.0
5.0
4.0
3.0
2.0
1.0
0.0
Water DO level (mg L-1)
SBM
FM
DO level
0
7
14
21
28
Days in period 1

Fig. 1

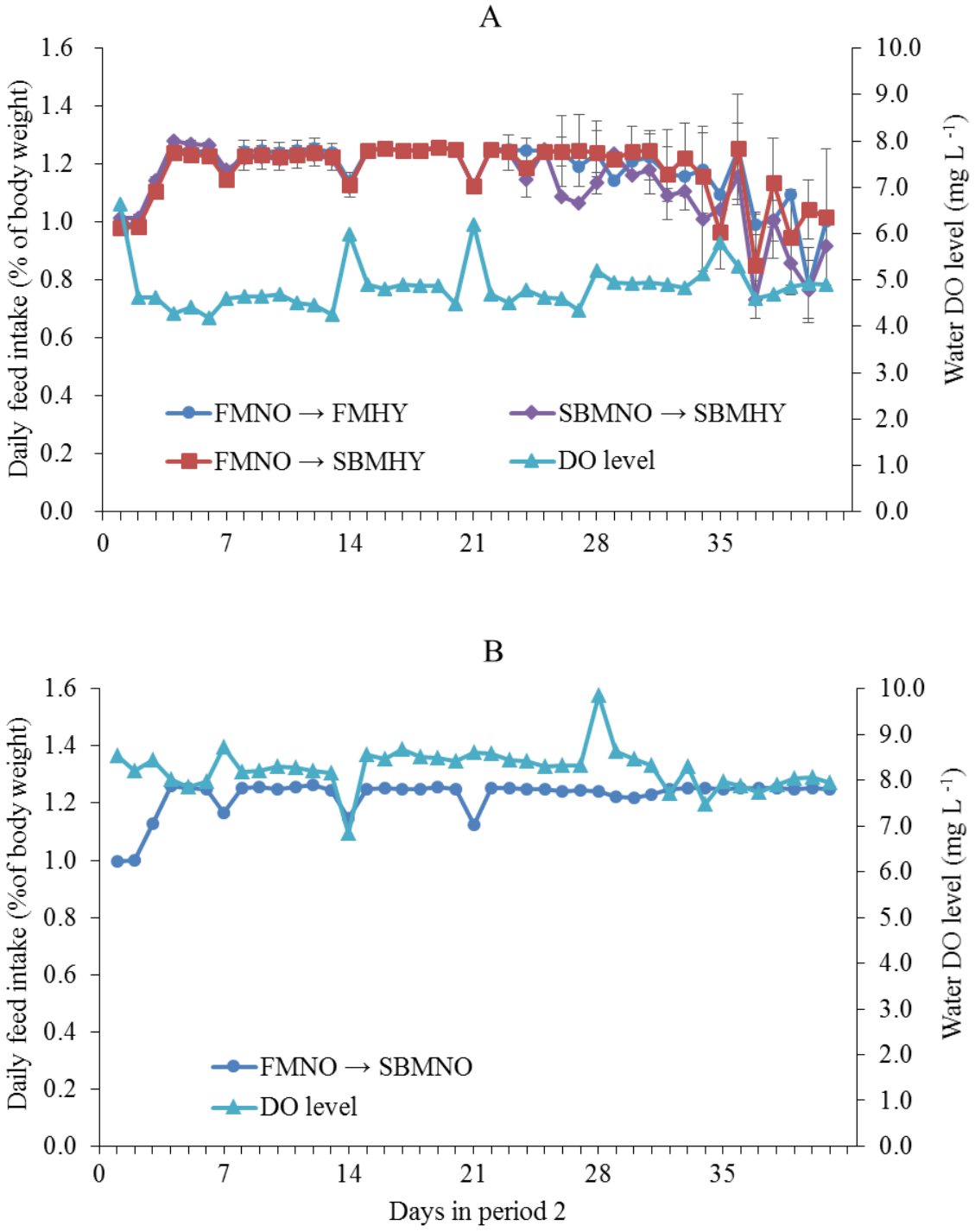
A
Daily feed intake (% of body weight)
Water DO level (mg L -1)
FMNO → FMHY
SBMNO → SBMHY
FMNO → SBMHY
DO level
B
Daily feed intake (%of body weight)
Water DO level (mg L -1)
FMNO → SBMNO
DO level
Days in period 2

Fig. 2

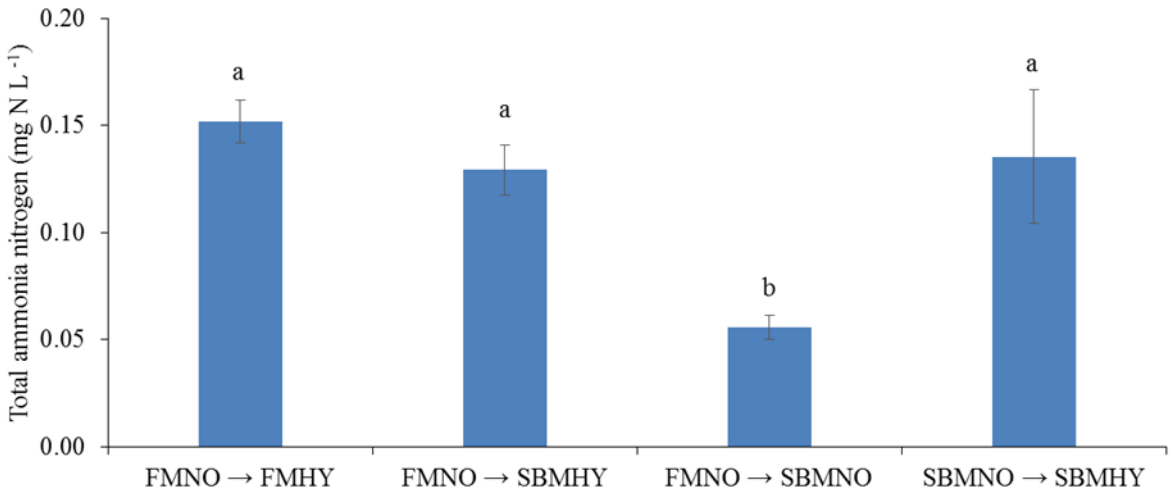
Total ammonia nitrogen (mg N L -1)
0.20
0.15
0.10
0.05
0.00
a
a
b
a
FMNO → FMHY
FMNO → SBMHY
FMNO → SBMNO
SBMNO → SBMHY

Fig. 3

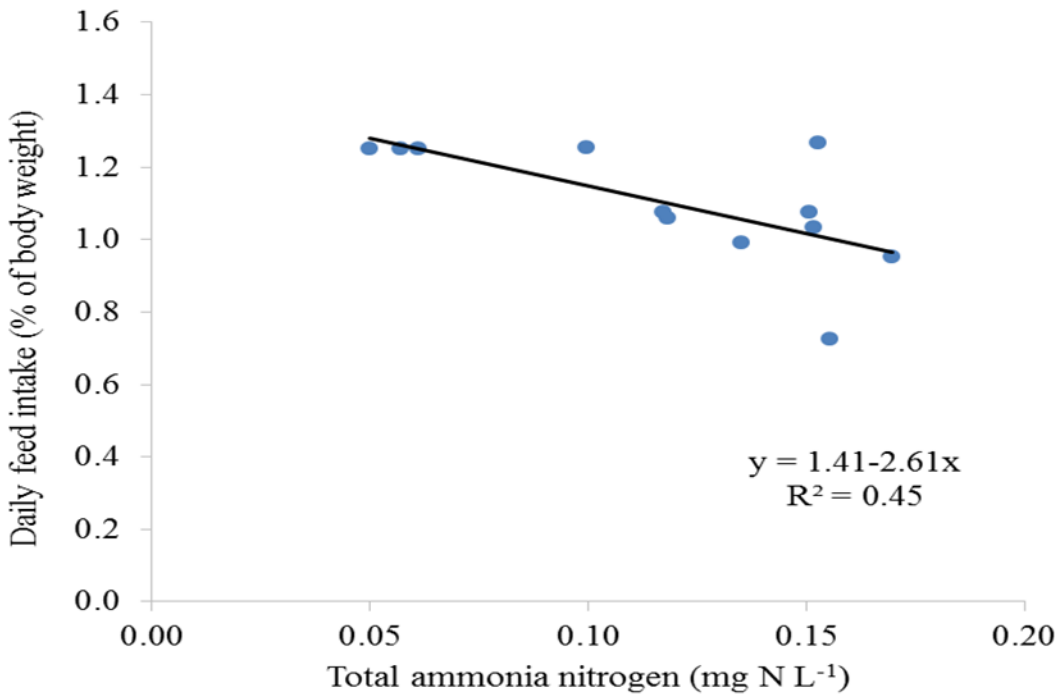
1.6
1.4
1.2
1.0
0.8
0.6
0.4
0.2
0.0
Daily feed intake (% of body weight)
y = 1.41-2.61x
R² = 0.45
0.00
0.05
0.10
0.15
0.20
Total ammonia nitrogen (mg N L-1)

Fig. 4

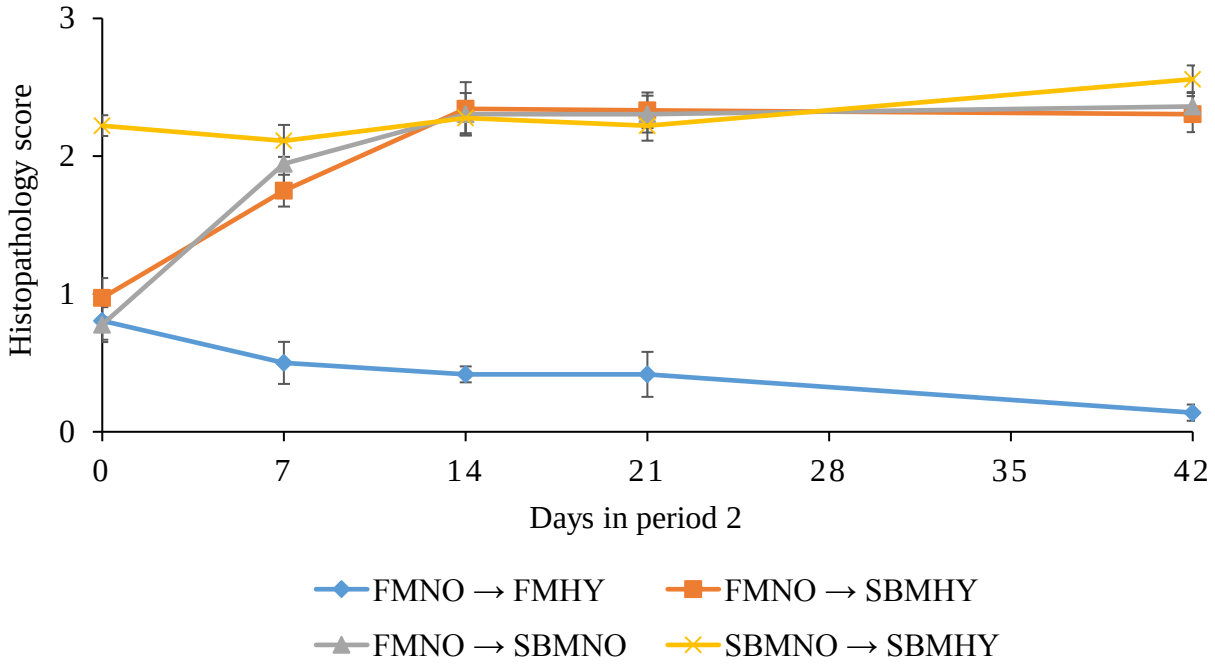
3
2
1
0
Histopathology score
0
7
14
21
28
35
42
Days in period 2
FMNO → FMHY
FMNO → SBMHY
FMNO → SBMNO
SBMNO → SBMHY

Fig. 5

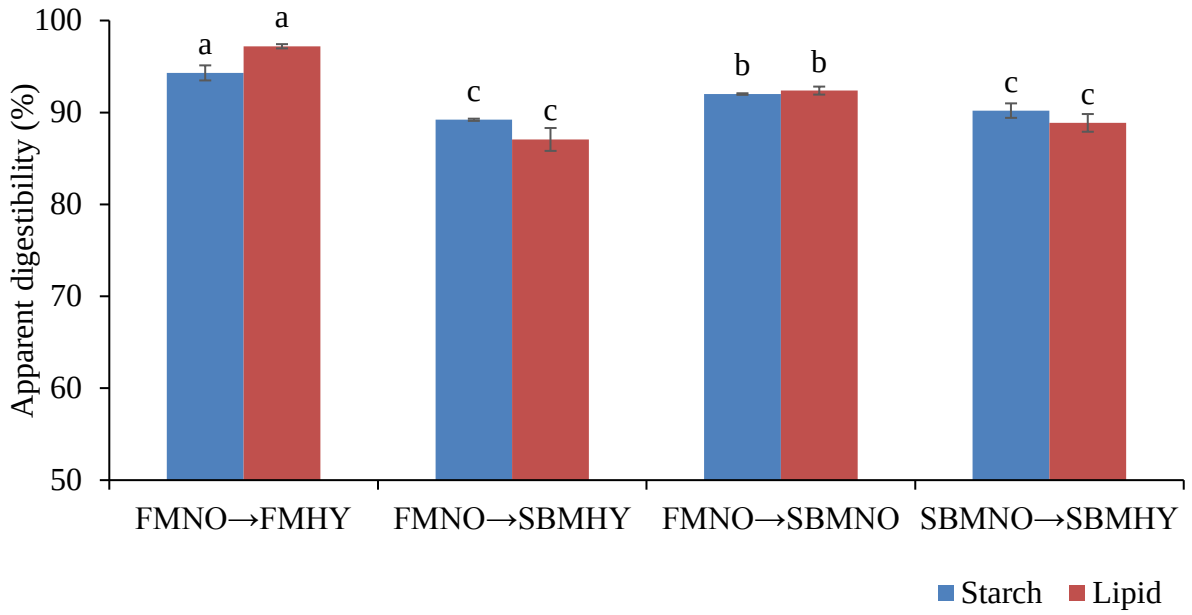
100
90
80
70
60
50
Apparent digestibility (%)
a
a
c
c
b
b
c
c
FMNO→FMHY
FMNO→SBMHY
FMNO→SBMNO
SBMNO→SBMHY
Starch
Lipid

Fig. 6

III

Granulomatous enteritis in rainbow trout (*Oncorhynchus mykiss*) challenged with soybean meal regardless of water dissolved oxygen level as an environmental challenge

Mosberian-Tanha, Peyman[1]; Landsverk, Thor[2]; Press, Charles McLean[2]; Mydland, Liv Torunn[1]; Schrama, Johan W[3]; Øverland, Margareth[*1]

[1]*Department of Animal and Aquacultural Sciences, Norwegian University of Life Sciences, Aas, Norway*

[2]*Department of Basic Sciences and Aquatic Medicine, Norwegian University of Life Sciences, Oslo, Norway*

[3]*Aquaculture and Fisheries Group, Wageningen Institute of Animal Sciences, Wageningen, the Netherlands*

* Correspondence: Margareth Øverland, Norwegian University of Life Sciences, NO-1432 Ås, Norway, Email: margareth.overland@nmbu.no

Running title:

Soybean meal-associated granulomatous enteritis

Key words: Enteritis, foamy macrophages, granulomatous enteritis, hypoxia, rainbow trout, soybean meal.

Abstract

Morphological changes associated with soybean meal-induced enteritis (SBMIE) in distal intestine (DI) of rainbow trout (*Oncorhynchus mykiss*) fed soybean meal (SBM)-based diet and kept at normoxia or hypoxia created by optimal and low water flow rate, respectively, was investigated. Histopathologic evaluation revealed additional pathological features to what is commonly known about SBMIE, thus these features were also investigated. Histology and immunohistochemistry using antibodies against cytokeratin and proliferating cell nuclear antigen (PCNA) were performed. The additional pathological features included vacuolar degeneration (VD) of epithelial cells mainly at the base of the mucosal folds, necrosis, shedding of necrotic cells, increased proliferation of subepithelial fibroblasts and granulomatous inflammation containing enlarged macrophages and multi-nucleated giant cells. SBMIE was also associated with increased reactivity to PCNA. Ziehl-Neelsen staining did not reveal acid-fast bacteria in enlarged macrophages, however, these cells contained acid and neutral mucins and occasionally cytokeratin-positive material, likely of epithelial origin. Hypoxia did not affect development or degree of morphological changes in DI including the additional pathological changes. These results suggest that SBM-based diet was associated with a variant form of enteritis in DI of rainbow trout including granulomatous inflammation and vacuolar degeneration.

Introduction

The inclusion of soybean meal (SBM) in salmonid feed is known to adversely affect intestinal homeostasis by development of a chronic inflammation referred to as soybean meal-induced enteritis (SBMIE) (Baeverfjord & Krogdahl 1996). SBMIE is a condition which has been characterized by many publications as increased leukocyte accumulation in the subepithelial tissues, atrophy of the intestinal folds, increased number of goblet cells and changes in the morphology of the epithelial cells such as: reduced supranuclear vacuolisation (SNV), reduced height of the cells and increased cytoplasmic basophilia (van den Ingh, Krogdahl, Olli, Hendriks & Koninkx 1991; Baeverfjord & Krogdahl 1996; Bakke-McKellep, Frøystad, Lilleeng, Dapra, Refstie, Krogdahl & Landsverk 2007b; Urán, Schrama, Rombout, Taverne-Thiele, Obach, Koppe & Verreth 2009). SBMIE shares some morphological and immunological features with human models of intestinal inflammation typically inflammatory bowel disease (IBD) and celiac disease (Hisamatsu, Kanai, Mikami, Yoneno, Matsuoka & Hibi 2013; Geboes, Joossens, Prantera & Rutgeerts 2003; Dickson, Streutker & Chetty 2006). Leukocyte infiltration and proliferation into the lamina propria resulting in thickening of mucosa, villus atrophy and loss of crypts with changes in morphology of epithelial cells are typical signs of these forms of intestinal inflammation. The composition of cells infiltrating into the lamina propria differ to some extents among various types of enteritis. In addition to T cells which have been studied under SBMIE conditions in Atlantic salmon (Bakke-McKellep *et al.* 2007b; Lilleeng, Penn, Haugland, Xu, Bakke & Krogdahl 2009), population of macrophages are also involved in mucosal immune response. Macrophages are one of the main agents of innate immune system and their function is crucial to maintain tissue homeostasis. As well as in mammals, activated macrophages in fish perform phagocytic activity and produce pro-inflammatory cytokines, reactive oxygen species and nitric oxide (Forlenza, Fink, Raes & Wiegertjes 2011).

Development of SBMIE is attributed to the presence of anti-nutritional factors (ANF), however, the exact aetiology of the disease is not yet fully understood. Inclusion of SBM at as low as 20% in Atlantic salmon (*Salmo salar* L.) has been shown to induce morphological changes in the distal intestine (DI) within the first week of consumption (Urán *et al.* 2009). Rainbow trout (*Oncorhynchus mykiss*) has been suggested to be more resistant to pathological effects of SBM (Refstie, Korsøen, Storebakken, Baeverfjord, Lein & Roem 2000), however, this condition is

also evident in this specie at sufficiently high SBM inclusion levels (Romarheim, Skrede, Penn, Mydland, Krogdahl & Storebakken 2008; Mosberian-Tanha, Øverland, Landsverk, Reveco, Schrama, Roem, Agger & Mydland 2016).

Adverse environmental conditions such as hypoxia may affect the fish health and welfare as reviewed elsewhere (Wu 2002). Pathological changes may occur in intestinal tissue in response to environmental factors. For example, impaired intestinal barrier function along with morphological changes in proximate and DI (Sundh, Kvamme, Fridell, Olsen, Ellis, Taranger & Sundell 2010) and elevated mucosal neutrophil infiltration (Niklasson, Sundh, Fridell, Taranger & Sundell 2011) has been previously reported to occur in response to chronic hypoxia in Atlantic salmon. It has also been shown that the effect of diet-induced intestinal morphological changes were aggravated in Nile tilapia (*Oreochromis niloticus*) kept under hypoxic conditions (Tran-Ngoc, Dinh, Nguyen, Roem, Schrama & Verreth 2016).

The interactive effect of dietary and environmental challenge (i.e. SBM-based diet and hypoxia) on the degree and progression of SBMIE in rainbow trout was shown previously by Mosberian-Tanha *et al.* (submitted) in which additional pathological features to what has been reported on SBMIE were observed. The granulomatous response reported previously (Mosberian-Tanha *et al.* submitted) is in several aspects different from the morphological changes commonly reported in response to SBM-based diet (Romarheim *et al.* 2008; Mosberian-Tanha *et al.* 2016). The findings necessitated a further detailed investigation of the intestinal pathology.

The present study was therefore designed to 1) investigate the interactive effect of dietary and environmental challenge (i.e. SBM-base diet and hypoxia) on morphological changes in DI in rainbow trout and 2) investigate if the uncommon pathological features were associated with hypoxia.

Materials and methods

Fish rearing and experimental procedure

The experiment was performed in accordance with the Dutch law on the use of experimental animals and approved by the ethical committee of Wageningen University (DEC: 2014006.a).

Details of diet preparation, chemical analysis and experimental design are described previously (Mosberian-Tanha *et al.* submitted). Briefly, at the start of the experiment 600 juvenile rainbow trout with mean initial body weight (± SE) of 74.1 ± 0.3g were randomly allocated among 12 tanks (50 fish per tank). Two isoenergetic and isonitrogenous diets were formulated (Table 1); one fishmeal-based control (FM) and one containing 40% soybean meal (SBM) as experimental diet. Each diet was assigned randomly to triplicate tanks (200 L capacity) according to the treatments and fed to the fish manually twice daily throughout the experiment at 9:00 and 16:00 hours for maximally 1 hour.

The experiment was split into two periods: In period 1 the fish were adapted to FM or SBM for 28 days and were kept at normoxia by setting the water flow rate at 7.5 L min^{-1} resulting in a mean dissolved oxygen (DO) level of above 8 mg L^{-1} in the outlet (>78% saturation). Period 2 was a challenge period of 42 days where the fish were subjected to either a dietary challenge and/or exposed to hypoxia by reducing the water flow rate from 7.5 L min^{-1} to 2.25 L min^{-1} resulting in a mean DO level of below 6 mg L^{-1} (< 55% saturation). The normoxic tanks, however, remained at the same water flow rate as used in period 1. If necessary, pure oxygen was injected into the inlet to maintain the intended DO level. The minimum DO level in the outlet, however, was maintained above 3.8 mg L^{-1} to avoid extreme reduction in feed intake and increased mortality. At the start of period 2, the feeding level was reduced from 1.5% to 1.25% of mean biomass of 12 tanks. Water DO level is the key limiting factor when the water flow rate is reduced, however, this treatment also leads to accumulation of metabolites or fish excretions such as ammonia. To simplify nomenclature, low water flow rate is termed hypoxia (HY) and optimal water flow rate is termed normoxia (NO). Throughout the experiment the fish was reared at photoperiod of 12 L: 12 D, water temperature of 14.0±0.5˚C, pH between 7.0 and 8.0, nitrate of < 250 mg N L^{-1} and nitrite of < 0.15 mg N L^{-1}. Total ammonium nitrogen (TAN) was measured as reported previously (Mosberian-Tanha *et al.* submitted) during week five of period 2. The average TAN level was 0.14 mg N L^{-1} under hypoxic conditions and 0.06 mg N L^{-1} at normoxia. The mean of DO level (mean ±SD) in the inlet was 10.3±0.3 mg L^{-1}.

The four treatments tested in this experiment are shown in Table 2. The design of the experiment has been described previously (Mosberian-Tanha *et al.* submitted).

Sampling

During the experiment DI was sampled at days 0, 7, 14, 21 and 42 of period 2. At each time point 3 fish per tank were randomly selected, individually weighed and anesthetised by 2-phenoxy ethanol (0.25 ml L^{-1}). The anesthetised fish were then sacrificed by a blow to the head before DI tissue sampling for morphological evaluation and immunohistochemistry. DI tissue samples were dissected and cut lengthways prior to fixation in neutral buffered formalin (4% formaldehyde) for 48 hours. DI tissue samples were dehydrated in 70% ethanol and embedded in paraffin before staining by hematoxylin and eosin (H&E) and Alcian blue-Periodic acid-Schiff (AB-PAS) following standard routines.

Histological evaluation

Blinded evaluation and scoring of the following morphological parameters was carried out on each DI tissue sample:

A. Subepithelial infiltration of leukocytes: increased accumulation of leukocytes in the subepithelial area down to stratum compactum.

B. Supranuclear vacuolisation (SNV) of epithelial cells: reduced vacuolisation of the epithelial cells.

C. Atrophy of intestinal folds.

D. Vacuolar degeneration (VD) of the epithelial cells: increased VD at the base of the intestinal folds.

E. The presence, if any, of granulomatous response and the degree of such response: increased proliferation of fibroblasts and aggregation of enlarged macrophages and multi-nucleated giant cells (MGC) along with lymphocytes in the subepithelial tissues.

Atrophy, SNV and mucosal leukocyte infiltration has been well documented in previous studies of SBMIE (Baeverfjord & Krogdahl 1996; Romarheim, Hetland, Skrede, Overland, Mydland & Landsverk 2013a). In H&E-stained sections, cells with VD and goblet cells often showed a similar morphological pattern and could be misinterpreted. Thus, AB-PAS staining was performed to detect acidic (blue) and neutral (red) mucins of goblet cells.

A score was given to each parameter which ranged from 0 (no morphological change) to 3 (severe changes) with increment of 1. Score of 1 was given to slight changes which are still assessed as normal morphology while score 2 was given to moderate changes. For evaluation of granulomatous response score of 1 was given to the tissue containing only a few number of enlarged macrophages and/or slight increase in the number of fibroblasts. Score 2 was given to the tissue expressing increased number of fibroblast, enlarged macrophages and a few MGCs. Score 3 was given to the tissue expressing large number of foamy macrophages and increased number of MGCs. According to this protocol, at least a score of 2 should be given to parameters A, B and C to confirm incidence of a classic SBMIE.

Immunohistochemistry

Paraffin sections were placed on glass slides and air-dried for 30 min at 58°C. The sections were then deparaffinised with xylene and rehydration. The sections were autoclaved in citrate buffer (pH 6.0) for 15 min at 121°C. Endogenous peroxidase was inhibited by incubation of the tissue sections for 10 min in 3 % H_2O_2 (hydrogen peroxide) diluted in methanol. To prevent nonspecific binding of antibodies, the sections were treated with goat serum containing 5% bovine serum albumin (BSA) in a Tris buffered saline (TBS) for 20 min at room temperature. The sections were then subjected to primary antibodies and incubated for 1 h at room temperature. For PCNA detection mouse monoclonal IgG2α-κ antibody (diluted 1:25000 in 1% BSA/TBS, M0879; Dako, Norge, Oslo, Norway) and for cytokeratin detection mouse monoclonal IgG1- κ antibody (pan, clone AE1/AE3, diluted 1:50 in 1% BSA/TBS, Zymed Laboratories) was used. Sections without primary antibody incubation served as negative controls. The incubation for the proxidase-laballed secondary antibody was performed with Labelled Polymer-HRP anti-mouse (Dako, Norge, Oslo, Norway) for 30 min. All incubations were performed in a humid chamber at room temperature. The peroxidase activity was developed with a 3-amino-9-ethyl carbazole kit (Dako, Norway) for 15 min. The sections were then counterstained with Mayer's hematoxylin for 20 seconds and mounted in Aquatex mounting medium (VWR International). The sections were washed 3 times, except for the treatment with goat serum, in PBS for 5 min between each step.

Calculations and statistics

Quantification of PCNA reactivity of each DI tissue sample was measured as described elsewhere (Romarheim, Øverland, Mydland, Skrede & Landsverk 2011). Statistical analyses were

performed using SAS 9.4 (SAS Institute 2012). All data were tested for normality and homogeneity by Kolmogorov-Smirnov and Bartlett tests. Data from morphological parameters violated the normal distribution assumption after log10-transformation; and thus these data were subjected to non-parametric Kruskal-Wallis test followed by multiple pairwise comparisons (Dwass-Steel-Critchlow-Fligner) if the test was significant. PCNA reactivity score in period 1 was subjected to one-way analysis of variance (ANOVA) in GLM procedure to test the effect of diet. The effect of treatment and sampling time on PCNA reactivity score in period 2 was analysed using a two-way ANOVA in GLM procedure. Least square means comparison was used to determine which groups differed significantly in PCNA reactivity from each other. Differences were declared statistically significant if $P < 0.05$.

Results

Histopathological evaluation of the distal intestine

Histopathological examination of the tissue sections revealed presence of SBMIE in fish fed SBM-based diet (Fig. 1). Under SBMIE conditions the intestinal folds showed various degrees of atrophy. Epithelial changes were often pronounced with reduced SNV of epithelial cells. In most individuals epithelial change also included VD often progressing to evident necrosis recognized by shrinking, condensation of the chromatin and fragmentation of nucleus. Acid and neutral mucins in goblet cells were readily identified with AB-PAS staining allowing distinction between goblet cells and cells with VD (Fig. 2). The necrotic epithelial cells were extruded to the intestinal lumen resulting in denudation of the lamina propria. Apparent fusion of adjacent intestinal folds in some cases resulted in the formation of cysts filled with epithelial debris (Fig. 3). These changes were predominantly found at the base of the folds. Flattened epithelial cells covering or partly covering the lamina propria and regenerative reaction in the remaining epithelial cells was interpreted as an effort for epithelial restitution (Fig. 4). Irregular shape of the epithelial cells and their nuclei in the vicinity of these areas and the site of fusion of the intestinal folds sometimes justified the use of the term “dysplastic” changes (Fig .5). Based on our evaluation protocol, total number of 113 fish (fed SBM regardless of their environment) were diagnosed with SBMIE during the entire experimental period. Of these, 12 fish (≈10%) during the last three weeks of period 2, showed dysplastic changes in epithelium.

Granulomatous response in different degrees was evident in the lamina propria (Fig. 6). Granulomatous response included prominent macrophage aggregates. Macrophages were often enlarged and sometimes finely vacuolated allowing the use of term “foamy macrophages” (Fig. 6). The foamy macrophages were positive for acid (blue) mucin and fewer were positive for neutral (red) mucin (Fig. 7). In addition to macrophages, infiltration of lymphocytes, eosinophilic granular cells, neutrophils and proliferation of fibroblasts were evident in the lamina propria. In individuals with marked granulomatous response, prominent presence of MGCs was also evident which, sometimes, were detected within the cysts. Ziehl–Neelsen stains were negative for acid-fast bacilli in selected sections with granulomatous response (Fig. 8).

The mean scores of morphological changes are shown in Fig. 9. These changes were characterised by reduced apical SNV, reduced height of simple and complex intestinal folds (partial atrophy), and increased number of leukocytes (e.g. lymphocytes, granulocytes and eosinophilic granular cells) in the lamina propria, the degree of VD at the base of the folds and the degree of granulomatous response. Atrophy, SNV of epithelial cells and mucosal leukocyte infiltration have been evaluated in many publications as morphological parameters associated with SBMIE (Mosberian-Tanha *et al.* 2016; Baeverfjord & Krogdahl 1996; Romarheim *et al.* 2013a). Thus these parameters are referred to as classic parameters/features of SBMIE in this paper. There was no adverse effect of hypoxia on morphological parameters in fish fed FM throughout the experiment, but exposed to hypoxia during period 2 (FMNO→FMHY). Fish fed the SBM diet throughout the experiment (SBMNO→SBMHY), developed SBMIE in the DI during period 1 and scored highest on all morphological parameters compared to fish fed the FM diet ($P<0.05$). During period 2 where this group were exposed to hypoxia, no significant change in the degree of morphological changes was observed overtime, however, granulomatous response tended to reduce at day 14 ($P=0.08$). The pattern of change in all morphological parameters was similar in the fish subjected to dietary change from FM to SBM under normoxia and hypoxia (FMNO→SBMHY and FMNO→SBMNO) during period 2. All SBM-fed fish regardless of the environment (i.e. hypoxia or normoxia), reached the same degree of change in three of the classic parameters (A, B and C) by day 7 and in VD and granulomatous response by day 14 and 21, respectively (Fig. 9).

Immunohistochemistry

Fish on a steady state SBM-based diet (SBMNO→SBMHY) showed higher degree of PCNA reactivity during period 1 than the groups fed FM-based diet ($P<0.0001$) and the degree of PCNA reactivity in this group remained unchanged throughout period 2. In period 2, fish fed FM-based diet but exposed to hypoxia (FMNO→FMHY) generally showed lowest degree of PCNA reactivity in the epithelium compared to other treatments (Fig. 10). The fish subjected to change from FM- to SBM-based diets under normoxia (FMNO→SBMNO) and hypoxia (FMNO→SBMHY) in period 2, showed their highest degree of PCNA reactivity at day 7 and 21 respectively, reaching the same degree as to that of the fish fed SBM throughout the experiment and exposed to hypoxia in period 2 (SBMNO-SBMHY). The degree of PCNA reactivity from day 21 onwards was not significantly different among all the fish fed SBM during period 2, regardless of their environment.

Following cytokeratin immunostaining, the epithelial cells were localised and the epithelial origin of extruded cells into the lumen was confirmed (Fig. 11). Cytokeratin reactivity was sometimes observed also within cysts (Fig. 12).

4. Discussion

The objective of the present study was to investigate if exposure to hypoxic conditions as an environmental challenge aggravates the effect of SBM on morphological changes associated with SBMIE in rainbow trout over time. Increase in morphological changes within the first week after SBM feeding is in agreement with the previous study in Atlantic salmon (Urán *et al.* 2009). In contrary to a previous study in rainbow trout (Romarheim *et al.* 2008), in the current study most of the fish fed SBM, regardless of their environment showed significant increase in change of all classic parameters of SBMIE within seven days of dietary challenge. Hypoxia did not affect significantly the degree of morphological changes in DI of SBM-fed fish. It is possible that the severe changes induced by SBM-based diet in this study concealed any additional effect of hypoxia. However, there was no adverse effect of hypoxia on morphology of DI in the fish fed FM-based diet. This may imply that hypoxia alone in this study could not induce morphological

changes in rainbow trout. This is in contrary to previous study in Atlantic salmon exposed to hypoxia (50% DO saturation) reporting atrophy of DI mucosal folds (Sundh *et al.* 2010) and infiltration of neutrophils into the mucosa of proximal intestine (Niklasson *et al.* 2011). The possible explanation is that rainbow trout may be more resistant to environmental challenges such as hypoxia than Atlantic salmon. The lack of adverse effect from hypoxia was observed for all parameters including granulomatous response and VD of epithelial cells.

This study presents a different feature of a diet-induced enteritis in association with dietary SBM. T cell reactivity has shown to be a key player in the pathogenesis of SBMIE in Atlantic salmon (Bakke-McKellep *et al.* 2007b; Lilleeng *et al.* 2009), however, in the current study pronounced presence of macrophages forming MGCs were also evident under SBMIE condition in many individuals. As a result this variant pathological feature was characterised as granulomatous enteritis. High inclusion of SBM and the lack of hypoxia effect on development of this form of enteritis led to the hypothesis that the pathological condition was associated with SBM feeding. The possible contribution from viral or bacterial factors such as mycobacterial infection was considered. The assumption was that the epithelial changes resulted in interruption of the intestinal mucosal barrier allowing the luminal contents including various types of microorganisms to directly interact with immune cells in subepithelial tissues. Absence of acid-fast organisms in tissue sections, however, ruled out presence of mycobacteria. However, it cannot be ruled out that other environmental factors, which could not be evaluated in this experiment, may have contributed to the manifestation. One such factor is water temperature. In a previous experiment on rainbow trout kept at average 9 ºC (Mosberian-Tanha *et al.* 2016) inclusion of 37.5% of SBM resulted in only classic morphological changes commonly reported for SBMIE. However, in the current experiment, apart from hypoxia, water temperature was another major environmental difference. Rainbow trout in this study was kept at relatively high temperature of 14ºC. The possible suggestion is that higher temperature used in this experiment may have been at least a contributing factor in the manifestation. Sealey, Barrows, Smith, Overturf & LaPatra (2009) reported epithelial "cystic absorptive vacuoles", fusion of intestinal folds, and change in morphology of epithelial cell nuclei in rainbow trout fed 43% SBM at 14.8 ºC temperature. Burrells, Williams, Southgate & Crampton (1999) observed increased vacuolisation of epithelial cells and extrusion of mucosal material into the intestinal lumen in rainbow trout (of 5 grams body weight) fed 80-89% SBM at 14 ºC compared to the fish fed lower

doses of SBM. Increased immune cell infiltration, however, was the only subepithelial observation made and reported by the authors. Moreover, the degree of SBMIE was found to increase at 12 ºC than that at 8 ºC in Atlantic salmon fed 20% SBM, however, without change in the form of inflammatory and tissue response (Uran, Schrama, Rombout, Obach, Jensen, Koppe & Verreth 2008). None of the above publications reported or observed granulomatous enteritis. We postulate that the pathological effect of SBM on DI may be different at higher temperatures (at least in rainbow trout) resulting in variant pathological features such as granulomatous response. Temperature may also affect the function of immune system which has a key role in the process of inflammation. In sockeye salmon (*Oncorhynchus nerka*), change in immune response pattern and higher dependency on specific immune function has been shown to occur at higher temperatures (Alcorn, Murray & Pascho 2002). The design of the current experiment, however, does not allow testing the effect of temperature.

Granulomatous enteritis involves a cellular response which may occur in association with chronic inflammation and is described by differentiated macrophages (epithelioid cells) which sometimes can be transformed into MGCs (Williams & Williams 1983). Granulomatous inflammation may occur in relation to various conditions such as tuberculosis, neoplastic diseases and toxins (Williams & Williams 1983). Incidence of granulomatous inflammation has been reported also in fish subjected to vaccination through injection or in fish with mycobacteriosis (Koppang, Haugarvoll, Hordvik, Aune & Poppe 2005; Novotny, Halouzka, Matlova, Vavra, Bartosova, Slany & Pavlik 2010). To our knowledge, there are no reports on development of granulomatous inflammation in response to soy products in intestine of fish. It has been suggested that granulomatous lesion can occur in response to release of mucins into the subepithelial area in colitis model of inflammation (Surawicz, Haggitt, Husseman & McFarland 1994). Association of granulomatous response with a human model of intestinal inflammation, Crohn's disease, has also been reported previously (Lee, Maguire, Obeidat & Russell 1997). Foamy macrophages are a form of active macrophages which may contain various types of materials (Sagaert, Tousseyn, De Hertogh & Geboes 2012). These cells were present in tissue sections with granulomatous inflammation. In this study positivity of foamy macrophages for acidic and neutral mucins may imply that foamy macrophages engulfed mucins. Foamy macrophages were mostly positive for acidic (blue) mucin which has been suggested to be an indication of mucin phagocytosis and presence of "muciphages" which are reported to occur in response to tissue

injury (Sagaert *et al.* 2012). Positivity for neutral (red) mucin is an indication of a much broader array of disorders including pathogen and also mucin phagocytosis (Sagaert *et al.* 2012). These cells could be observed under various conditions such as tissue inflammation, regeneration and hyperplasia (Bejarano, Aranda-Michel & Fenoglio-Preiser 2000). Overall, these result may suggest that foamy macrophages resembled muciphages and contained mucins of endogenous origin. It has been shown that muciphages engulf debris of death cells after previous injury and are not necessarily formed in response to pathogens (Bejarano *et al.* 2000).

Under SBMIE conditions increased number of goblet cells has been reported (Urán *et al.* 2009), which may be confused with vacuoles of epithelial cells. In this study, however, AB-PAS staining allowed more accurate evaluation of this pathological feature in tissue samples. VD is a feature of reversible and non-lethal cell injury which occurs as a result of fluid accumulation in the cell or swelling of the endoplasmic reticulum. If cell injury is progressive, the cell will eventually become necrotic (Kumar, Abbas, Fausto & Aster 2010). Epithelial cells with VD were mainly observed at the mucosal fold bases where cysts were also formed. Fusion of intestinal folds containing cells with VD may have formed epithelial cysts, similar to the observations made previously in rainbow trout (Sealey *et al.* 2009). Less degree of maturation at base of the folds where proliferation occurs may in turn result in increased susceptibility of epithelial cells to various harmful agents. Cytokeratin reactivity within cysts further suggests epithelial cell debris accumulation in these features.

Histopathology score of VD and granulomatous response were significantly increased after 14 and 21 days respectively in period 2 which implies that these features required more time to develop than other morphological parameters (i.e. A, B and C). This may also imply that the classic SBMIE with serious consequences on epithelial integrity may have contributed to the development of these pathological features.

Increased epithelial cells proliferation as compensatory response to cell loss under SBMIE condition has been shown previously (Bakke-McKellep, Penn, Salas, Refstie, Sperstad, Landsverk, Ringø & Krogdahl 2007a; Romarheim, Landsverk, Mydland, Skrede & Øverland 2013b) and indicates an attempt to restore tissue homeostasis. Increased proliferation as indicated in this experiment by measurement of PCNA-reactive stretch, showed a similar pattern as classic morphological changes (parameters A, B and C) and highlights the cellular proliferation in

response to inflammation. Reduced SNV in the apical part of the intestinal folds under SBMIE could, at least partly, be a result of reduced maturity of the epithelium due to expanded proliferation zone. Hypoxia did not increase PCNA reactivity which implies that the tissue maintained homeostasis under this condition. The delayed increase in PCNA reactivity score in the fish challenged simultaneously to hypoxia and SBM-based diet may be an indication of a short term effect of hypoxia on cell proliferation.

Dysplastic changes (dysplasia) in areas expressing epithelial restitution and fusion of intestinal folds indicates disorder of cell proliferation in the tissue under SBMIE condition. The balance of cell death and proliferation is important to maintain tissue homeostasis. When the rate of cell proliferation exceeds that of cell death, the tissue may undergo abnormal growth with increased risk of tumorigenesis. Dysplasia is known to be associated with incomplete maturation process in new cells. Increased risk of abnormal growth of intestinal tissue towards neoplasm has been reported in human with inflammatory bowel disease (Triantafillidis, Nasioulas & Kosmidis 2009). Discrimination between regenerating epithelial cells due to inflammation and dysplastic cells could be challenging. With use of cell proliferating markers such as PCNA, some experiments have shown further expansion of proliferation zone in intestinal tissues with dysplasia (Kullmann, Fadaie, Gross, Knuchel, Bocker, Steinbach, Scholmerich & Ruschoff 1996).

Immunohistochemical detection of cytokeratin revealed epithelial origin of extruded epithelial cells explaining the cause of lamina propria denudation mainly at the tip of the intestinal folds. This indicates loss of epithelial cells and barrier damage and in turn can cause increased cell proliferation (as indicated by increased PCNA reactivity) and susceptibility of tissue to luminal contents. At the edge of denuded area, flattened epithelial cells were observed which may indicate a rapid compensatory response referred to as restitution. Restitution has been reported to occur following severe epithelial damage in small intestine of rats (Matovelo, Sund & Landsverk 1989) and aims to cover the denuded areas and provide protection. Severe extrusion of epithelial cells has been suggested as a disturbing factor to the epithelial barrier integrity leading to inflammation (Gudipaty & Rosenblatt 2016).

In conclusion, hypoxic conditions neither induced inflammation nor aggravated the degree of SBMIE in rainbow trout. Simultaneous exposure of SBM-based diet and hypoxia induced a

delayed increase in PCNA reactivity score. Further to the commonly reported pathological features of SBMIE, additional changes such as granulomatous response and vacuolar degeneration of epithelial cells were observed. These changes were associated with more pronounced macrophage reaction. There was no indication of hypoxia effect on development of these changes. The variant pathological features reported in this study could potentially reveal new aspects of the pathogenesis of SBMIE.

References

Alcorn, S.W., Murray, A.L. & Pascho, R.J. (2002) Effects of rearing temperature on immune functions in sockeye salmon (Oncorhynchus nerka). *Fish & Shellfish Immunology,* **12,** 303-334.

Baeverfjord, G. & Krogdahl, A. (1996) Development and regression of soybean meal induced enteritis in Atlantic salmon, *Salmo salar* L., distal intestine: a comparison with the intestines of fasted fish. *Journal of Fish Diseases,* **19,** 375-387.

Bakke-Mckellep, A., Penn, M., Salas, P., Refstie, S., Sperstad, S., Landsverk, T., Ringø, E. & Krogdahl, Å. (2007a) Effects of dietary soyabean meal, inulin and oxytetracycline on intestinal microbiota and epithelial cell stress, apoptosis and proliferation in the teleost Atlantic salmon (*Salmo salar* L.). *British Journal of Nutrition,* **97,** 699-713.

Bakke-Mckellep, A.M., Frøystad, M.K., Lilleeng, E., Dapra, F., Refstie, S., Krogdahl, Å. & Landsverk, T. (2007b) Response to soy: T-cell-like reactivity in the intestine of Atlantic salmon, *Salmo salar* L. *Journal of Fish Diseases,* **30,** 13-25.

Bejarano, P.A., Aranda-Michel, J. & Fenoglio-Preiser, C. (2000) Histochemical and immunohistochemical characterization of foamy histiocytes (muciphages and xanthelasma) of the rectum. *American Journal of Surgical Pathology,* **24,** 1009-1015.

Burrells, C., Williams, P.D., Southgate, P.J. & Crampton, V.O. (1999) Immunological, physiological and pathological responses of rainbow trout (Oncorhynchus mykiss) to increasing dietary concentrations of soybean proteins. *Veterinary Immunology and Immunopathology,* **72,** 277-288.

Dickson, B.C., Streutker, C.J. & Chetty, R. (2006) Coeliac disease: an update for pathologists. *Journal of Clinical Pathology,* **59,** 1008-1016.

Forlenza, M., Fink, I.R., Raes, G. & Wiegertjes, G.F. (2011) Heterogeneity of macrophage activation in fish. *Developmental & Comparative Immunology,* **35,** 1246-1255.

Geboes, K., Joossens, S., Prantera, C. & Rutgeerts, P. (2003) Indeterminate colitis in clinical practice. *Current Diagnostic Pathology,* **9,** 179-187.

Gudipaty, S.A. & Rosenblatt, J. (2016) Epithelial cell extrusion: Pathways and pathologies. *Seminars in Cell & Developmental Biology*.

Hisamatsu, T., Kanai, T., Mikami, Y., Yoneno, K., Matsuoka, K. & Hibi, T. (2013) Immune aspects of the pathogenesis of inflammatory bowel disease. *Pharmacology & Therapeutics,* **137,** 283-297.

Koppang, E.O., Haugarvoll, E., Hordvik, I., Aune, L. & Poppe, T.T. (2005) Vaccine-associated granulomatous inflammation and melanin accumulation in Atlantic salmon, Salmo salar L., white muscle. *Journal of Fish Diseases,* **28,** 13-22.

Kullmann, F., Fadaie, M., Gross, V., Knuchel, R., Bocker, T., Steinbach, P., Scholmerich, J. & Ruschoff, J. (1996) Expression of proliferating cell nuclear antigen (PCNA) and Ki-67 in dysplasia in inflammatory bowel disease. *European Journal of Gastroenterology and Hepatology,* **8,** 371-379.

Kumar, V., Abbas, A.K., Fausto, N. & Aster, J.C. (2010) Cellular responses to stress and toxic insults: adaptation, injury and death. In: *Robbins & Cotran Pathologic Basis of Disease* (ed. by A.K.A. (Ed. By V. Kumar, N. Fausto & J.C. Aster)), pp. 13-14. Saunders and Elsevier, Philadelphia, PA, USA.

Lee, F.D., Maguire, C., Obeidat, W. & Russell, R.I. (1997) Importance of cryptolytic lesions and pericryptal granulomas in inflammatory bowel disease. *Journal of Clinical Pathology,* **50,** 148-152.

Lilleeng, E., Penn, M., Haugland, O., Xu, C., Bakke, A. & Krogdahl, A. (2009) Decreased expression of TGF-beta, GILT and T-cell markers in the early stages of soybean enteropathy in Atlantic salmon (*Salmo salar* L.). *Fish & Shellfish Immunology,* **27,** 65-72.

Matovelo, J.A., Sund, R.B. & Landsverk, T. (1989) Morphological and functional recovery following exposure to deoxycholic acid. A study in the rat small intestine in vivo. *APMIS,* **97,** 798-810.

Mosberian-Tanha, P., Øverland, M., Landsverk, T., Reveco, F.E., Schrama, J.W., Roem, A.J., Agger, J.W. & Mydland, L.T. (2016) Bacterial translocation and *in vivo* assessment of intestinal barrier permeability in rainbow trout (*Oncorhynchus mykiss*) with and without soyabean meal-induced inflammation. *J. Nutr. Sci.,* **5,** e26 (10 pages).

Niklasson, L., Sundh, H., Fridell, F., Taranger, G.L. & Sundell, K. (2011) Disturbance of the intestinal mucosal immune system of farmed Atlantic salmon (*Salmo salar*), in response to long-term hypoxic conditions. *Fish & Shellfish Immunology,* **31,** 1072-1080.

Novotny, L., Halouzka, R., Matlova, L., Vavra, O., Bartosova, L., Slany, M. & Pavlik, I. (2010) Morphology and distribution of granulomatous inflammation in freshwater ornamental fish infected with mycobacteria. *Journal of Fish Diseases,* **33,** 947-955.

Refstie, S., Korsøen, Ø.J., Storebakken, T., Baeverfjord, G., Lein, I. & Roem, A.J. (2000) Differing nutritional responses to dietary soybean meal in rainbow trout (Oncorhynchus mykiss) and Atlantic salmon (Salmo salar). *Aquaculture,* **190,** 49-63.

Romarheim, O.H., Hetland, D.L., Skrede, A., Overland, M., Mydland, L.T. & Landsverk, T. (2013a) Prevention of soya-induced enteritis in Atlantic salmon (*Salmo salar*) by bacteria grown on natural gas is dose dependent and related to epithelial MHC II reactivity and CD8 alpha(+) intraepithelial lymphocytes. *British Journal of Nutrition,* **109,** 1062-1070.

Romarheim, O.H., Landsverk, T., Mydland, L.T., Skrede, A. & Øverland, M. (2013b) Cell wall fractions from Methylococcus capsulatus prevent soybean meal-induced enteritis in Atlantic salmon (*Salmo salar*). *Aquaculture,* **402–403,** 13-18.

Romarheim, O.H., Skrede, A., Penn, M., Mydland, L.T., Krogdahl, A. & Storebakken, T. (2008) Lipid digestibility, bile drainage and development of morphological intestinal changes in rainbow trout (*Oncorhynchus mykiss*) fed diets containing defatted soybean meal. *Aquaculture,* **274,** 329-338.

Romarheim, O.H., Øverland, M., Mydland, L.T., Skrede, A. & Landsverk, T. (2011) Bacteria Grown on Natural Gas Prevent Soybean Meal-Induced Enteritis in Atlantic Salmon. *Journal of Nutrition,* **141,** 124-130.

Sagaert, X., Tousseyn, T., De Hertogh, G. & Geboes, K. (2012) Macrophage-related diseases of the gut: a pathologist's perspective. *Virchows Archiv,* **460,** 555-567.

Sealey, W.M., Barrows, F.T., Smith, C.E., Overturf, K. & Lapatra, S.E. (2009) Soybean meal level and probiotics in first feeding fry diets alter the ability of rainbow trout Oncorhynchus mykiss to utilize high levels of soybean meal during grow-out. *Aquaculture,* **293,** 195-203.

Sundh, H., Kvamme, B.O., Fridell, F., Olsen, R.E., Ellis, T., Taranger, G.L. & Sundell, K. (2010) Intestinal barrier function of Atlantic salmon (*Salmo salar* L.) post smolts is reduced by common sea cage environments and suggested as a possible physiological welfare indicator. *BMC Physiology,* **10,** 22.

Surawicz, C.M., Haggitt, R.C., Husseman, M. & Mcfarland, L.V. (1994) Mucosal biopsy diagnosis of colitis: acute self-limited colitis and idiopathic inflammatory bowel disease. *Gastroenterology,* **107,** 755-763.

Tran-Ngoc, K.T., Dinh, N.T., Nguyen, T.H., Roem, A.J., Schrama, J.W. & Verreth, J.a.J. (2016) Interaction between dissolved oxygen concentration and diet composition on growth, digestibility and intestinal health of Nile tilapia (*Oreochromis niloticus*). *Aquaculture,* **462,** 101-108.

Triantafillidis, J.K., Nasioulas, G. & Kosmidis, P.A. (2009) Colorectal cancer and inflammatory bowel disease: epidemiology, risk factors, mechanisms of carcinogenesis and prevention strategies. *Anticancer Research,* **29,** 2727-2737.

Uran, P.A., Schrama, J.W., Rombout, J., Obach, A., Jensen, L., Koppe, W. & Verreth, J.a.J. (2008) Soybean meal-induced enteritis in Atlantic salmon (Salmo salar L.) at different temperatures. *Aquaculture Nutrition,* **14,** 324-330.

Urán, P.A., Schrama, J.W., Rombout, J.H.W.M., Taverne-Thiele, J.J., Obach, A., Koppe, W. & Verreth, J.a.J. (2009) Time-related changes of the intestinal morphology of Atlantic salmon, *Salmo salar* L., at two different soybean meal inclusion levels. *Journal of Fish Diseases,* **32,** 733-744.

Van Den Ingh, T.S.G.a.M., Krogdahl, Å., Olli, J.J., Hendriks, H.G.C.J.M. & Koninkx, J.G.J.F. (1991) Effects of soybean-containing diets on the proximal and distal intestine in Atlantic salmon (*Salmo salar*): a morphological study. *Aquaculture,* **94,** 297-305.

Williams, G.T. & Williams, W.J. (1983) Granulomatous inflammation--a review. *Journal of Clinical Pathology,* **36,** 723-733.

Wu, R.S.S. (2002) Hypoxia: from molecular responses to ecosystem responses. *Marine Pollution Bulletin,* **45,** 35-45.

Acknowledgements

This study was funded by AQUAEXCEL (Aquaculture Infrastructures for Excellence in European Fish Research) project no 0071/05/13/30/A and also supported by Foods of Norway, a Centre for Research- based Innovation (the Research Council of Norway; grant no. 237841/030).

Figure legends

Fig. 1. Morphology of the distal intestine in rainbow trout (*Oncorhynchus mykiss*) stained with hematoxylin and eosin (H&E) (bars = 200 μm). A) Normal distal intestinal (DI) tissue of rainbow trout fed fish meal. Epithelial cells are regular, high and finely vacuolated. B) DI tissue with soybean meal-induced enteritis after 42 days of feeding a diet containing 40% soybean meal. DI tissue shows atrophy of mucosal folds and heavy infiltration of leukocytes into the subepithelial mucosa. Epithelial cells have a denser cytoplasm and their height and degree of supranuclear vacuolisation is reduced. Cysts containing epithelial debris, are mainly seen at the base of the mucosal folds (arrows).

Fig. 2. Distal intestine of rainbow trout with soybean meal-induced enteritis stained with Alcian blue - Periodic acid Schiff (AB-PAS). Vacuolar degeneration of epithelial cells (black arrows) are identified and goblet cells containing acidic (blue) mucins are readily distinguished (blue arrows) (bar=50 μm).

Fig. 3. Immunohistochemistry using anti-cytokeratin antibody (AE1/AE3) on distal intestine of rainbow trout with soybean meal-induced enteritis. Epithelial cells have largely disappeared from the base of the mucosal folds and replaced by cysts (arrows) containing necrotic debris (bar= 100 μm).

Fig. 4. Epithelial restitution in distal intestine of rainbow trout with soybean meal-induced enteritis and immunostained with anti-cytokeratin antibody (AE1/AE3). Restitution is a tissue response aiming to cover the denuded area (DN) resulting from heavy loss of epithelial cells. In this process epithelial cells are flattened (F) and spread to cover the denuded area. LP: lamina propria; S: shedding of necrotic cells (bar=100 μm).

Fig. 5. Dysplastic changes in the epithelium of rainbow trout with soybean meal-induced enteritis (SBMIE). Dysplastic changes were observed in 10 % of individuals with SBMIE (sampled during the last three weeks of period 2) and characterised by the irregularity in nuclei of the epithelial cells. In this micrograph these changes are seen at the site of fusion of the intestinal folds (encircled). Tissue stained with hematoxylin and eosin (H&E) (bar=100 μm).

Fig. 6. Granulomatous enteritis in rainbow trout with distal intestinal inflammation induced by soybean meal. This phenomenon was characterised by the presence of multi-nucleated giant cells (black arrows), foamy macrophages (red arrow) and increased proliferation of fibroblasts in subepithelial tissue. Cysts (C) were also observed in association with granulomatous enteritis. Hematoxylin and eosin (H&E) (bar=50 μm).

Fig. 7. Foamy macrophages in rainbow trout with granulomatous enteritis were mostly positive for acidic (blue) mucins, however, a few were also positive for neutral (red) mucins. In this micrograph cysts (C) are seen which sometimes contained multi-nucleated giant cells (black arrow) (bar=50 μm).

Fig. 8. Distal intestinal tissue in rainbow trout with granulomatous enteritis found to be negative for Ziehl-Neelsen staining. A) Foamy macrophages and B) multi-nucleated giant cells (black arrow) did not contain acid-fast organisms. C: cyst (bar=50 μm).

Fig. 9. Morphological evaluation of distal intestine of rainbow trout fed fish meal or soybean meal and exposed to hypoxia or normoxia for 42 days. The changes in subepithelial infiltration of leukocytes (A), supranuclear vacuolisation of the epithelial cells (B), atrophy of intestinal folds (C), vacuolar degeneration of the epithelial cells at the base of the intestinal folds (D) and the subepithelial presence and degree of granulomatous response (E) are shown. Values are means

(n=9) ± standard errors represented by vertical bars. Fish was challenged with soybean meal and/or hypoxia during period 2. FM, fish meal; SBM, soybean meal; NO, normoxia; HY, hypoxia. Histopathological score of classic morphological parameters (A, B and C) in response to a soybean meal (SBM)-based diet was significantly increased at the end of period 1 (Day 0). The degree of morphological parameters remained unchanged throughout period 2 for the fish under steady-state SBM feeding. In rainbow trout subjected to change from fish meal (FM) - to SBM-based diet, regardless of water oxygen level, the score of the classic morphological parameters were significantly increased after 7 days of SBM feeding in period 2. After day 7, there was no further change in the degree of these morphological parameters. The significant change in vacuolar degeneration of epithelial cells and granulomatous response were observed after 14 and 21 days, respectively, in period 2 in fish subjected to change from FM to SBM. After day 21, there was no further change in the degree of classic and variant morphological features among SBM-fed groups regardless of their environment.

Fig. 10. Proliferating cell nuclear antigen (PCNA) reactivity score of epithelium in the distal intestine of rainbow trout fed fish meal or soybean meal-based diets and kept at normoxia or hypoxia for 42 days. FM, fish meal; SBM, soybean meal; NO, normoxia; HY, hypoxia. Values are means (n=9) ± standard errors represented by vertical bars. PCNA reactivity score was significantly increased in response to SBM-based diet by the end of period 1 (Day 0). The score remained unchanged during period 2 in the treatment group exposed to steady state dietary challenge (i.e. SBM). In the group subjected to FM throughout the experiment, the PCNA reactivity score was significantly reduced at day 42. Change from FM to SBM without change in water oxygen level increased the score significantly after 7 days of SBM feeding and remained as high as the score observed in the group under steady state SBM challenge. Change from FM-

to SBM-based diets and simultaneously a change from normoxia to hypoxia resulted in significant increase in PCNA reactivity score after 21 days in period 2. After day 21 there was no significant difference in PCNA reactivity score among all groups fed SBM-based diet, regardless of water oxygen levels.

Fig. 11. Extrusion of epithelial cells into the lumen of distal intestine of rainbow trout with soybean meal-induced enteritis. The epithelial origin of extruded material was confirmed by immunohistochemistry using antibody (AE1/AE3) directed against cytokeratins. NC: necrotic cells (bar =200 µm).

Fig. 12. Cytokeratin reactivity was occasionally found within cysts (red arrow) in distal intestine of rainbow trout with soybean meal-induced enteritis. This suggests accumulation of material of epithelial origin within these structures. Black arrow shows a multi-nucleated giant cell (bar =200 µm).

Table 1. Diet formulation and chemical composition of experimental diets fed to rainbow trout (*Oncorhynchus mykiss*) [1]

	FM	SBM
Ingredients (g kg^{-1})		
Fish meal	540.0	250.0
Soybean meal	-	400.0
Wheat flour	170.0	140.0
Rapeseed oil	100.0	120.9
Fish oil	40.0	40.0
Cellulose	143.4	30.0
Monocalcium phosphate	-	10.0
DL-methionine	-	2.5
Yttrium oxide	0.1	0.1
Vitamin/mineral premix	6.5	6.5
Proximate analysis		
Crude protein (g kg^{-1})	430.0	427.0
Crude fat (g kg^{-1})	206.0	220.0
Ash (g kg^{-1})	79.0	76.0
Gross energy (MJ kg^{-1})	23.0	23.2

FM, fishmeal; SBM, soybean meal

[1] Details of ingredients suppliers were previously reported (Mosberian-Tanha *et al.* submitted).

Table 2. Experimental design to evaluate morphological changes in the distal intestine of rainbow trout (*Oncorhynchus mykiss*) fed soybean meal and exposed to hypoxic conditions

Treatment	Period 1		Period 2	Abbreviation
1	FM at Normoxia	→	FM at Hypoxia	FMNO→FMHY
2	FM at Normoxia	→	SBM at Hypoxia	FMNO→SBMHY
3	FM at Normoxia	→	SBM at Normoxia	FMNO→SBMNO
4	SBM at Normoxia	→	SBM at Hypoxia	SBMNO→SBMHY

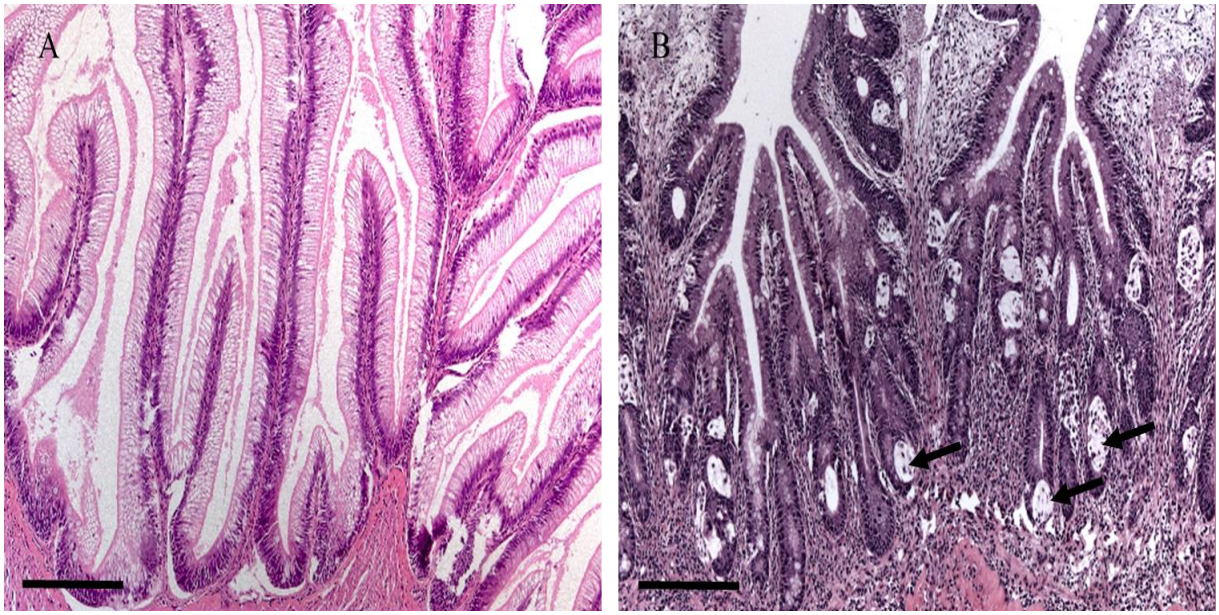

Fig. 1

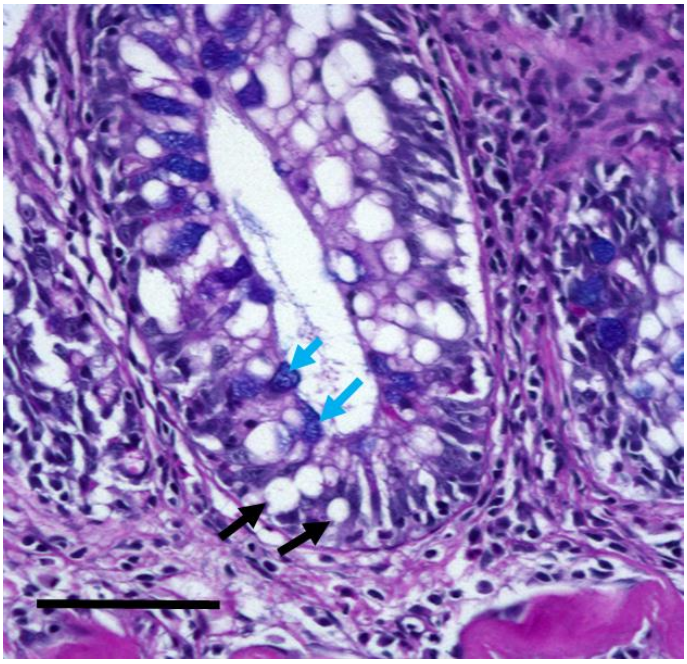

Fig. 2

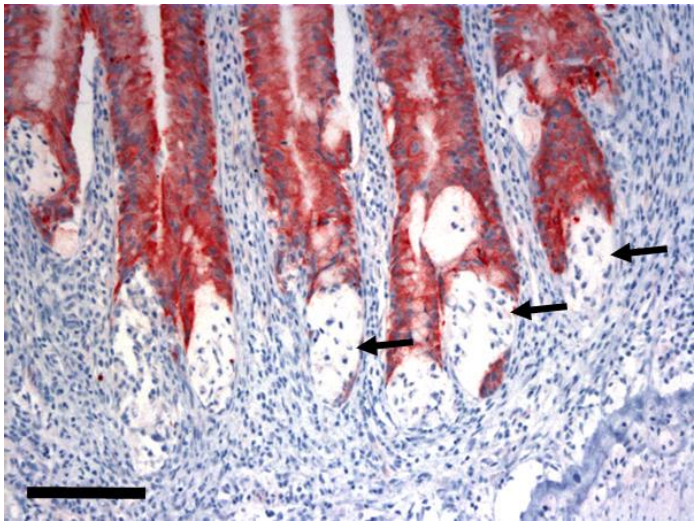

Fig. 3

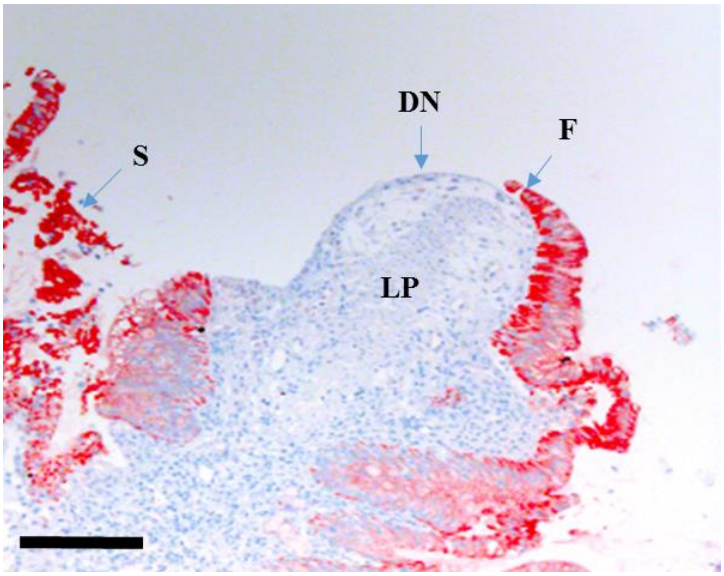

Fig. 4

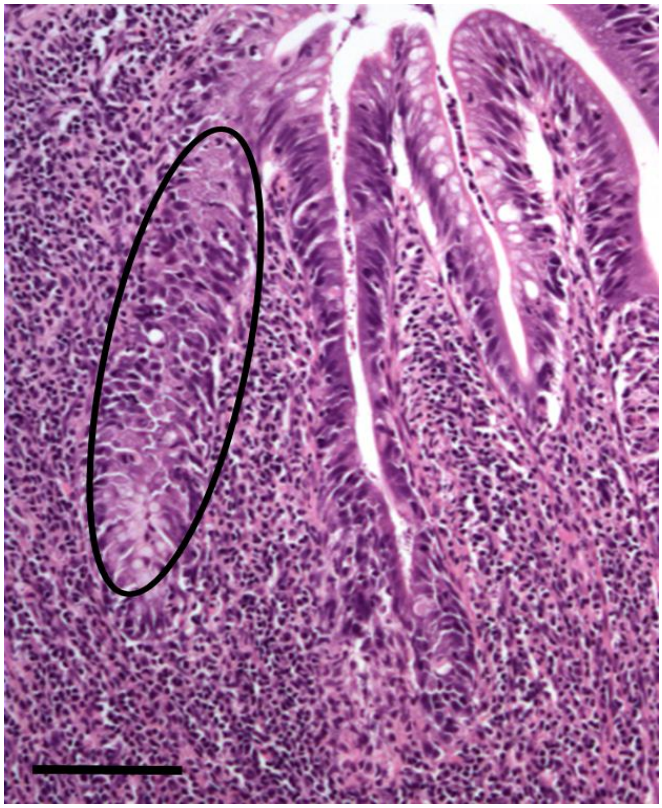

Fig. 5

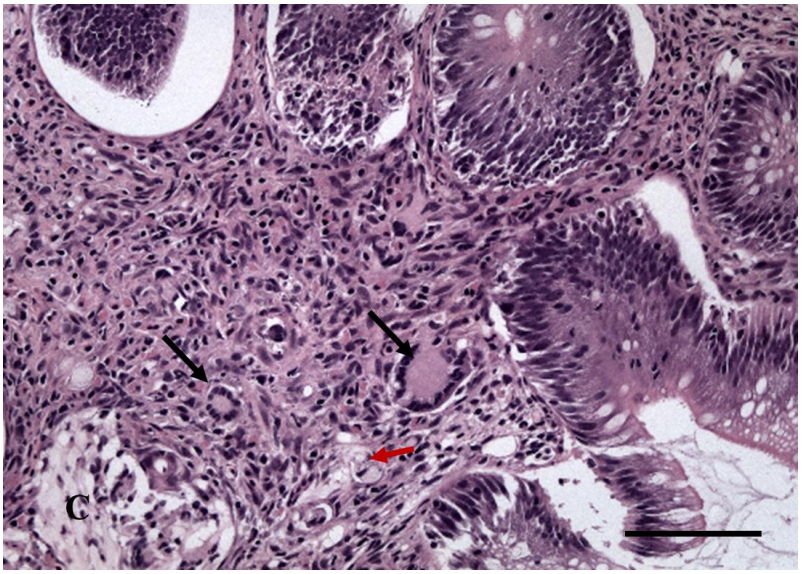

Fig. 6

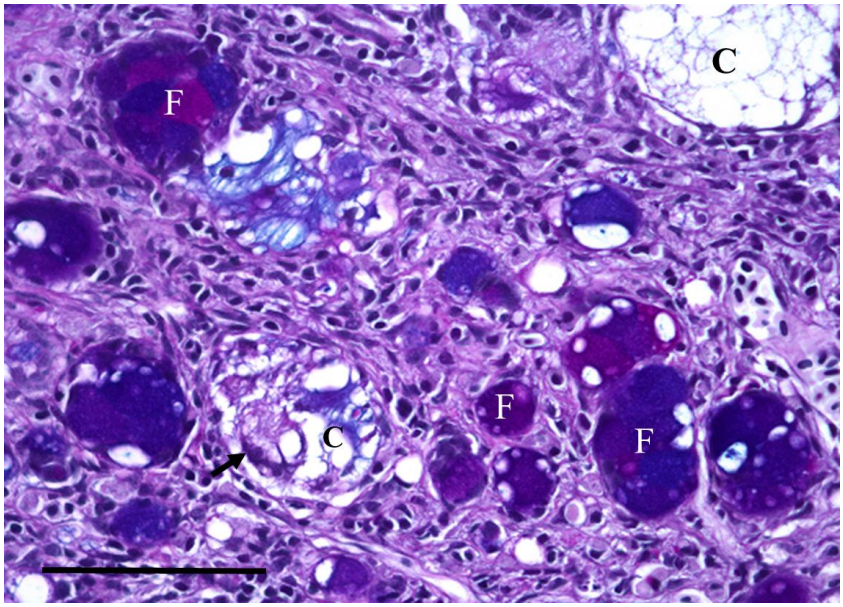

Fig. 7

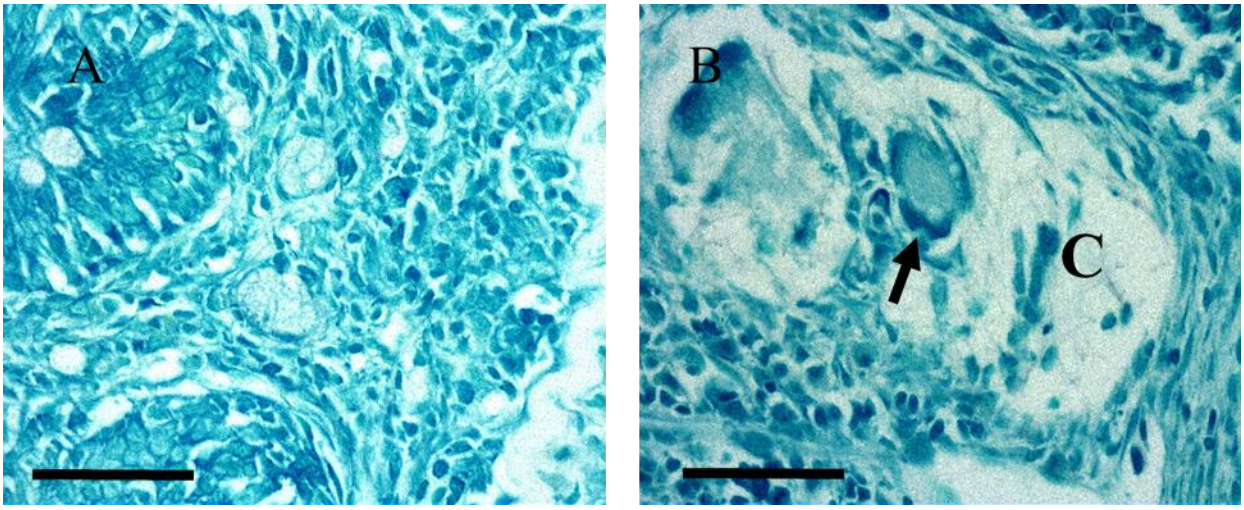

Fig. 8

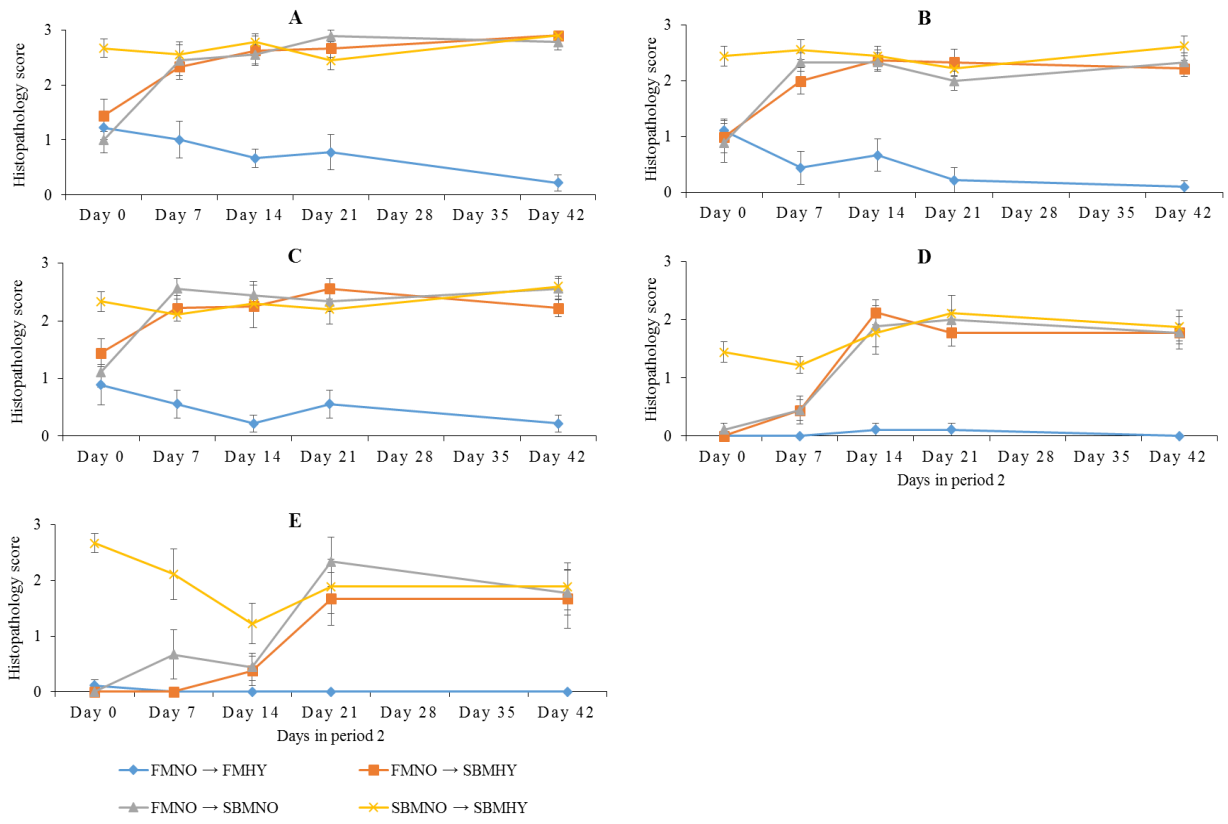
A
B
C
D
E
Histopathology score
Day 0
Day 7
Day 14
Day 21
Day 28
Day 35
Day 42
Days in period 2
FMNO → FMHY
FMNO → SBMHY
FMNO → SBMNO
SBMNO → SBMHY

Fig. 9

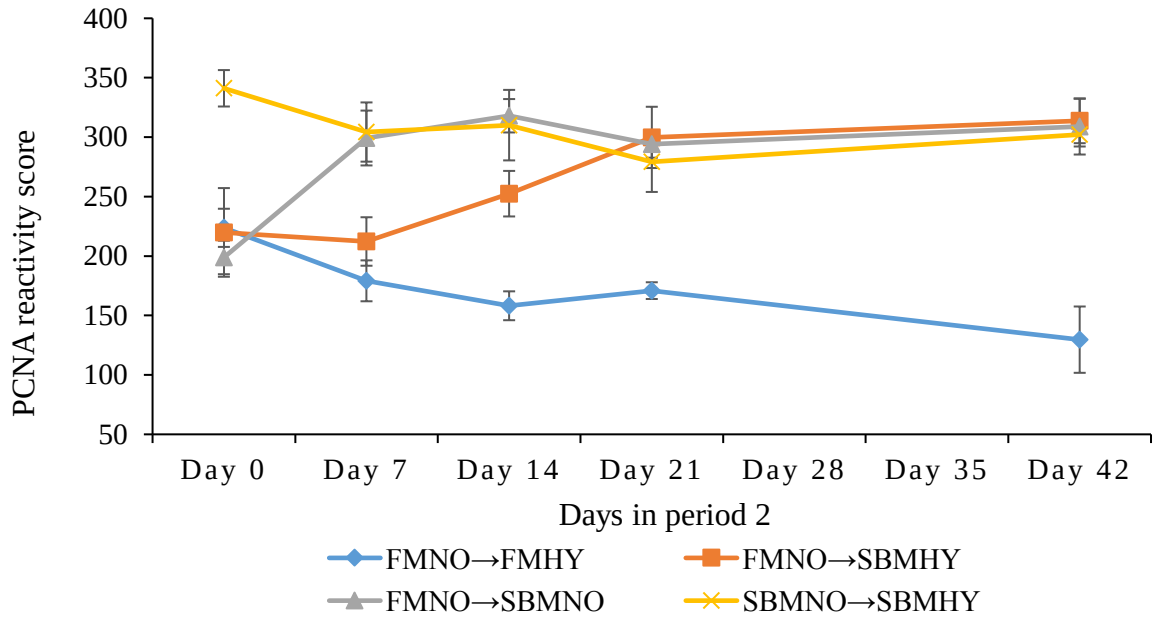
400
350
300
250
200
150
100
50
PCNA reactivity score
Day 0
Day 7
Day 14
Day 21
Day 28
Day 35
Day 42
Days in period 2
FMNO→FMHY
FMNO→SBMHY
FMNO→SBMNO
SBMNO→SBMHY

Fig. 10

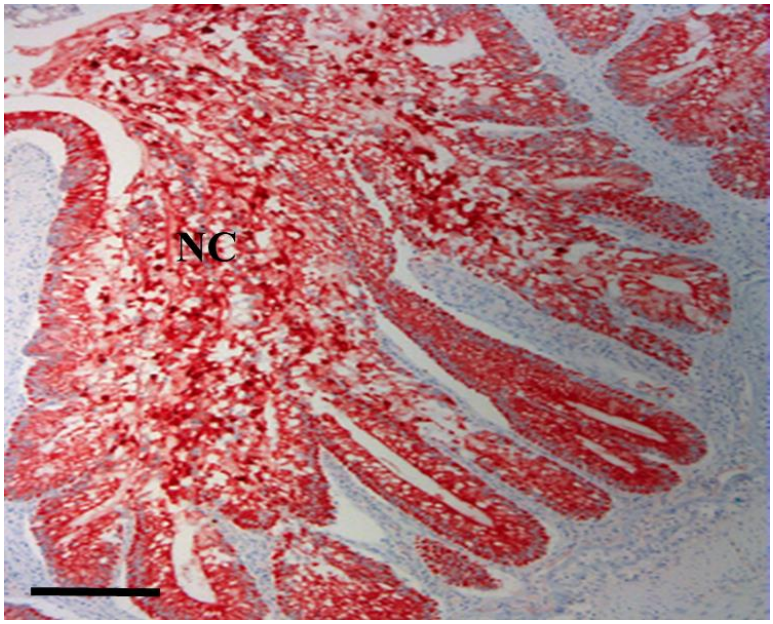

Fig. 11

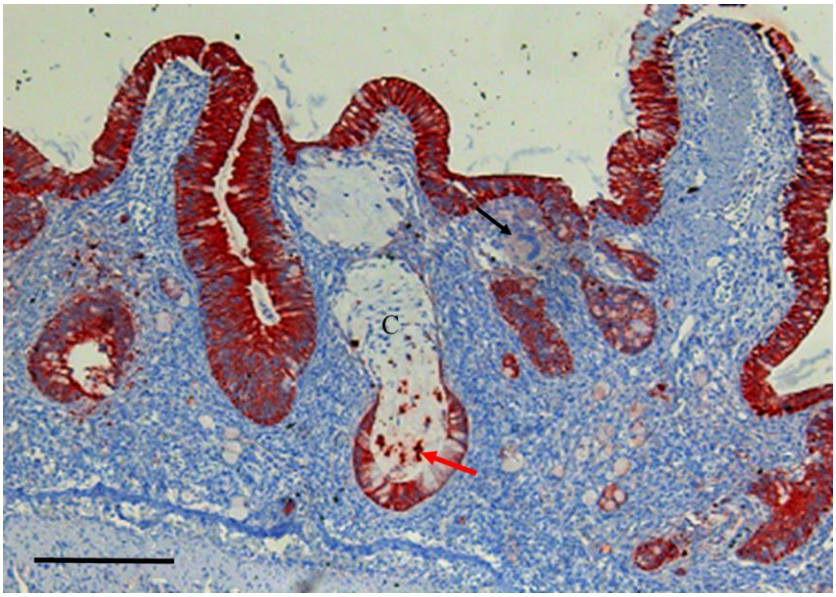

Fig. 12