



Norwegian University
of Life Sciences

Master's Thesis 2016 30 ECTS
Department of Animal and Aquacultural Sciences

The effect of dietary antioxidants on hyperpigmented fillet spots of Atlantic salmon (*Salmo salar* L.)

Weizhi Wang
Aquaculture

**The effect of dietary antioxidants on hyperpigmented fillet spots of
Atlantic salmon (*Salmo salar* L.)**

Master's thesis in Aquaculture

(30 ECTS)

By

Weizhi Wang

Main supervisor

Turid Mørkøre

Co-supervisor

Thomas Larsson

Department of Animal and Aquacultural Sciences

Norwegian University of Life Sciences (NMBU)

Post Box 5003

1432 Ås, Norway

May 2016

Acknowledgment

Finally I have accomplished my master study, majoring in Aquaculture in Norway. It was a pleasant and unforgettable experience to obtain this opportunity to study in Norway. Thanks to the Norwegian University of Life Sciences (NMBU) for accepting me as a master student and gives me a lot of knowledge and unforgettable experiences. Thanks to Norwegian Fishery and Aquaculture Industry Research Fund (FHF) for funding the research project “Dark spots in salmon fillet”.

Firstly, I have to sincerely thank Dr. Turid Mørkøre, my great supervisor, for helping me a lot from choosing the subject to modifying the thesis, which spent her much invaluable time. I really appreciate her from my heart. She is an ebullient and precise scientist with logics who gave me lots of inspirations, motivations and suggestions, guiding me to be interested in sampling and every step. I would like to express my thanks to my co-supervisors Dr. Thomas Larsson who is warm-hearted and patient, thanks for all the generous help and precious time from analysis instruction to thesis modification.

I want to show my great love to my family, especially my mom Wanglian Li. They gave me support both in spirit and finance, and helped me finish my master study in Norway.

I really appreciated all the personnel both at Marine Harvest and Nofima for helpful assistance during the whole sampling and analysis. Special thanks to Raul, Pradip and Roman for your company and advices during writing thesis. Thanks to all my friends who helped and encouraged me during this period.

Weizhi Wang

Ås, 2016

Abstract

Superficial discolored spots on Atlantic salmon fillets is a serious problem for the farming industry. Fillets with large dark stained spots are downgraded by the processing industry while smaller spots are removed, requiring extra labour. The main aim of the present study was to investigate the effect of diet on appearance, location and size of dark stained spots. The fish used were Atlantic salmon (*Salmo salar* L.) fed a standard commercial feed (Control) or the same feed added antioxidants (vitamin C, E and selenium) (Antioxidant). The experiment was carried out from 7th January to 13th March 2015. The results showed that the supplementation of antioxidants had no significantly effect on growth (average body weight 4 kg) or other biometric traits, but improved the fillet quality. Significantly lower occurrence of spots (31% vs. 45%), lower number of dark stained muscle segments (1.4 vs. 2.3), smaller fillet spot size (0.6 vs. 2.2 score) and lower fillet gaping score (0.8 vs. 1.0) were found of the Antioxidant group as compared to the Control group. Results showed that the melanin (40%) and a combination of melanin and scar (25%) were dominating the visual appearance of spots. Colorimetric analysis of the dark stained spots of the Antioxidant group revealed paler (higher L* value), less redness (lower a* value) and less yellowness (lower b* value) as compared to the Control group. Colorimetric characteristics of the dark spots were stable during one week of ice storage. Image analysis showed significantly higher lightness (higher L* value), less yellowness, larger area and wider width of myocommata of the Antioxidant group compared with the Control group. It is concluded that dietary supplementation of antioxidants reduced fillet gaping, occurrence of dark spots, spots size and number of dark stained muscle segments significantly.

Key words: Atlantic salmon, antioxidant, vitamin C, E, selenium, dark stained spot, segment, myocommata, lightness (L*), redness (a*), yellowness (b*)

Contents

Acknowledgment.....	I
Abstract	III
List of figures	V
List of tables	VIII
1 Introduction	1
2 Theoretical background	3
2.1 Flesh quality	3
2.1.1 Color.....	3
2.1.2 Gaping	4
2.1.3 Texture.....	5
2.1.4 Flavor.....	5
2.1.5 Fat content	6
2.2 Melanin.....	7
2.3 Melanization of skeletal muscle of fish.....	8
2.4 Antioxidants.....	11
3 Materials and Methods	14
3.1 Fish and feed regimes.....	14
3.2 Sampling of fish	15
3.3 Flesh quality measurements	15
3.3.1 Fillet color	15
3.3.2 Gaping	16
3.4 Visual inspection of hyper pigmentation.....	17
3.5 Colorimetric analysis of hyper pigmented muscle	18
3.6 Image analysis	19
3.6.1 Measuring color, area and width of myocommata	20
3.7 Statistical analyses.....	21
4 Results	22
4.1 Biometric traits	22
4.2 Tissue evaluation	23
4.2.1 Visual appearances of fillet and dark spots	23
4.2.2 Colorimetric changes of melanin	29
4.2.3 Image analysis	35
5 Discussion	37
5.1 Biometric traits	37
5.2 Tissue evaluation	38
6 Conclusion.....	44
7 References	45
9 Internet resources	57
10 Appendixes	58

List of figures

Figure 2.1: Structure of eumelanin and pheomelanin (Wiki, 2015).

Figure 2.2: Salmon product sold in REMA 1000 with stain removed (Wang, 2015).

Figure 3.1: Marine Harvest research station, where the feeding trial was carried out (Wang, 2015).

Figure 3.2: *Salmo*Colour FanTM (DSM) (Wang, 2015).

Figure 3.3: Image illustrating how the fillet was divided into areas: B1, B2 and RYGG according to the national FHF standard; The area circled with yellow oval shape is a dark spot in the area B1, and the blue vertical line illustrates the distance from the center of the spot to the lateral line of the fillet. The number and location of dark stained spot was recorded by counting segments from the anterior end. The spot on the image covers 6 muscle segments, from number 8 to 13.

Figure 3.4: Konica Minolta CR400 Chroma Meter used for colorimetric analysis of dark spots on Day 0 and Day 7 post mortem.

Figure 3.5: Arrangement of fish myotome and myocommata (Kiessling et al. 2006)

Figure 3.6: Image analysis of the RGB values of five myocommatas.

Figure 3.7: Measurement of the area (yellow area) and width of five myocommatas at three points (blue line).

Figure 4.1: (a) Fillet gaping score; (b) Fillet color score of Atlantic salmon (*Salmo salar* L.). The salmon were fed a standard feed (Control) or the same feed added vitamin C, E and selenium (Antioxidant) during a 10 weeks period before slaughter. Results are presented as LS-Means \pm SE and different superscripts indicate significant differences between dietary treatments ($p \leq 0.05$).

Figure 4.2: (a) Melanin score in fillet (score 0 - 8); (b) Melanin score in belly (score 0 - 3); (c) Melanin score in organs (score 0 - 3) of Atlantic salmon (*Salmo salar* L.). The salmon were fed a standard feed (Control) or the same feed added vitamin C, E and selenium (Antioxidant) during a 10 weeks period before slaughter. Results are

presented as LS-Means \pm SE and different superscripts indicate significant differences between dietary treatments ($p \leq 0.05$).

Figure 4.3: (a) Melanin frequency; (b) Distance from the center of the spot to the latera line of the fillet; (c) Number of dark stained muscle segments of Atlantic salmon (*Salmo salar* L.). The salmon were fed a standard feed (Control) or the same feed added vitamin C, E and selenium (Antioxidant) during a 10 weeks period before slaughter. Results are presented as LS-Means \pm SE and different superscripts indicate significant differences between dietary treatments ($p \leq 0.05$).

Figure 4.4: (a) Location distribution of stained spots in the fillet; B1 belly anterior, B2 belly posterior, RYGG dorsal; (b) Visual appearance of stained spots of Atlantic salmon (*Salmo salar* L.), M + B combination of both melanin and blood, M + S combination of both melanin and scar, B + S combination of both blood and scar. The salmon were fed a standard feed (Control) or the same feed added vitamin C, E and selenium (Antioxidant) during a 10 weeks period before slaughter. Results are presented as LS-Means \pm SE and different superscripts indicate significant differences between dietary treatments ($p \leq 0.05$).

Figure 4.5: (a) Size distribution of spots within each fillet location; (b) Distribution of stained segment of Atlantic salmon (*Salmo salar* L.). B1: belly anterior; B2: belly posterior; RYGG: dorsal.

Figure 4.6: Lightness (L^* value) of dark stained spots of Atlantic salmon (*Salmo salar* L.) fillets on Day 0 and Day 7. Results are presented for hyper-pigment areas with increasing discoloration. Score 1 grayish shade, score 2 marked spot ≤ 3 cm, score 4 marked dark stained spot 3 - 6 cm. The salmon were fed a standard feed (Control) or the same feed added vitamin C, E and selenium (Antioxidant) during a 10 weeks period before slaughter. Results are presented as LS-Means \pm SE and different superscripts indicate significant differences between dietary treatments ($p \leq 0.05$).

Figure 4.7: Redness (a^* value) of dark stained spots of Atlantic salmon (*Salmo salar* L.) fillets on Day 0 and Day 7. Results are presented for hyper-pigment areas with

increasing discoloration. Score 1 grayish shade, score 2 marked spot ≤ 3 cm, score 4 marked dark stained spot 3 - 6 cm. The salmon were fed a standard feed (Control) or the same feed added vitamin C, E and selenium (Antioxidant) during a 10 weeks period before slaughter. Results are presented as LS-Means \pm SE and different superscripts indicate significant differences between dietary treatments ($p \leq 0.05$).

Figure 4.8: Yellowness (b^* value) of dark stained spots of Atlantic salmon (*Salmo salar* L.) fillets on Day 0 and Day 7. Results are presented for hyper-pigment areas with increasing discoloration. Score 1 grayish shade, score 2 marked spot ≤ 3 cm, score 4 marked dark stained spot 3 - 6 cm. The salmon were fed a standard feed (Control) or the same feed added vitamin C, E and selenium (Antioxidant) during a 10 weeks period before slaughter. Results are presented as LS-Means \pm SE and different superscripts indicate significant differences between dietary treatments ($p \leq 0.05$).

Figure 4.9: (a) Average width and area of myocommatas of Atlantic salmon (*Salmo salar* L.). The salmon were fed a standard feed (Control) or the same feed added vitamin C, E and selenium (Antioxidant) during a 10 weeks period before slaughter. Results are presented as LS-Means \pm SE and different superscripts indicate significant differences between dietary treatments ($p \leq 0.05$).

Figure 4.10: (a) Lightness (L^* value); (b) Redness (a^* value); (c) Yellowness (b^* value) of myocommata of Atlantic salmon (*Salmo salar* L.). The salmon were fed a standard feed (Control) or the same feed added vitamin C, E and selenium (Antioxidant) during a 10 weeks period before slaughter. Results are presented as LS-Means \pm SE and different superscripts indicate significant differences between dietary treatments ($p \leq 0.05$).

List of tables

Table 3.1 Scale for fillet gaping score (Andersen et al., 1994).

Table 4.1: Biometric traits of Atlantic salmon (*Salmo salar* L.) fed a standard feed (Control) or the same feed added vitamin C, E and selenium (Antioxidant) during a 10 weeks period before slaughter. Results are presented as LS-Means \pm SE and different superscripts indicate significant differences between dietary treatments ($p \leq 0.05$).

Table 4.2 Correlation coefficient and p -value of CIE L*a*b* value determined on Day 0 and Day 7.

1 Introduction

Aquaculture accounts for almost half of the total food fish supply over the world and the percentage is increasing every year with an average growth rate of 8.8 % since 1980 (FAO, 2012).

Salmonids are popular species in aquaculture economic industries owing to high nutritional value with high quality proteins, omega-3 fatty acids (ω -3 FA), vitamins and minerals that have benefits to human beings (Børresen, 2008). Taking use of the geographical advantages, Norway becomes a world leading producer of farming Atlantic salmon and the second largest seafood exporter in the world. In 2012 about 1.23 million tones Atlantic salmon were produced in Norway (Fisheries, 2014), which was responsible for more than 60 percent of the global total salmon production in the world (FAO, 2015).

Flesh quality of farmed Atlantic salmon involves several indexes including color, texture, gaping and drip loss. To determine good appearance of product, consumers use their sense for evaluation and will make a decision based on color (Anderson, 2000). Flesh quality of Atlantic salmon has much to do with breeding (Gjedrem, 1997), diet composition (Torstensen et al., 2008), environmental condition and starvation prior to harvesting (Mørkøre, 2008).

Dark stacked superficial spots are frequently termed as salmon “black spots” or “melanin”. The presence of melanin in farmed salmon, especially in the muscle fillet, represents a considerable quality problem for the salmon industry affecting up to 20% of the fillets at the processing plants (Mørkøre, 2012). Most of the consumers tend to associate any discoloration of the muscle with lower product quality, which leads to a reduced price or even rejection of the fillets that present melanin spots (Bjerkeng, 2004a, b; Reidar et al., 2007). It is generally thought that the main factor causing melanin spots in fillets is related to vaccines containing

oil adjuvants (Fagerland et al., 2013), but it was also proved that other factors like PD diseases (Bjerkeng, 2004a), environmental conditions and genetics can exhibit the same problem even without vaccination (Torrissen and Naevdal, 1988).

Dark stained spots of fillet are a response to tissue damages or local inflammatory conditions (FAQ, 2013), and it can occur in mainly three locations: organ, peritoneum and muscle fillet. The size of the spots vary a lot from visible minimum size to several dm².

The main aims of this thesis is to investigate the effect of diet on the appearance, location and size of dark spots in fillet by visual observation, colorimetric analysis and image analysis.

2 Theoretical background

This chapter is composed of three sections. The first section provides general information about flesh quality and quality measurements of Atlantic salmon. The second part gives general view of melanin and melanization of skeletal muscle of fish. The final part provides information oabout antioxidants.

2.1 Flesh quality

There are several important attributes of flesh quality of salmon considered by the consumers such as appearance, texture, flavor and fat content (Haard, 1992; Thomassen et al., 1997).

2.1.1 Color

Up to 40 % of the consumers have preferences for red-color of salmon products (Robb, 2001b; Skonberg et al., 1998). Astaxanthin is a beta-carotenoid pigment that is most commonly found in Atlantic salmon giving the fish its pinkish color (MacDermid et al., 2012). However, Atlantic salmon is not capable to endogenously synthesize astaxanthin, therefore it must be supplemented in fish feed (Anderson, 2000).

Measurements of color

Pigment content is measured visually or chemically. Traditional measurements of carotenoid pigments in salmon fillet was conducted by high-performance liquid-chromatography (HPLC) (Bjerkeng et al., 1997). But this traditional method has the disadvantages of low efficiency, high cost and destruction of fillet even it is reliable. Mostly used method in industries for visual color analyzing is DSM Salmon FanTM card produced in Switzerland that is

recognized for color measurement internationally with a value ranging from 20 (very pale red) to 34 (highest red intensity) (Forsberg and Guttormsen, 2006). In recent years, computational techniques combined with a digital camera, image processing software has been applied to measure the color of salmon fillet (Forsyth and Ponce, 2003).

2.1.2 Gaping

Fillet gaping is a post-mortem phenomenon that can deteriorate the appearance of fillets significantly and fillets with gaping are downgraded because of rejection by consumers due to its unappealing appearance (Pittman et al., 2013). Gaping is mainly because interaction between forces pulling the muscle apart and the strength of the tissue, leading to rupture of the connective tissue and producing flaking of the fillet (Kießling et al., 2004). Fillet firmness is a critical sensory quality characteristic that can influence gaping considerably and fillets with soft texture cannot be sold as high quality product. There are various factors that can affect firmness including handling stress, fish size, fish age and protein content of the fish (Bremner et al., 1985). Bahuaud et al. (2010) reported that the firmness decreases during the first four days of storage as a consequence of protein hydrolysis.

Measurements of gaping

Analysis of gaping includes several methods, but the most used method is on a scale either with ranges from 1 to 4, where 1 = gaping, 2 = minor gaping (1-5 cm longitudinally), 3 = slight gaping (6-10 cm) and 4 = great gaping (> 10cm) (Kießling et al., 2004) or from 0 to 5, where 0 represents no slits, 1= less than 10 small slits (<2 cm), 2 = less than 10 slits, 3 = more than 10 slits or some larger than 2 cm, 4 = many large slits and 5 = extreme gaping (Andersen et al., 1994).

2.1.3 Texture

Fillet texture is one of the most important quality parameters for producers, processors and consumers (Hyldig and Nielsen, 2001). The textural properties of fish is influenced by collagen properties. Fish muscles are generally softer compared to land-living domesticated animals due to their low content of collagen and fewer cross-links (Liu et al., 2013). Consumers commonly want salmon with firm texture (Merkin et al., 2014) and high juiciness fillet rather than dry fillets. Juiciness of salmon fillets is related to the amount of liquid and intra-muscular fat (Ofstad et al., 1996). Liquid holding capacity of muscle is highly influenced by fibril swelling, contraction and the distribution of fluid between intra and extracellular locations (Offer and Trinick, 1983).

Measurements of texture

Tensile texture analysis of salmon is commonly measured by automatic penetrometer using various devices like Warner Bratzler shear blade (V-shaped blade) and flat-ended cylinders, knives or Kramer shear cell (multiple blades) (Torrissen et al., 2001).

2.1.4 Flavor

Flavor is crucial for evaluating fish quality and freshness. The flavor, which contains two elements: taste and odor, can determine the food recognition, acceptance and nutrient. When the fish tastes good and gives pleasant odor, it is more attractive to humans (Ensor, 1989). Off-flavor in fish product is associated with deterioration caused by bacteria (Connell, 1990) and related to lipid oxidation during chilled storage or transportation (Jones and Carton, 2015). Odor can be also affected by the treatment of salmon fillet by different sodium salts before storage (Sallam, 2007).

Measurements of flavor

Measurements of flavor often accomplished by Electronic noses and electronic tongues which are typically array of sensors used to characterize complex samples. Array of gas sensors are termed as electronic noses while array of taste sensors are termed as electronic tongues (Stetter and Penrose, 2002). Electronic noses are used in quality control and process operations in the food industry while the electronic tongue are widely used in taste studies.

2.1.5 Fat content

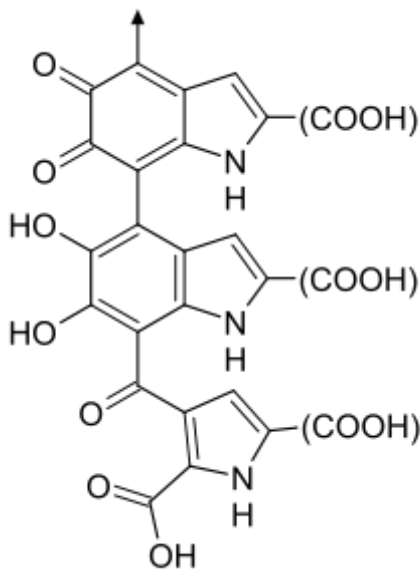
Fat content is one of the most important characteristics of salmon fillet quality, and may vary widely from fillet to fillet. The fat content of Norwegian salmon fillets ranges from 11% to 19% (Fjellanger et al., 2000). A large proportion of the lipid in salmon fillet is congregated in white stripes of connective tissue segmenting the red-colored muscle tissue in vertical blocks and giving the fillet a zebra-like appearance (Stien et al., 2007).

Measurements of fat content

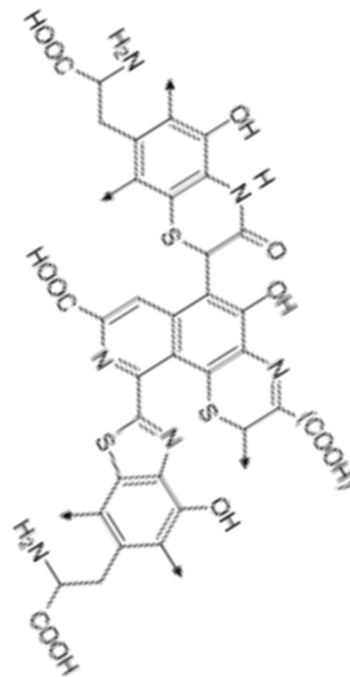
Fat content can be measured by chemical extraction methods, Torry Fish Fat meter, computerized tomography (CT), near-infra-red (NIR) and spectrophotometry (Fjellanger et al., 2000). But chemical analysis is both time-consuming and labor-consuming, and CT and NIR have high requirement for expensive equipment. Therefore the image analysis is more likely to be favored as it is relatively labor-saving, economical and effective. Recently a rapid measurement of fat content in live and slaughtered salmon has been presented by a German professor called Bruker, O.G. This instrument is a low field mobile NMR analyzer for relaxation measurements in the near surface volume of samples unrestricted in size.

2.2 Melanin

Melanin refers to a group of natural pigments with high molecular weight, complex biopolymer of indole quinone, insoluble and stable pigments (Jacobson, 2000) which are normally found in most organisms (animals and plants). Melanin is produced in specific cells called melanocytes by oxidating the amino acid tyrosine, followed by polymerization. Melanin has three main forms including eumelanin, pheomelanin, and neuromelanin (Figure 2.1), with eumelanin being the most common type found in teleosts (bony fish) (Agius and Roberts, 2003).



Part of the molecular formula of eumelanin.



Part of the molecular formula of pheomelanin.

Figure 2.1: Structure of eumelanin and pheomelanin

The synthesis of melanin in mammals happens in melanocytes, of which origin is the embryonic neural tube (Sulaimon and Kitchell, 2003). Melanocytes are the cells that are responsible for both producing melanin and dark pigmentation of fish (Hearing et al., 1991). But others think that melanogenesis in heterothermic vertebrates happens in the cells derived from mesenchyme of the haematopoietic lineage (Sichel et al., 1997). Melanin can be

detected in skin, eyes, and hair, and has various functions in diverse organisms, for example, protecting the skin cells against from UVB radiation damage in humans since melanin has the capability of dissipating absorbed UV radiation. Furthermore, melanin can protect against damage from high temperature, chemical stress, and biochemical threats (FAO, 2015).

2.3 Melanization of skeletal muscle of fish

Melanin has positive roles in many organisms, but the presence of melanin in fish fillets can lead to serious reductions of product quality (Koteng, 1992), thus affecting the economic yield. This issue not only exists in salmon along the whole coast in Norway but also other dominant salmon farming countries like Chile, UK and Ireland. As was reported, the problem caused losses to the Norwegian fish farming industry around one hundred million Euros yearly (NMBU, 2015). Light shades, darkly stained spots and grey or red spots on the salmon fillets are collectively known as melanin spots, and the darkly stained fillet spots as a result of melanin accumulation and red to grey black spots are blood pigment because of the formation of haemorrhages or scar tissue or combination of both (FAO, 2013). The occurring of spots includes two ways: inflammation effects and scar formation, both of them indicate acute and old tissue damage.

The spot can vary from light pale shadow to intensive darkness up to several centimeters in diameter or even larger. It will not disappear even after baking or smoking and give unsatisfied impression of product quality to consumers (Mørkøre, 2008). The rate of the downgrading of salmon fillets because of melanin pigment reached up to 30% in 2006 (Thorisen, 2006), and nearly 8-20% of the entire fillets with melanin spots was reported in 2007 in Norway. Most fillets with dark spots were just thrown out (Mathiassen et al., 2007), resulting in great economic losses to producers who aim to obtain fast growth and healthy fish with great visual appearance, flavor and texture (FAO, 2005; Kiessling et al., 2006). As the salmon fillets are stained with dark or pale spots, they are impossible to sell as whole

fillets, therefore the spots must be removed before sending them to the market. Trimming of spots results in aberrant appearance and economic loss especially for larger or deeper stain removal (Figure 2.2).



Figure 2.2: Salmon product sold in REMA 1000 with spot removed (Wang, 2015)

Melanin is formed as a support to the defense and repair processes that occur following chronic inflammation (NVH, 2013). Undesirable black color (melanin hyper-pigmentation) on salmon fillets is the main obstacle for achieving high product quality even though the melanin shows no harm or toxicity to humans in many food items (FAO, 2013). The buyers tend to consume the good looking fillet product with no discoloration or dark pigmentation since they think fillets with dark spots are unhealthy, and they are even willing to pay double or more price for the good quality product without stained melanin (Reidar et al., 2007). Unfortunately this situation has not improved in recent years, and up to 20% at some fish farms exhibits dark spots (Mørkøre et al., 2015).

The spot often occurs on the peritoneum and visceral organs as well as muscle tissue of ectothermic vertebrates (Mackintosh, 2012). Usually the occurrence of melanin spots in the anterior part of the fillet is relatively higher than other areas as reported (Mathiassen et al., 2007; Mørkøre, 2012). The melanin can be found both around the peritoneal membrane of abdominal wall and the surface of fillet or in deep muscle with diameter around 1 - 4cm or larger (Mørkøre, 2008). Also, it has been shown that melanin could be found in the location of injury or infection area in diverse species. For the whole salmon fillet, the pigmentation appears mostly superficially on the anterior part of belly (B1), but one data showed higher value for the posterior part of belly (B2), but hardly dark spots are found on the dorsal part of the fillet (RYGG) (Mørkøre, 2012).

By the statistics of 2013 in Norway, approximately 12% of salmon fillets had light grey spots with diameter below 3cm while darkly stained spot smaller than 3cm reaches up to 2% on average (FAO, 2013). Geographically, the distribution of the melanin varies in Norway, the prevalence of the northern part and southern part are 12% and 22% respectively, while the occurrence of melanin in central Norway has a rate of 15%. The differences between regions cannot be explained by temperature (Mørkøre, 2012).

In fish, the melanogenesis occurs in the dermis and the cells of pigment melanin-generating called melanocytes (Agius and Roberts, 2003). Some researchers tied the melanosis in salmon skeletal muscle to immune and pigmentary systems of fish, summarizing that the granulomatous inflammation was related to pigment producing (Larsen et al., 2012). The symptom of fish showed darkened skin might be caused by impaired production or malfunction of melanocyte-stimulating hormones or broken tyrosine phosphorylation affecting the regulation of melanosome distribution in melanocytes (Chen et al., 2004). Pathological pigmentation like melanin spots can be caused by multiple factors. Normally thinking, vaccination is believed to be the one of the causes of melanin spots on farmed salmon fillet. Around 13% higher incidence of melanin was shown in vaccinated salmon

fillets compared with the unvaccinated (Jafelice, 2014) mainly because the vaccine contains non-metabolizable mineral oil consisting of long inert hydrocarbons chains with resistance to biochemical reactions which can trigger more intense inflammation response than metabolizable oils (Spickler and Roth, 2003). It revealed that vaccine showed no adverse effects on fish but specific inflammatory response at the site of injection and the area around peritoneum (Mutoloki et al., 2004).

Fish exposed to stressors including artificial stress and physical stress, such as water quality variation and handling during the production are more likely to exhibit melanosis since the process of response to those stressors can influence fish health and physiology like disease resistance, growth, metabolism and behavior (Barton et al., 2000).

Pancreas disease caused by virus is one of the most serious diseases facing the Norwegian salmon industries today. The fish infected with pancreas disease are susceptible to parasitism and secondary infection like bacterial disease (Ruane et al., 2005). Pancreas disease -induced quality downgrading leads to great losses and some anecdotal evidence shows that pancreas disease may cause general muscle quality associated with severe discoloration (Hoel, 2007).

Recently, new findings about black spots on salmon fillets have come to light: a large number of virus called Piscint orthoreovirus (PRV) was found in these dark spots of farmed salmon fillets, and its relationship with inflammation of heart and skeletal muscle (HSMI) has been identified previously in farmed salmon in Norway (NMBU, 2015).

2.4 Antioxidants

Antioxidants are a type of molecules that are capable to terminate the process of chain reaction during oxidation. Antioxidants have been added to present in farmed fish feeds can

date back to 20 years ago in the USA to avoid rancidity of fats, destruction of vitamins and pigment caused by oxidation (FAO, 2015). In Norway, antioxidants are widely used not only in livestock feed industries but also in fish feed production, such as Atlantic salmon dietary feed supplemented with vitamins and minerals (Hamre et al., 2004). Many studies have thought about the effect of feed supplementation of antioxidants on flesh quality in salmonids (Jobling et al., 1998). To obtain high health and performance of fish, functional feeds have been developed to enhance conventional feeds by inclusion of antioxidants (vitamins and Se) (Tacchi et al., 2011).

Vitamin E (VitE) is a lipid-soluble antioxidant that can stimulate the immune system of fish and maintain physiological processes like growth and immune function (Andrade et al., 2007), increasing the tolerance of fishes to adapt the stress (Chen et al., 2004). Besides, it has the ability of protecting fish immunity, meat quality and red blood cells resistance against hemolysis (Blaxhall and Daisley, 1973). VitE deficiency reveals some symptoms like growth reduction, damage to collagen and atrophy of muscle darkened skin. The minimum demand of VitE among juvenile salmon has been estimated as 60 mg/kg dry feed (Hamre and Lie, 1995), a value higher than that for other salmonids. To achieve optimum flesh pigmentation and to prevent oxidation of salmon fillet during storage, a dietary supplement of 500 mg/kg VitE is needed (FAO, 2015; Woodeard et al., 1994).

Vitamin C (VitC) is a water soluble vitamin widely used in fish diets for obtaining growth and development, which can protect phagocytic cells and surrounding tissues from oxidative damage. An increased immune response due to high levels of VitC supplementation has been demonstrated in several fish species (Gatlin, 2002). Physiological effects of VitC demonstrated in fish are related to reproduction (Waagbø et al., 1989), immune functions and disease resistance (Hardie et al., 1991), iron metabolism and hematology (Maage et al., 1990), and lipid metabolism (John et al., 1979). When fed VitC-deficient diets, reduced reproductive performance has also been reported in rainbow trout (Sandnes et al., 1984). The minimum

dietary VitC requirement for optimal growth and normal development in Atlantic salmon fry ranges from 10 to 20 mg kg⁻¹ (Sandnes et al., 1992) and the requirement for rainbow trout between 40 and 100 mg kg⁻¹ (Sato et al., 1982). In coho salmon a dietary content of 50 mg/kg prevents deficiency symptoms, 100 mg/kg supports optimal growth, while higher levels are needed to maintain high tissue reserves or to promote rapid wound repair (Halver et al., 1969). VitC-deficient salmon and trout exhibits structure deformities and internal hemorrhaging (Sato et al., 1983)

Selenium (Se) is an essential nutrient in both human and animal diets to fulfill basic requirement (Hamilton et al., 2004), which is a component of the enzyme glutathione peroxidase that can remove hydrogen peroxide and lipid peroxidases from cells. Se requirement among fish varies from 0.1 to 0.5 g / kg (dry mass) (Gatlin et al., 1984). 3 g / kg Se is the maximum dosage for carp, and over maximum dosage, Se bio-accumulates rapidly and leads to harmful influences on fish, and elevating mortality when using over 13 g / kg (Jovanovic et al., 1997). In 2012, the EU has limited the amount use of Se added into the feed composition to a level under 0.5 g / kg (dry mass). Recent investigations provided evidence that farmed fish required a higher content of Se in diet (Zhou et al., 2009). Se requirement of fish subjected to stressful conditions may be up to 4.0 g / kg (dry mass) (Rider et al., 2009) and inadequacy of Se will negatively affect the regulated function but too much is toxic (Koller et al., 1986).

VitC can prevent the appearance of VitE deficiency signs in Atlantic salmon in a dose-dependent way (Hamre et al., 1997). VitC and VitE as antioxidants have cooperative action against the oxidation of lipid in solution and lipoproteins, they function at their own site individually and furthermore act synergistically (Niki et al., 1995). VitC might increase the biological utilization of dietary Se in chickens, and dietary VitC elevates the Se containing glutathione peroxidase enzyme activity and reduces the dietary Se requirement of VitE deficient chickens (Combs and Scott, 1976).

3 Materials and Methods

3.1 Fish and feed regimes

This feeding trial was conducted at Marine Harvest seawater research station (Norwegian west coast, Averøy) as a part of research project “Dark spots in salmon fillet” funded by the Norwegian Fishery and Aquaculture Industry Research Fund (FHF). The fish used were Atlantic salmon (*Salmo salar* L.), vaccinated with a 6-component vaccine from MSD Animal Health (Norvax Minova 6) in freshwater (Nofima freshwater research station, Sunndalsøra). The salmon were transferred to seawater into two net pens with a volume of 343m³ (7m*7m*7m) on 26.09.2013. The fish received a standard feed until January 2015, thereafter they were randomly distributed six 125 m³ net pens (5m*5m*5m), 180 fish in each net pen on average. The fish were fed a standard feed (Control feed) or the same feed added antioxidants (Antioxidant feed) and each feed was fed to three pens until March 2015 for 10 weeks. The average seawater temperature recorded at the depth of 3m during the whole study period was 5.5°C.



Figure 3.1: Marine Harvest seawater research station, where the feeding trial was carried out (Wang, 2015).

The Control feed used during the time between 7th January and 13th March 2015 was a commercial standard extruded 9mm diameter dry feed containing 37.9 % protein, 33.5 % fat, 7.1 % water, 4.6 % ash 50 mg kg⁻¹ astaxanthin, vitamin C 50 mg kg⁻¹ and 201mg kg⁻¹ vitamin E (Optiline V 2500 40A) produced by Skretting AS, Averøy, Norway. The Antioxidant feed was the same feed supplemented with 350mg kg⁻¹ vitamin C (ROVIMIX® STAY-C® 35, DSM Nutritional Products Ltd, Basel, Switzerland), 500 mg kg⁻¹ vitamin E (dl- α -tocopherol acetate-DSM Nutritional products Ltd, Basel, Switzerland) and 0.2 mg kg⁻¹ selenium (Organic selenium Sel-Plex®, Alltech). Both the Control and Antioxidant diet were coated with rapeseed oil to prevent leaching of nutrients and taste differences, and distributed through automatic feeders manufactured by Sterner Maxi, Sterner, Leksand, Sweden.

3.2 Sampling of fish

The fish were anesthetized (MS 222 metacaine, ALPHARMA, Animal Health Ltd., Hampshire, UK, 0.1 g L⁻¹) and harvested in batches by percussive stunning, two net pens per day from 17th to 19th March 2015. Thereafter, both gill arches were cut and the fish were put into a rectangular container with circulated seawater, where they were bled to death at ambient seawater temperature. Within half an hour, the salmon were weighed whole body firstly, followed by gutting and filleting by a professional worker. All the biometric traits of salmon including body weight, gutted weight, fillet weight and length were logged, and fillets were examined for discoloration before they were individually packed and stored on ice for one week.

3.3 Flesh quality measurements

3.3.1 Fillet color

Visual color was assessed by comparing the fillets against the *Salmo*Colour Fan™ (DSM) with a range from 20 to 34 under standard light conditions in a box within a controlled environment (“Salmon Color Box”, Skretting, Stavanger, Norway). Score 20 refers to pale

color and score 34 the most intense red color (Figure 3.2). The color card readings were performed on the dorsal fillet part: 1) Between the posterior end of the dorsal fin and the gut (NQC-Norwegian Quality Cut); 2) Below the anterior end of the dorsal fin.



Figure 3.2: *SalmoColour Fan™* (DSM) (Wang, 2015)

3.3.2 Gaping

Degree of gaping was measured visually by using a scale ranging from 0 to 5 according to the amount and size of the slits (Andersen et al., 1994) (Table 3.1).

Table 3.1 Scale for fillet gaping (Andersen et al., 1994)

Gaping (score)	Size
0	No slits
1	Few small slits (<2cm, less than 5)
2	Some small slits (less than 10)
3	Some small slits (> 2cm, more than 10)
4	Many large slits
5	Extreme gaping with fillets falling apart

3. 4 Visual inspection of hyper pigmentation

- **Size of the spot**

Registration of dark spots of each fillet was graded from score 0 to score 8 according to the national FHF standard (Norwegian Fishery and Aquaculture Industry Research Fund) (Mørkøre, 2012):

Score 0 = no discoloration

Score 1 = grayish shade

Score 2 = dark stained spot, < 3 cm

Score 4 = dark stained spot, 3 - 6 cm

Score 8 = dark stained, diameter > 6 cm

Registration of dark spots around visceral organs and belly were graded from score 0 to 3 (Taksdal et al., 2012):

Score 0 = no discoloration

Score 1 = tiny spots or dots

Score 2 = observable dark stained spots

Score 3 = large amount of dark stained spots

- **Appearance of the spot**

Appearance of the spots was visually recorded: red (defined as blood), black or dark brown (defined as melanin), grayish (defined as scar).

- **Position of the spot**

The location of the each spot was recorded in the anterior part of the belly flap (B1), posterior part of the belly flap (B2) and the dorsal part of the fillet (RYGG). Also where the spot started

and ended were recorded individually by counting the number of segment from the anterior end of the fillet. The distance (mm) from center of the spot to the lateral line of the fillet were measured and recorded (Figure 3.3).

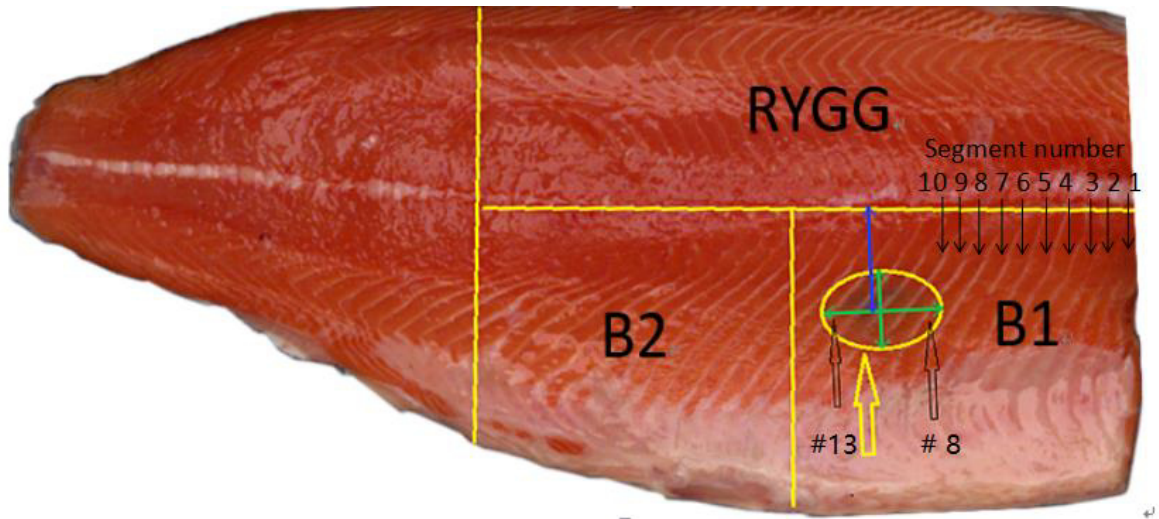


Figure 3.3: Image illustrating how the fillet was divided into areas: B1, B2 and RYGG according to the national FHF standard; The area circled with yellow oval shape is a dark spot in the area B1, and the blue vertical line illustrates the distance from the center of the spot to the lateral line of the fillet. The number and location of dark stained spot was recorded by counting segments from the anterior end. The spot on the image covers 6 muscle segments, from number 8 to 13.

3.5 Colorimetric analysis of hyperpigmented muscle

Each spot was analyzed by Minolta Chroma meter (CR-400 Minolta, KONICA MINOLTA SENSING, INC. JAPAN) (Figure 3.4). The parameters recorded by Minolta Chroma meter were L^* , a^* , b^* values; L^* means lightness of the sample, a^* intensity of red, and b^* intensity of yellow) (CIE $L^*a^*b^*$, 1994). Analyses were performed immediately after slaughtering and filleting (Day 0) and after one week of ice storage (Day 7). Calibration was performed against a white ($L=100$) and black ($L=0$) standard.



Figure 3.4: Konica Minolta CR400 Chroma Meter used for colorimetric analysis of dark spots on Day 0 and Day 7 post mortem.

3.6 Image analysis

A total of 60 fish were randomly selected for image analysis; 10 fish from each net pen with an average fillet weight of 2427 g (Control group) and 2518 g (Antioxidant group). Photography was performed by using the equipment provided by AKVA group Software AS, described in detail by Folkestad et al. (2008). In short, the system consists of a closed box with standardized light and color conditions, a digital camera and a PC for transmitting of the image and software for analysis. Image analyses consisted of measuring the color (RGB) (R-red, G-green, B-blue), area and width of myocommatas number 10 to 14 counted from the anterior end of the fillet. The measurements were conducted by using ImageJ software (a java-based image processing program developed by the National Institute of Health, USA). The scale was defined based on a ruler placed next to the fillet in the picture, and results are reported in mm.

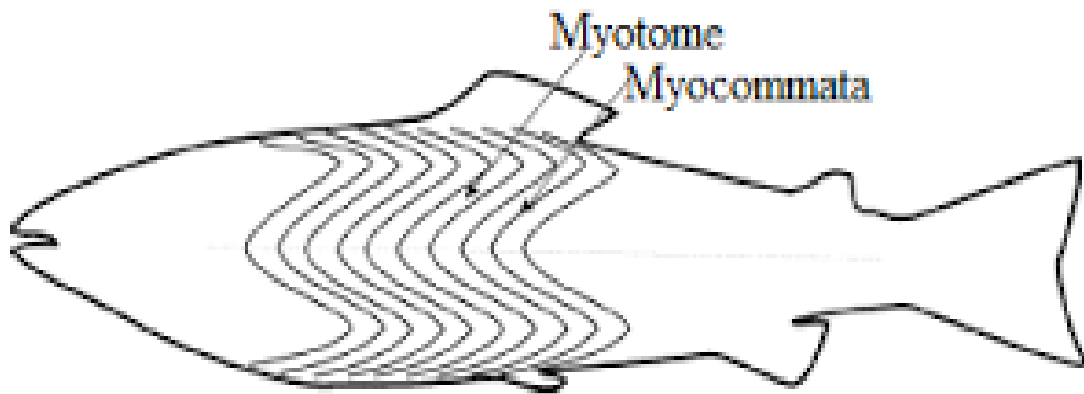


Figure 3.5: Arrangement of fish myotome and myocommata (Kiessling et al., 2006)

3.6.1 Measuring color, area and width of myocommata

A rectangle was drawn 30 mm below the lateral line covering myocommatas number 10 to 14. The height of the rectangle was set as 6 pixels (2.7 mm). The rectangle was cropped out and used for analysis of myocommata number 10 to 14 including RGB, area and width. Measurements of RGB were performed inside each of the five myocommatas (yellow line showed in Figure 3.6). Data was transferred into Excel and further converted into CIE L^* , a^* and b^* .

The saturation of the image were then adjusted in order to select the pixels containing myocommata for measuring area and width of myocommatas (no pixels in muscle segments). The selection of pixels belonging to the myocommata were defined as follows: during the saturation adjustment, the number of selected pixels was increased step by step until the first pixels which were clearly inside the myotome appeared. The selected area (mm^2) was then measured (Figure 3.7). The same area selection was used for measuring the width of each myocommata at three points by drawing a line, at pixels 1, 3 and 6 from edge to edge (Figure 3.7).

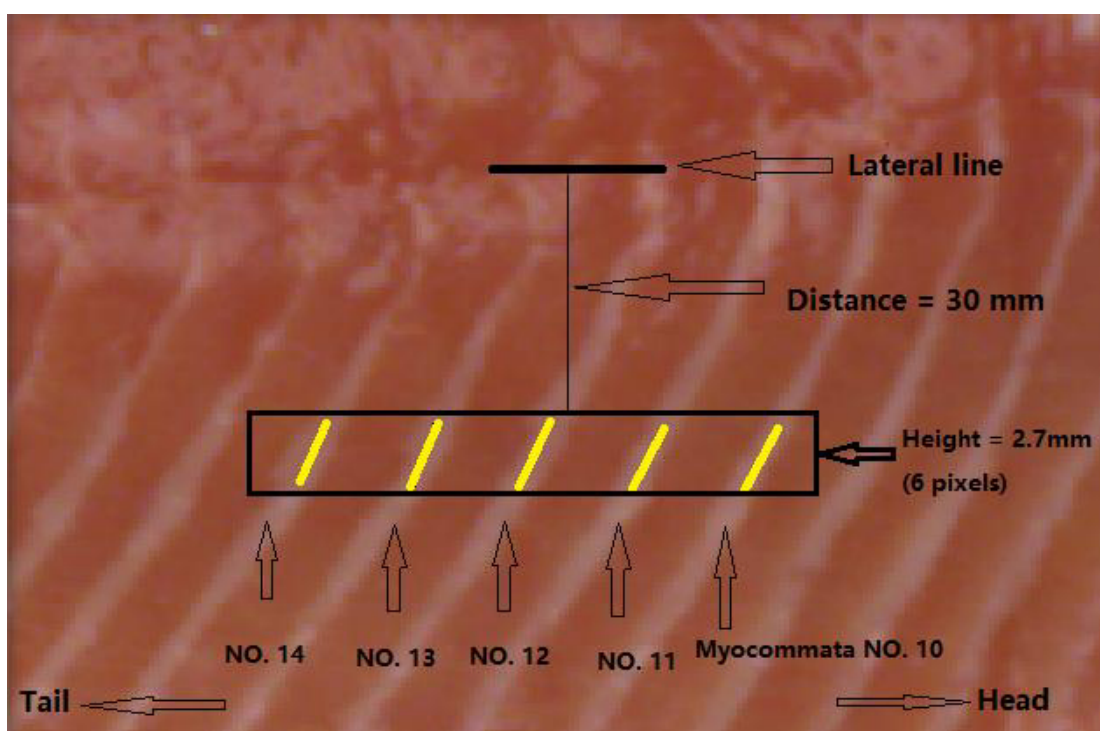


Figure 3.6: Image analysis of RGB values of five myocommatas

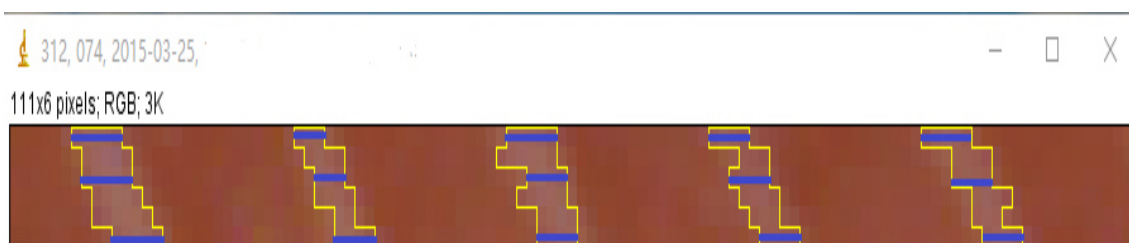


Figure 3.7: Measuring of the area (yellow area) and width of five myocommatas at three points (blue lines)

3.7 Statistical analyses

Various types of statistical methods have been used in analyzing recordings including one-, two-way ANOVA analysis using the Statistical Analysis System program for Windows 64 bytes (Version 9.4; SAS Institute Inc., Cary, USA). Effects of sampling conditions were tested for each trait using the GLM procedure. The alpha level was set to 5% ($p \leq 0.05$ was considered significant).

4 Results

The results chapter contains two parts. In the first part, general biometric traits of salmon are presented between dietary treatments. The second part describes the tissue evaluation of fillets.

4.1 Biometric traits

The average body weight, gutted weight and fillet weight were 4064 g, 3632 g and 2473 g, respectively. The carcass and fillet weight relative to the body weight were 89% and 61%, respectively. The average condition factor was 1.36. Dietary treatments showed no significant effects on biometric traits ($p > 0.35$) (Table 4.1).

Table 4.1: Biometric traits of Atlantic salmon (*Salmo salar* L.) fed a standard feed (Control) or the same feed added vitamin C, E and selenium (Antioxidant) during a 10 weeks period before slaughter. Results are presented as LS-Means \pm SE and different superscripts indicate significant differences between dietary treatments ($p \leq 0.05$).

Biometric traits	Control	Antioxidant	<i>p</i> -value Feed
Body weight, g	4029.1 \pm 87.1 ^A	4098.3 \pm 93.9 ^A	0.6321
Gutted weight, g	3608.2 \pm 77.9 ^A	3654.9 \pm 100.1 ^A	0.7121
Fillet Weight, g	2426.7 \pm 60.0 ^A	2517.8 \pm 74.6 ^A	0.3472
Fillet length, cm	41.2 \pm 0.6 ^A	42.8 \pm 0.8 ^A	0.2551
Fillet yield, % ¹	60.3 \pm 0.6 ^A	60.8 \pm 0.6 ^A	0.5303
Condition Factor ²	1.35 \pm 0.1 ^A	1.37 \pm 0.1 ^A	0.4245
Carcass yield, % ³	89.1 \pm 0.3 ^A	88.9 \pm 0.2 ^A	0.4228

¹ Fillet yield, FY = Fillet weight, g / body weight, g \times 100;

² Condition factor, CF = Body weight, g / (fish length, cm)³ \times 100;

³ Carcass yield = gutted weight, g / body weight, g \times 100;

4.2 Tissue evaluation

4.2.1 Visual appearances of fillet and dark spots

The average gaping score was significantly lower of the Antioxidant compared to the Control group, but no significant differences of color score were found between the dietary treatments (Figure 4.1 a, b).

The Antioxidant group (0.6) showed significantly lower average spot score in fillet and belly as compared to the Control group (2.2) (Figure 4.2 a, b), but dietary treatments had no significant effects on the average score of dark spot on organ (Figure 4.2 c).

The number of fillets with dark spots was significantly lower of the Antioxidant group (31%) as compared with the Control group (45%) (Figure 4.3 a).

The distance from the center of dark spots to the lateral line of the fillet was 3.5 cm on average. Supplementation of antioxidants showed no significant effects on the distance (Figure 4.3 b).

The Antioxidant group had significantly lower amount of dark stained segments (1.4) as compared to the Control group (2.3) (Figure 4.3 c).

The Antioxidant group showed a higher frequency of spots in the B1 (81%), while lower occurrence was observed in B2 (17%) and RYGG (2%) as compared to the Control group (B1 59%, B2 33% and RYGG 8%) (Figure 4.3 a).

The Antioxidant group showed relatively higher occurrence of melanin spots (44%) and spots with a combination of melanin and scar (28%) as compared with the Control group (35% and 23%, respectively). Neither diets showed incidence of combination with melanin, scar and blood spots (Figure 4.3 b).

The spots in the RYGG were relatively larger compared with spots in the belly part (in RYGG 57 % of the spots were dark stained spot with diameter less than 3 cm, i.e. score 2, while in B1 and B2 52 % and 56 % of the spots were grayish shade, i.e. score 1) (Figure 4.5 a)

The dark stains were widely distributed and the majority of dark stained segments were observed between segment number 10 and 16. Dark stained segments showed a secondary peak at segment number 21 (Figure 4.5 b).

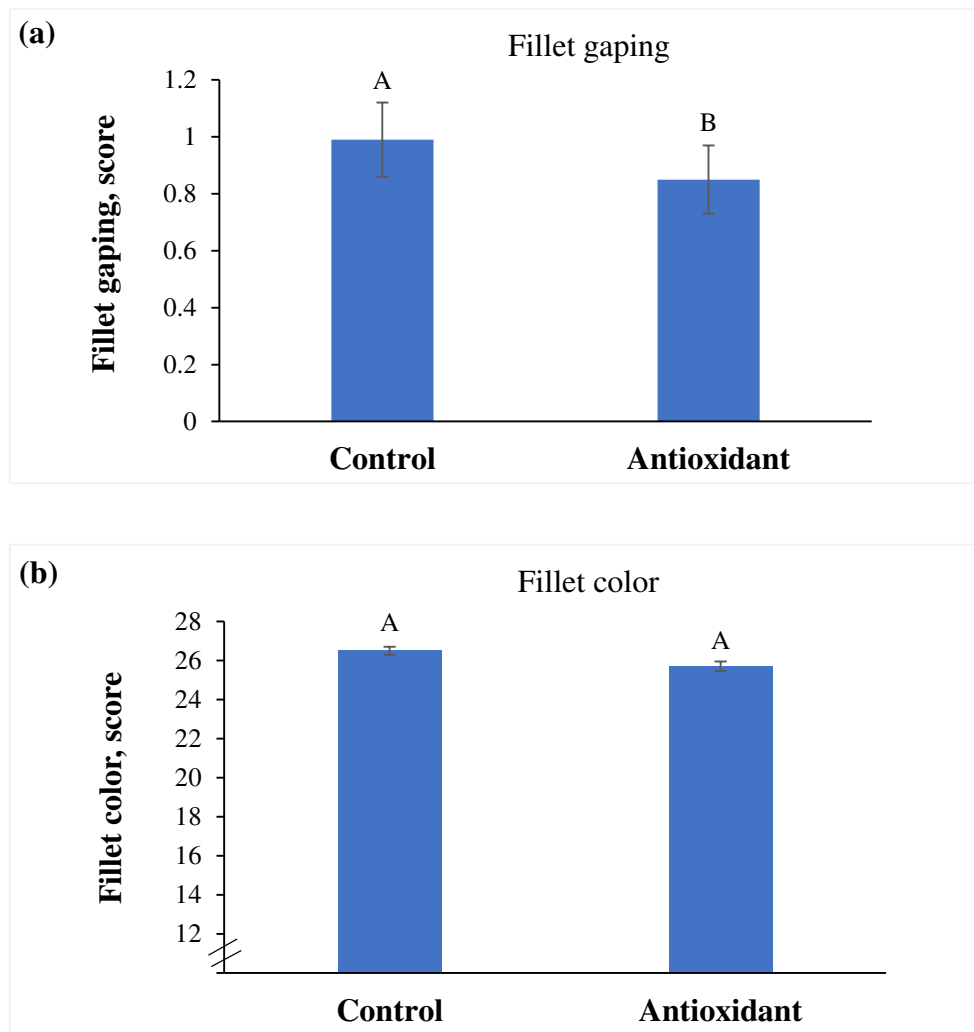


Figure 4.1: (a) Fillet gaping score; (b) Fillet color score of Atlantic salmon (*Salmo salar* L.). The salmon were fed a standard feed (Control) or the same feed added vitamin C, E and selenium (Antioxidant) during a 10 weeks period before slaughter. Results are presented as LS-Means \pm SE and different superscripts indicate significant differences between dietary treatments ($p \leq 0.05$).

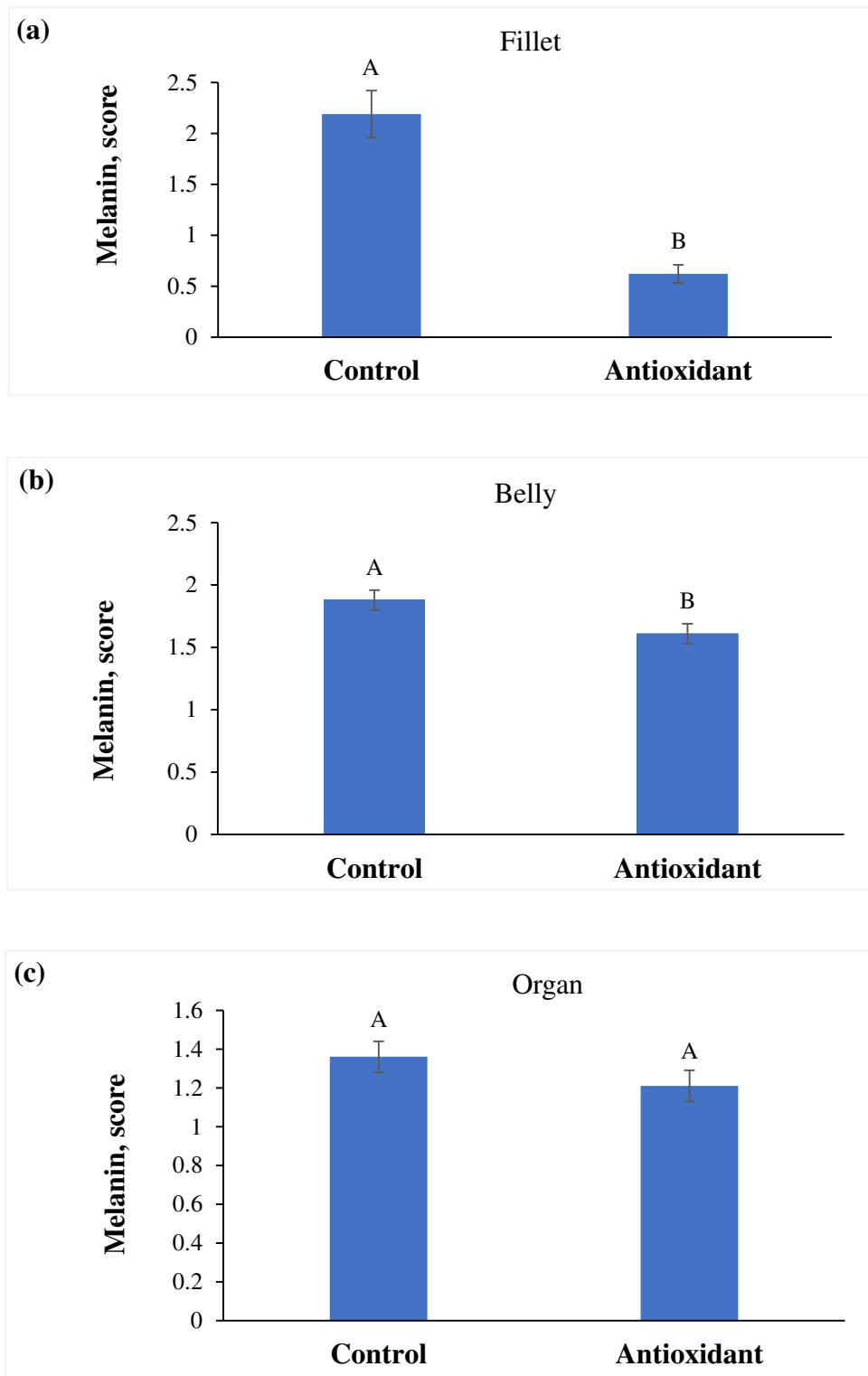


Figure 4.2: (a) Melanin score in fillet (score 0 - 8); (b) Melanin score in belly (score 0 - 3); (c) Melanin score in organ (score 0 - 3) of Atlantic salmon (*Salmo salar* L.). The salmon were fed a standard feed (Control) or the same feed added vitamin C, E and selenium (Antioxidant) during a 10 weeks period before slaughter. Results are presented as LS-Means \pm SE and different superscripts indicate significant differences between dietary treatments ($p \leq 0.05$).

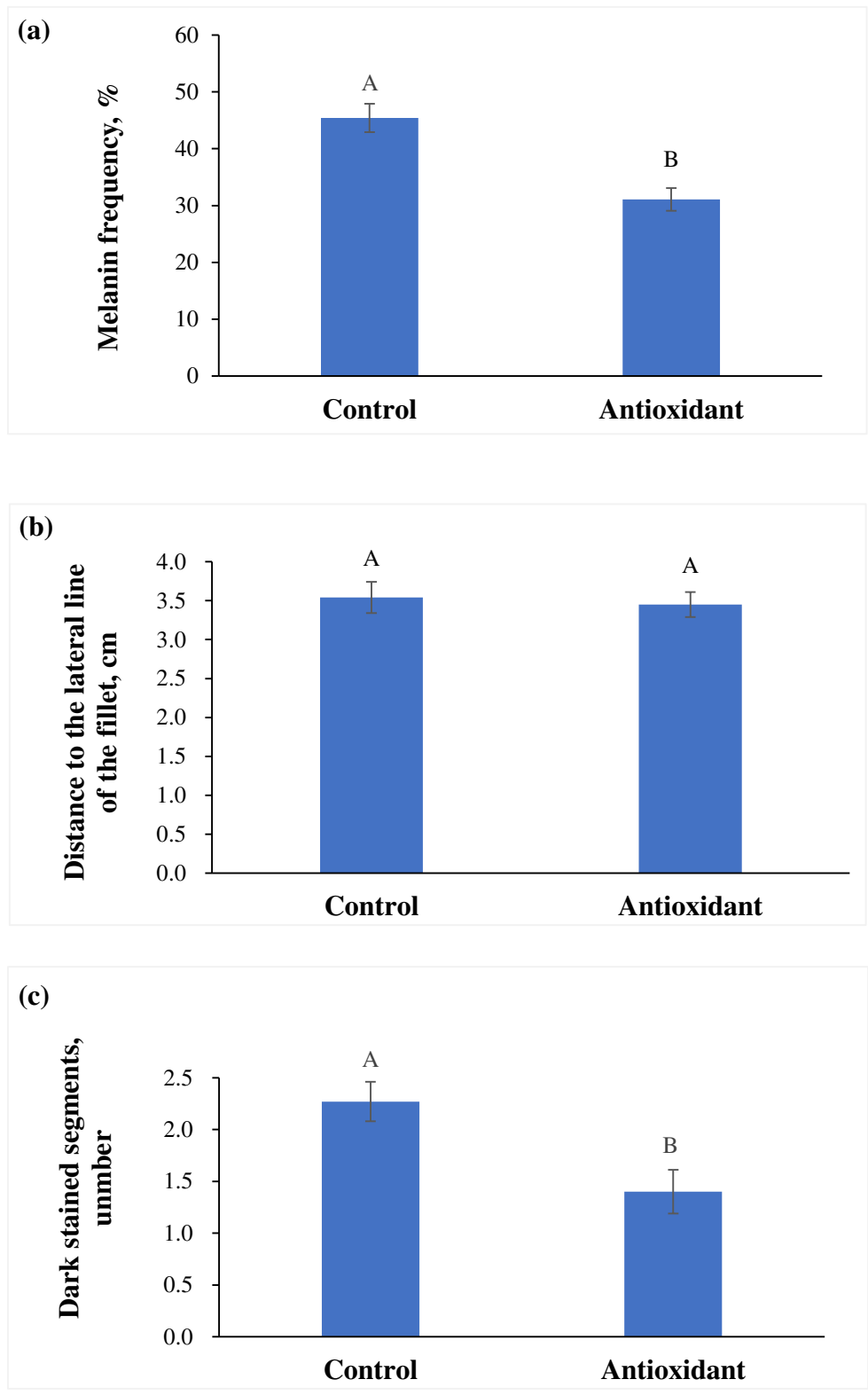


Figure 4.3: (a) Melanin frequency; (b) Distance from the center of the spot to the lateral line of the fillet; (c) Number of dark stained muscle segments of Atlantic salmon (*Salmo salar* L.). The salmon were fed a standard feed (Control) or the same feed added vitamin C, E and selenium (Antioxidant) during a 10 weeks period before slaughter. Results are presented as LS-Means \pm SE and different superscripts indicate significant differences between dietary treatments ($p \leq 0.05$).

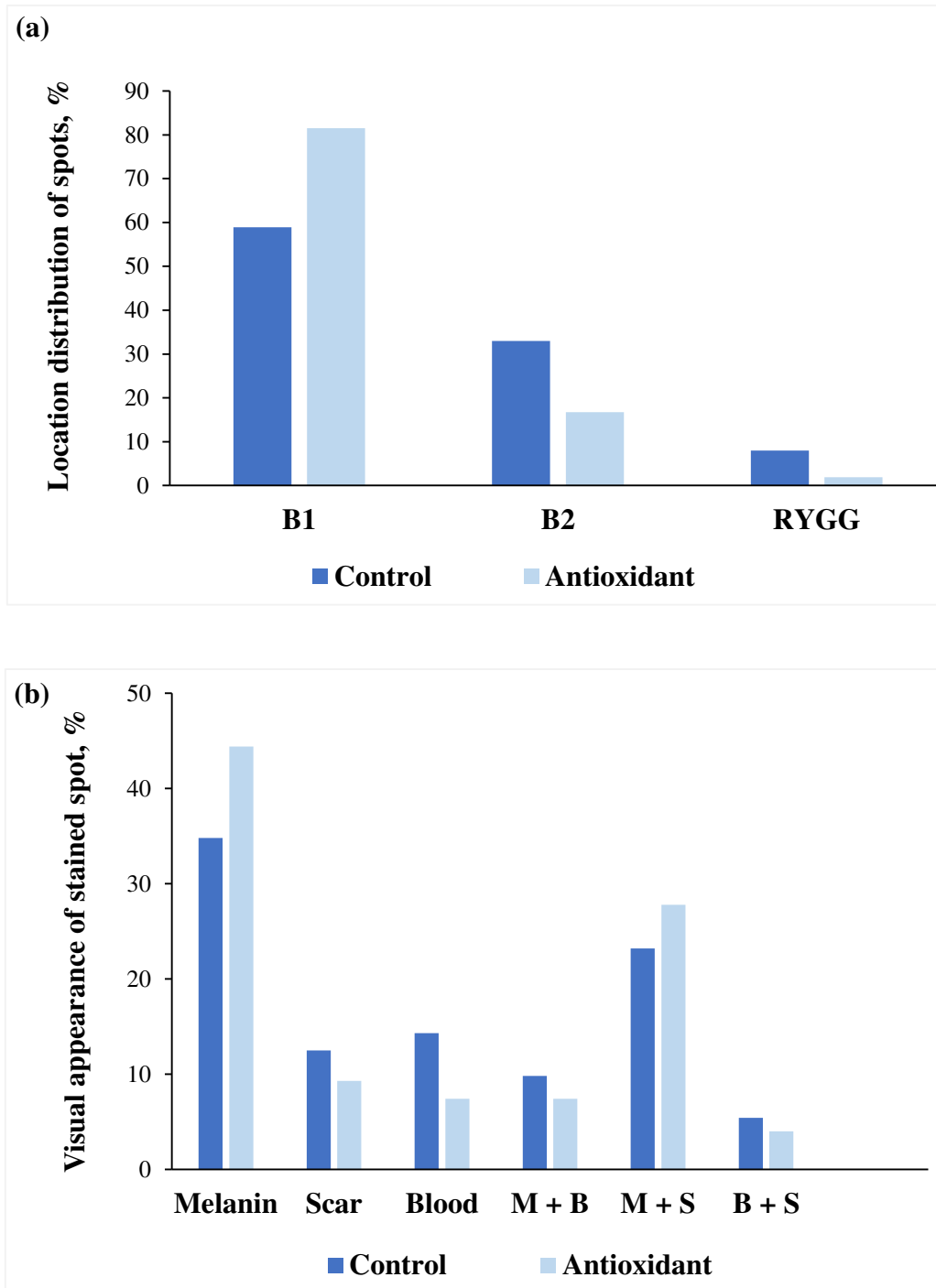


Figure 4.4: (a) Location distribution of stained spots in the fillets; B1 belly anterior, B2 belly posterior, RYGG dorsal; (b) Visual appearance of stained spots of Atlantic salmon (*Salmo salar* L.), M + B combination of melanin and blood, M + S combination of melanin and scar, B + S combination of blood and scar. The salmon were fed a standard feed (Control) or the same feed added vitamin C, E and selenium (Antioxidant) during a 10 weeks period before slaughter. Results are presented as LS-Means \pm SE and different superscripts indicate significant differences between dietary treatments ($p \leq 0.05$).

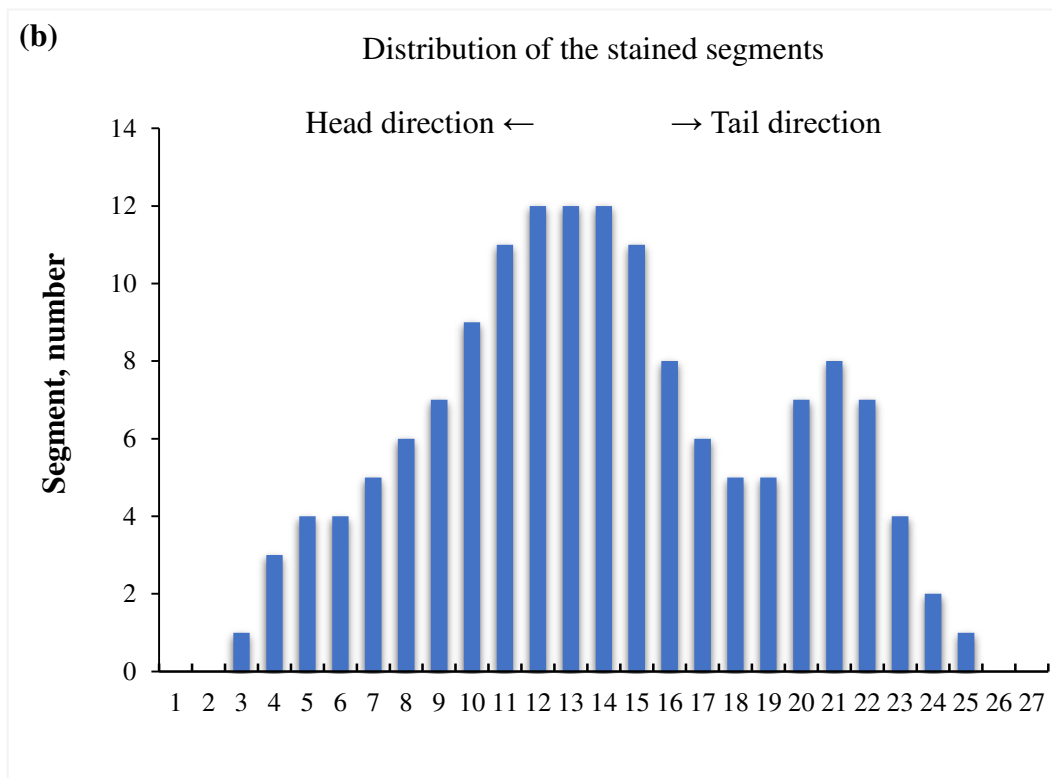
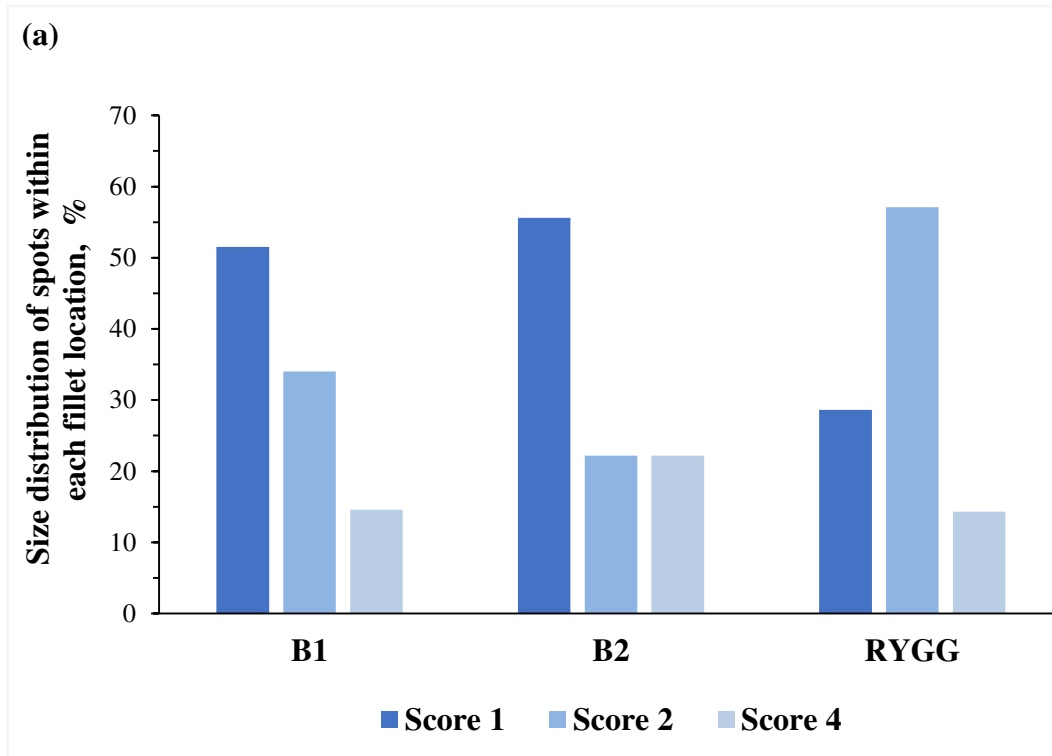


Figure 4.5: (a) Size distribution of spots within each fillet location; (b) Distribution of stained segments of Atlantic salmon (*Salmo salar* L.). B1: belly anterior; B2: belly posterior; RYGG: dorsal.

4.2.2 Colorimetric changes of melanin

- **L* lightness**

The L* value analyzed on Day 0 showed no significant variation between spot sizes within dietary treatments, except for the L* value of spots with score 1 that was significantly higher for the Antioxidant group (Figure 4.6 a).

The L* value analyzed on Day 7 decreased with spot size for both dietary treatments, but no significant differences were found between diets within spot size (Figure 4.6 b).

The L* value showed no significant changes during storage within spot score for either dietary treatments (Figure 4.5 a, b).

- **a* redness**

The a* value on Day 0 decreased with spot sizes of both dietary groups, but the pattern was more pronounced for the Antioxidant group. The a* value of spots with score 4 was significantly lower of the Antioxidant group compared with the Control group (Figure 4.6 a).

The a* value analyzed on Day 7 decreased with spot size for both dietary treatments, and the a* value for score 4 was significantly lower of the Antioxidant group (Figure 4.6 b).

The changes of a* value during storage showed no significant differences between dietary treatments (Figure 4.6 a, b).

- **b* yellowness**

The b* value analyzed on Day 0 showed a significant decrease with spot sizes. The b* value of spots with score 4 was significantly lower of the Antioxidant group (Figure 4.7 a).

The b^* value analyzed on Day 7 showed a general decrease with spot sizes for both dietary treatments. And b^* value of spots with score 4 was the lowest of the Antioxidant group (Figure 4.7 b).

The b^* value of score 4 decreased significantly during storage for the Antioxidant group, but no significant changes were found for score 1 and score 2 during storage for either dietary treatments (Figure 4.7 a, b).

The correlation (r) between analysis performed on Day 0 and Day 7 for lightness (L^*), redness (a^*) and yellowness (b^*) were 0.38, 0.67 and 0.68 respectively (Table 4.2).

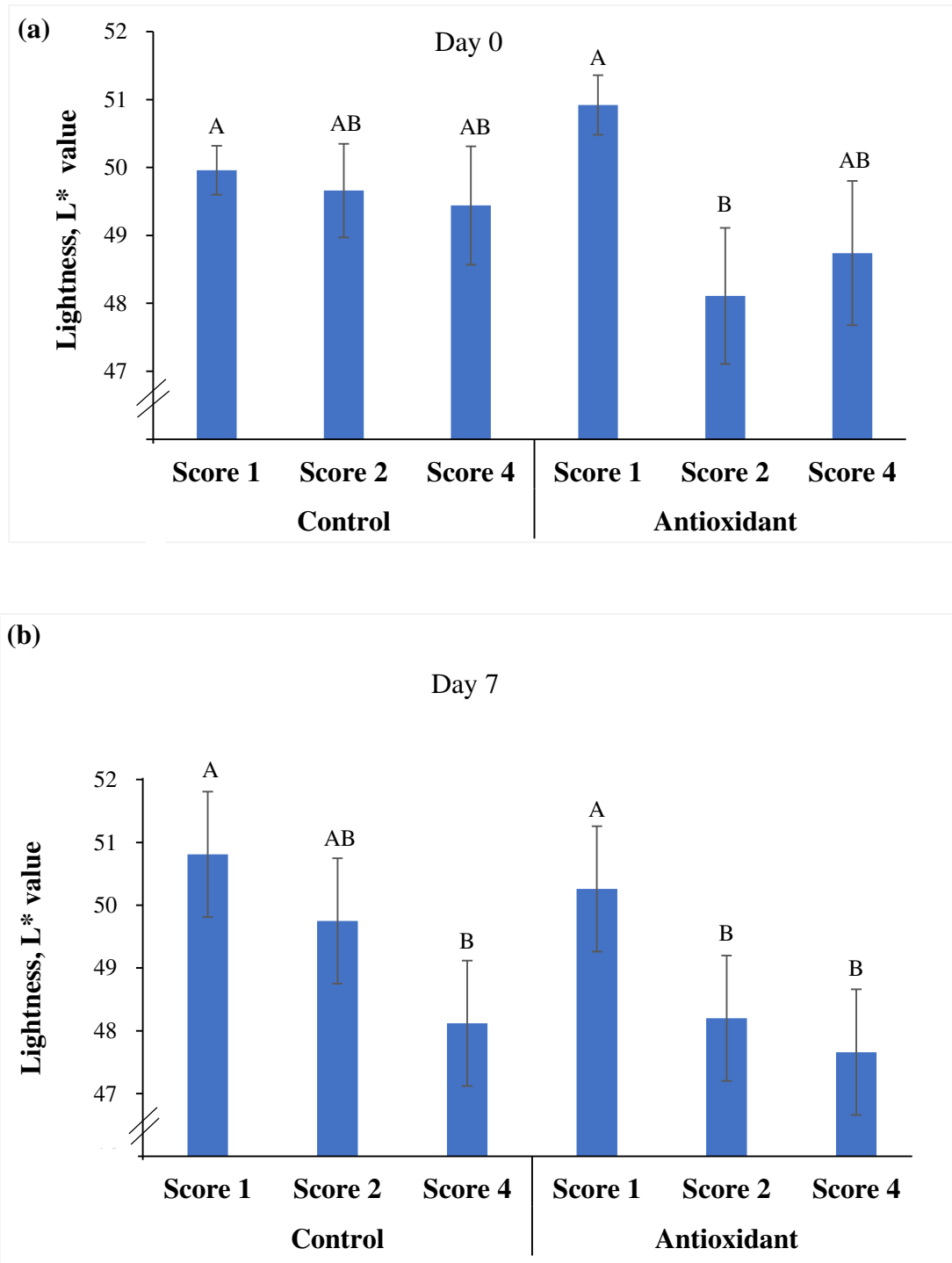


Figure 4.6: Lightness (L* value) of dark stained spots of Atlantic salmon fillets (*Salmo salar* L.) on Day 0 and Day 7. Results are presented for hyper-pigment areas with increasing discoloration. Score 1 grayish shade, score 2 marked spot ≤ 3 cm, score 4 marked dark stained spot 3 - 6 cm. The salmon were fed a standard feed (Control) or the same feed added vitamin C, E and selenium (Antioxidant) during a 10 weeks period before slaughter. Results are presented as LS-Means \pm SE and different superscripts indicate significant differences between dietary treatments ($p \leq 0.05$).

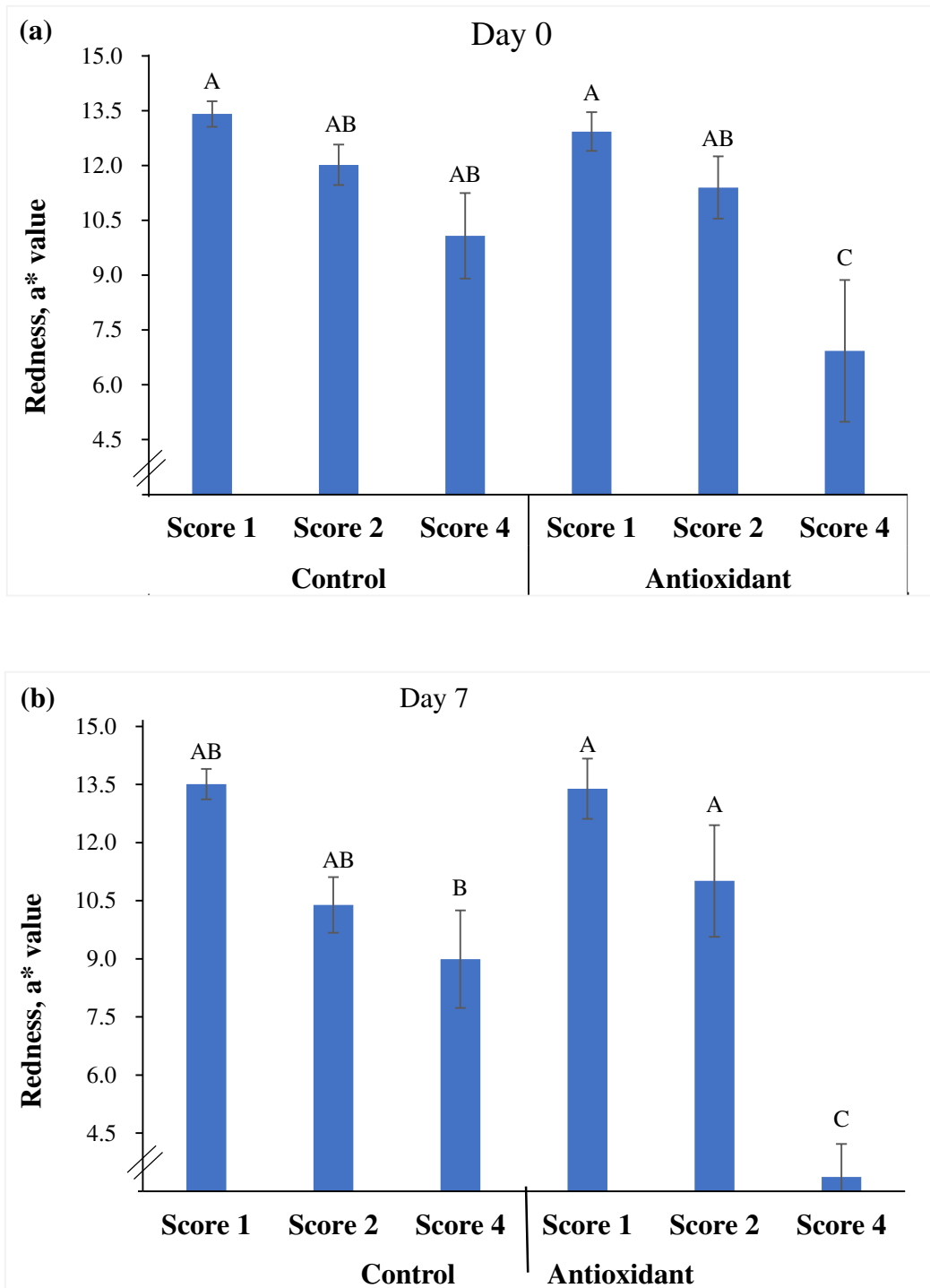


Figure 4.7: Redness (a^* value) of dark stained spots of Atlantic salmon fillets (*Salmo salar* L.) on Day 0 and Day 7. Results are presented for hyper-pigment areas with increasing discoloration. Score 1 grayish shade, score 2 marked spot ≤ 3 cm, score 4 marked dark stained spot 3 - 6 cm. The salmon were fed a standard feed (Control) or the same feed added vitamin C, E and selenium (Antioxidant) during a 10 weeks period before slaughter. Results are presented as LS-Means \pm SE and different superscripts indicate significant differences between dietary treatments and spots score ($p \leq 0.05$).

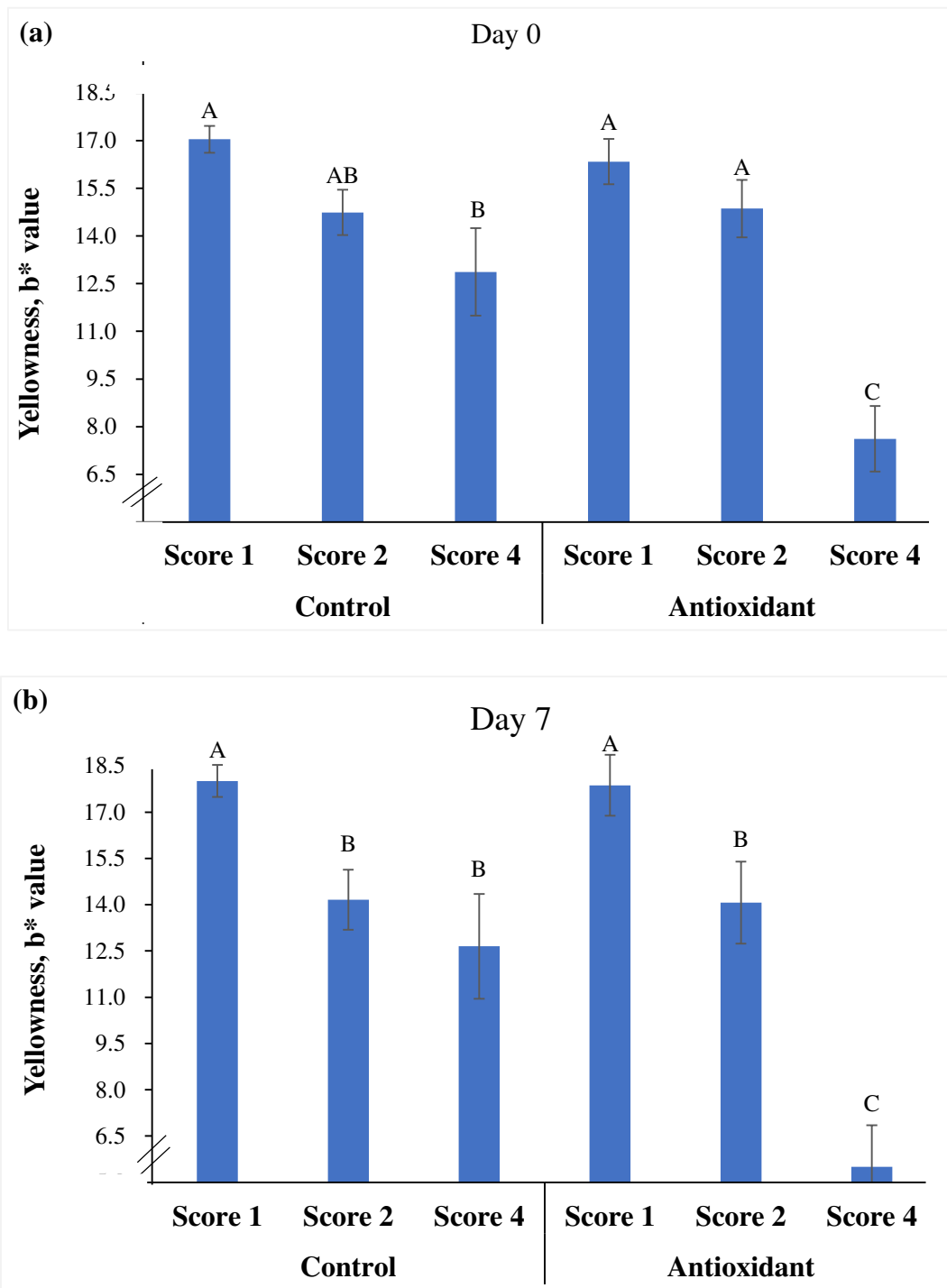


Figure 4.8: Yellowness (b* value) of dark stained spots of Atlantic salmon fillets (*Salmo salar* L.) on Day 0 and Day 7. Results are presented for hyper-pigment areas with increasing discoloration. Score 1 grayish shade, score 2 marked spot ≤ 3 cm, score 4 marked dark stained spot 3 - 6 cm. The salmon were fed a standard feed (Control) or the same feed added vitamin C, E and selenium (Antioxidant) during a 10 weeks period before slaughter. Results are presented as LS-Means \pm SE and different superscripts indicate significant differences between dietary treatments ($p \leq 0.05$).

Table 4.2: Correlation coefficient and P-value of CIE L*a*b* value determined on Day 0 and Day 7.

		Day 0		
		L* (Lightness)	a*(Redness)	b* (Yellowness)
Day 7	L* (Lightness)	0.38***	0.27*	0.29*
	a* (Redness)	.	0.67***	0.65***
	b* (Yellowness)	.	.	0.68***

* $p < 0.05$

** $p < 0.01$

*** $p < 0.001$

4.2.3 Image analysis

The average width and area of myocommata was significantly higher of the Antioxidant group compared to the Control group (Figure 4.9 a, b).

The average lightness (L^*) of myocommata was significantly higher of the Antioxidant group compared with the Control group (Figure 4. 10 a).

The average redness (a^*) of myocommata showed no significant differences between the two diets (Figure 4.10 b).

The yellowness (b^*) of myocommata was significantly higher of the Control group as compared with the Antioxidant group (Figure 4.10 c).

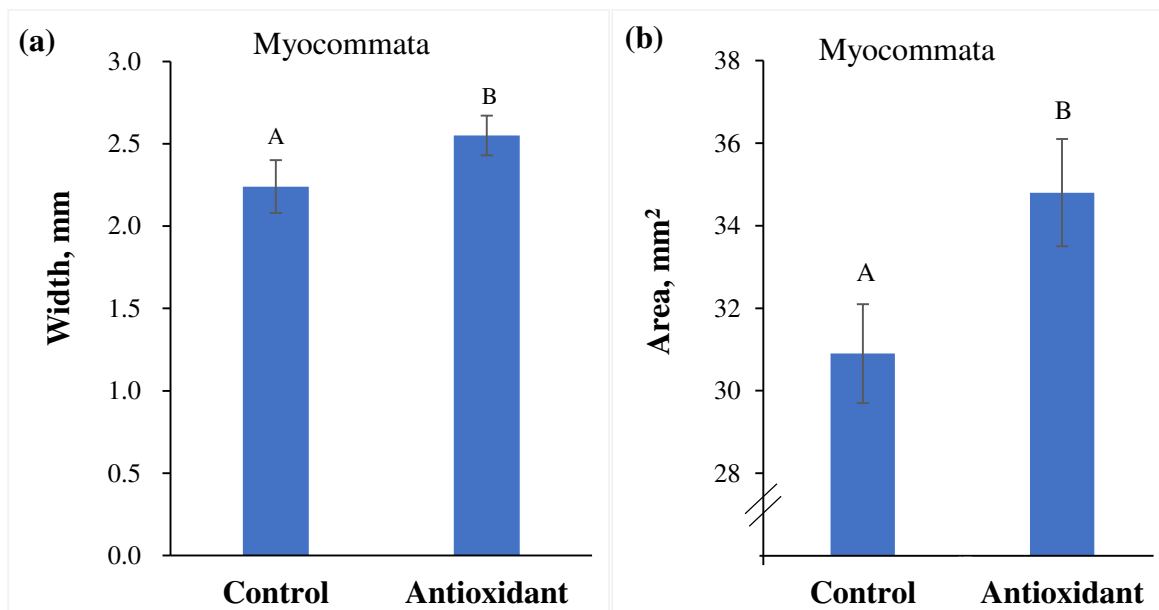


Figure 4.9: (a) Average width and area of myocommata of Atlantic salmon (*Salmo salar* L.). The salmon were fed a standard feed (Control) or the same feed added vitamin C, E and selenium (Antioxidant) during a 10 weeks period before slaughter. Results are presented as LS-Means \pm SE and different superscripts indicate significant differences between dietary treatments ($p \leq 0.05$).

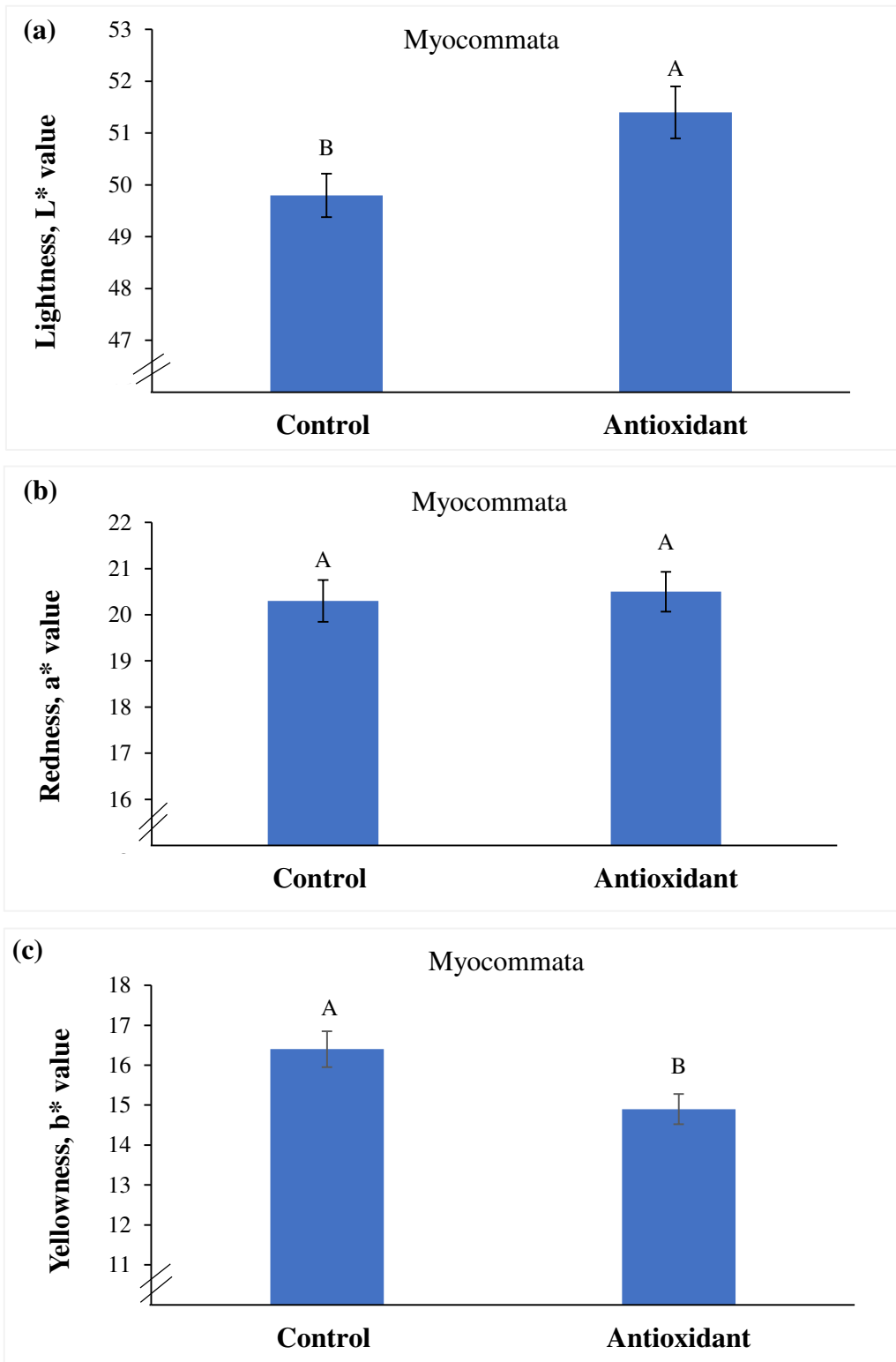


Figure 4.10: (a) Lightness (L* value); (b) Redness (a* value); (c) Yellowness (b* value) of myocommata of Atlantic salmon (*Salmo salar* L.). The salmon were fed a standard feed (Control) or the same feed added vitamin C, E and selenium (Antioxidant) during a 10 weeks period before slaughter. Results are presented as LS-Means \pm SE and different superscripts indicate significant differences between dietary treatments ($p \leq 0.05$).

5 Discussion

The discussion is divided in two parts. The first part describes general biometric traits of Atlantic salmon between dietary treatments. While the second part tissue evaluation of dark spots and myocommata are discussed.

5.1 Biometric traits

This result showed that supplementation of antioxidants (VitC, E and Se) had no significant effect on average body weight, fillet weight or carcass yield in this trial. The results were consistent with an earlier study conducted by Hang (2012) who reported that elevated VitE had no significant effect on growth performance of salmon weighted 3.4 kg on average (seawater temperature averaged 9°C). Hamre et al. (1997) documented higher growth in juvenile Atlantic salmon (body weight 0.2 g, temperature 12°C) when the diet was supplemented with VitC and VitE as compared with a deficient diet VitC and VitE. A study with African catfish showed that the body weight was not affected significantly by dietary Se levels when the feed contained 1 mg Se / kg or 8 mg Se/kg during a period of six weeks (Luten and Schram, 2006). Improvement in growth by dietary VitE supplementation was observed in some other species such as black sea bream (Peng et al. 2009), juvenile hybrid tilapia (Huang & Huang, 2004) and sea bream (Tocher et al. 2003). Gonçalves et al. (2010) noted that supplementation of 400 mg / kg VitE improved the standard length and weight gain of tambacus. Oppositely, Ruff et al. (2003) reported lower fillet weight for turbot when diets were supplemented with VitC and VitE.

Supplementation of antioxidants did not affect the condition factor (CF) which agrees with a study done by Rafiq (2015), who used a diet supplemented with VitE and Se.

5.2 Tissue evaluation

- **Flesh quality characteristics**

In the present study, the Antioxidant group showed significantly lower fillet gaping score compared to the Control group. Less gaping has been reported when the salmon contained a high collagen content in the muscle tissues (Sato et al., 1986; Eckhoff et al., 1998; Hultmann, 2000). Hang (2012) concluded that dietary supplementation of 1200 mg kg⁻¹ VitE resulted in firmer texture but no significant difference in gaping of Atlantic salmon. Therefore, reduction of fillet gaping might be accomplished by inclusion a mixture of antioxidants instead of a single antioxidant.

The red fillet color of farmed Atlantic salmon is related to dietary administered carotenoids, mainly astaxanthin that is an efficient antioxidant. The fillet color in the present trial was not influenced significantly by the supplementation of antioxidants in diet. This outcome agrees with Jafelice (2014), who concluded that dietary supplementation with antioxidants VitE and Se had no significant effect on the cutlet color of Atlantic salmon. However, an increase in the duration of feeding carotenoids has been reported to reduce inter-fish variation in pigmentation of Atlantic salmon (Torrissen et al. 1995), rainbow trout and chinook salmon (March and MacMillan, 1996). In the present study, there is no evidence that extra dietary antioxidants are sparing utilization of astaxanthin.

- **Visual characteristics of melanization**

Thorisen et al. (2006) and Larsen et al. (2012) associated dark staining of salmon skeletal muscle to immune and pigmentary systems of the fish, concluding that the pigment-producing granulomas are an inflammatory reaction. Similarly, Fagerland (2013) pointed out that melanin probably arises as a result of chronic inflammations and scar tissue formation. Komar et al. (2004) reported that this inflammatory immune response was elicited by intra-

peritoneal vaccination. However, Mørkøre (2012) reported that vaccination did not result in the development of melanin spots. Studies demonstrated that occurrence of pigmented spots tended to be increase with age and size of the fish, which might be explained by weakened immune response to infections or stress mechanisms with aging of fish (Mørkøre et al., 2012).

- Frequency of the spot

The study represented that the antioxidants reduced the occurrence of dark spots by 14% units compared to the Control group. This result agrees with Rafiq (2015) who concluded that feed components such as some vitamins and minerals could reduce the development of spots. Lauritzsen et al. (1999) noted that addition of ascorbate (VitC) efficiently reduced the incidence of lipid oxidation-induced discoloration by terminating the process of oxidation in salted cod muscle. Hence, addition of dietary VitE can sustain the oxidative stability in fish tissue and prevent pathological symptoms like discoloration related to lipid peroxidation (Sahoo and Mukherjee, 2002; Peng et al., 2009). However, the decreased melanin deposition of salmon fed diets supplemented with antioxidants may therefore reflect an upregulated immune response (Jafelice, 2014).

- Size of the spot

The majority of the spots had a diameter less than 3 cm, but the size of the spots varied between locations of the fillet. Over 50% of the spots in the belly area (B1 and B2) were score 1 (grayish shade). In the dorsal area (RYGG), up to 57% of the spots were score 2 (dark stained spot with diameter ≤ 3 cm). Hence the spots in the dorsal region were relatively larger than in the belly area of the fillet. Acharya (2011) and Koppang et al. (2005) reported that the pigmented areas varied in diameters from pinhead size up to 4 ~ 5 cm in diameter.

- Visual appearance of the spot

The visual evaluation of the discolored spots showed that melanin (black or brown appearance), and a combination of melanin and scar (white or grayish appearance) were the

most common. Only a few spots (4.7% on average) had a combination of blood and scar. It is well known that blood spot or blood effusion both on the surface and within the fillets not only represent an aesthetic problem but also contributes to reduced shelf life, lipid oxidation, muscle softening and loss of nutrients (Vareltzis et al., 2008; Pazos et al., 2009; Richards et al., 2009; Maqsood and Benjakul, 2010). However, it is not known whether melanin deposition affects the shelf life of the fillets.

- Position of the spot

The location of dark spots was consistently highest on the B1 (74%) and lowest in RYGG (6%), irrespective of dietary treatments. This outcome agrees with Mathiassen et al. (2007), Jafelice (2014), Mørkøre (2012) and Rafiq (2015), who reported that most of the dark spots in salmon fillets were detected in the anterior part of the abdomen while rarely found in the dorsal fillet part. The diet with antioxidants had no significant effects on melanin occurrence in belly and organs that is in concordance with a previous study performed by Jafelice (2014). The distance from the spot center to the lateral line of the fillet was 3.5 cm on average, regardless of dietary treatments.

There is no previous research published regarding to the accurate location of dark spot on salmon fillet. In the present study, the melanin mainly occurred between muscle segment number 10 and 16 with a peak at segment 12 and a secondary peak at segment 21. The total amount of stained segments was significantly less in the Antioxidant group (1.4) on average compared to the Control group (2.3), which is in accordance with earlier study, reporting that the involved muscle segments averaged from 2 to 5 myocommatas (Koppang et al., 2005). The results indicate that supplementation of antioxidants can reduce the spot diameter.

- **CIE L*a*b* values of melanin**

Generally, the L* value (lightness) decreased slightly with spots size but no significant differences on Day 0 or Day 7 between dietary treatments. The relationship of lightness on Day 0 and Day 7 was linearly positive correlated but quite weak ($r = 0.38$, p -value < 0.001). This finding implied that neither the supplementation of antioxidants and 7 days ice storage had significantly effect on L* value of dark spots. The L* value of dark stained spot with diameter 3 – 6 cm (score 4) of the Antioxidant group was higher than of smaller spots (score 2) on Day 0 which was not in keeping with the downtrend. The reason might be that the score 2 had higher darkness intensity but smaller diameter as compared to score 4. There is no previous investigations are reported on color change of dark spots with storage time, but color changes of fish fillet are documented. A study of Atlantic cod showed that the L* value increased during the first 4 - 6 hours ice storage post mortem and stayed stable or slightly decreased from 8 to 16 h (Mørkøre, 2006). Similarly, one study demonstrated that the lightness increased with time of frozen storage of cod (Skjervold et al., 2001 a,b; Choubert et al., 2006), saithe and redfish (Mu, 2014). But these results are in contrast with the findings of Fagan et al. (2002), who reported chilling storage had no effect on lightness of cod fillet.

The redness (a* value) decreased with spot sizes for both dietary treatments and this decrease become more obvious after 7 days ice storage. The a* value on Day 0 and Day 7 was positively correlated ($r = 0.67$, p -value < 0.001). The average reduction of a* from Day 0 to Day 7 was higher of the Antioxidant group as compared to the Control group, particularly for score 4, where the a* decreased from 6.9 to 3.4 (3.5 decreases) as compared to the Control group that decreased from 10.4 to 9.0 (1.4 differences). This result demonstrated that the dark spots become less reddish after one week ice storage, regardless of dietary treatment. But the grayish shade (score 1) become redder during ice storage. An earlier study pointed out that the salmon fillet was most red along the lateral line and in the tail region (Nicell and Bromage, 1998 b). Therefore, the position of the dark spot may influence the inherent redness and the change during ice storage.

After the ice storage, the smaller spots (score 1) seemed to be yellower (higher b^* value) as compared to the larger spots (score 2 and score 4) whether the feed was supplemented antioxidants or not. The yellowness of the spots was stable during storage, and the predictability during one week storage was high ($r = 0.68$, p -value below 0.001).

- **Myocommata evaluation**

Lipids stored in the muscle of farmed Atlantic salmon is affecting the texture, flavor and color (Borderias et al., 1999). High levels of PUFAs make salmon fillets easily susceptible to oxidation, leading to quality deterioration of salmon flesh (Burgaard, 2010). Lipofuscin results from the oxidative polymerization of PUFAs and it may accumulate in fish as a result of dietary VitE and VitC deficiency (Agius et al., 2003). The aquaculture industries and researchers investigated options to reduce lipid oxidation by including antioxidant (VitE) in the diets or injecting mixtures of antioxidants (VitC and citric acid) into fish fillet (Stéphan et al., 1995).

The Atlantic salmon stores most of its exercise energy as lipids in the skeletal muscle and viscera predominately as triglyceride (TG) (Polvi and Ackman, 1992). In the fillet, the fat is predominately stored in the myocommata (Zhou et al., 1995). Hence, the myocommata of salmon fillets are commonly used as an indicator of fat content. Estimation of the white striped myocommata can be standardized by determining the area of the stripes (Sigurgisladóttir et al., 1997).

The present study showed that supplementation of antioxidants resulted in significantly wider myocommata with higher lightness (L^*) and lower yellowness (b^*) compared to the standard feed. Sigurgisladóttir et al. (1997) reported that the fat content and the diameter of the fat stripes of salmon generally increase with fish weight. Also it has been reported that the size of myocommata was correlated positively with fat content of the fillet (Stien et al., 2007). The Antioxidant group showed 90 g higher body weight as compared to the Control group,

but this weight difference is not likely explaining the higher width and area of the myocommatas. The L^* value was positively correlated with fat content (wider width and area of myocommata) of the Antioxidant group, which was supported by the findings of Marty-Mahe et al., (2004), who documented that L^* value increased with lipid content, and there was high correlation between fat level and areas of myocommata ($r = 0.77$). Because thick fat stripes will lead to higher mean L^* values (Stien et al., 2006), it is possible that the wider width, larger area, higher lightness (L^*) and lower yellowness (b^*) of this trial were associated with prevented oxidation of lipids in the myocommata. As Abreua et al. (2011) reported that the additions of antioxidants to fish can slow down the rate of oxidation.

6 Conclusion

Supplementation of antioxidants (vitamin C, E and selenium) improved the fillet quality of farmed Atlantic salmon. The results can be summarized as follows:

- Supplementation of antioxidants in farmed salmon feed decreased the incidence of dark stained spots by 14% units and also reduced the size of dark spots significantly.
- Most spots were grayish shades or dark spots less than 3 cm in diameter, and located in the anterior belly of the fillet (B 1). Dark stained muscle segments were most prevalent between muscle segment number 10 and 16, regardless of dietary treatment.
- Melanin and a combination of melanin and scar were the main visual color of the dark spots. The appearance of dark spots maintained the same after 7 days ice storage.
- Supplementation of antioxidants increased the myocommata width, area and lightness (higher L* value) significantly, and decreased yellowness (lower b* value) significantly.
- Supplementation of antioxidants decreased the fillet gaping significantly.

7 References

- Aas, T. S., Sixten, H. J., Hillestad, M., Ytrestøyl, T., Sveier, H. & Åsgård, T. E. (2015). Feed intake and nutrient digestibility and retention in Atlantic salmon fed diets with different physical pellet quality. A create project 8282963240: Nofima. 17 pp.
- Acharya, D. (2011). Fillet quality and yield of farmed Atlantic salmon (*Salmo salar* L.): variation between families, gender differences and the importance of maturation. *Norwegian University of Life Sciences*. Master thesis.
- Agius, C., Roberts, R.J. (2003). Melano-macrophage centers in fish. *Journal of Fish Disease*. 2003, 26, 499-509.
- Alfnes, F., Guttormsen, A.G., Steine, G. & Kolstad, K. (2006). Consumers' willingness to pay for the color of salmon: a choice experiment with real economic incentives. *American Journal of Agricultural Economics*, 88 (4): 1050-1061.
- Andersen, B., Steinsholt, K., Stroemsnes, A. & Thomassen, M. (1994). Fillet gaping in farmed Atlantic salmon (*Salmo salar* L.). *Norwegian Journal of Agricultural Sciences* (Norway), 8: 165-179.
- Anderson, S. (2000). Salmon Color and the Consumer. *International institute of fishery and economics trade* (IIFET 2000): Microbehavior and microresults, Oregon, USA.
- Andrade, J.I.A., Ono, E.A., Menezes, G.C., Brasil, E.M., ...Roubach, R. (2007). Influence of diets supplemented with vitamins C and E on pirarucu (*Arapaima gigas*) blood parameters. *Comp. Biochem, Phys.*, 146:576-580.
- Barton, B. A. (2000). Salmonid fishes differ in their cortisol and glucose responses to handling and transport stress. *N. Am. J. Aqua-cult.* 62, 12–18.
- Barton, B. A., Bollig, H., Hauskins, B. L. and Jansen, C. R. (2000). Juvenile pallid (*Scaphirhynchus albus*) and hybrid pallid 3 shovelnose (*S. albus 3-platornychus*) sturgeons exhibit low physiological responses to acute handling and severe confinement. *Comp. Biochem. Physiol.*, 126A:125–134.

- Bell, J.G., Cowey, C.B., Adron, J.W. & Shanks, A.M. (1985). Some effects of vitamin E and selenium deprivation on tissue enzyme levels and indices of tissue peroxidation in rainbow trout (*Salmo gairdneri*). *Br. J. Nutr.*, 53, 149-157.
- Bjerkeng, B. (2004a). Colour deficiencies in cold-smoked Atlantic salmon. Skretting Norway.
- Bjerkeng, B., Refstie, S., Fjalestad, K., Storebakken, T., Rødbotten, M. & Roem, A. (1997). Quality parameters of the flesh of Atlantic salmon (*Salmo salar* L.) as affected by dietary fat content and full-fat soybean meal as a partial substitute for fish meal in the diet. *Aquaculture*, 157 (3): 297-309.
- Blaxhall, P.C and Daisley, K.W. (1973). Routine haematological methods for use with fish blood. *J. Fish Biol.*, 5: 771-781.
- Borderías, A.J., Gómez-Guillén, M.C., Hurtado, O. (1999) Use of image analysis to determine fat and connective tissue in salmon muscle. *Eur Food Res Technol.* 209:104–107.
- Borderías, A.J., Gómez-Guillén, M.C., Hurtado, O., Montero, P. (1999). Use of image analysis to determine fat and connective tissue in salmon muscle *European Food Research and Technology*, 209 pp. 104–107.
- Børresen, T. (2008). Improving seafood products for the consumer. *Part II Health benefits of seafood*, Chapter 10, 165-166.
- Bremner, H.A. & Hallett, I.C. (1985). Muscle fiber–connective tissue junctions in the fish blue grenadier (*Macruronus novaezelandiae*). A scanning electron microscopy study. *Journal of Food Science*, 50, 975–980.
- Burgaard, M. G., & Jørgensen, B. (2010). Effect of frozen storage temperature on quality-related changes in fish muscle: Changes in physical, chemical and biochemical quality indicators during short- and long-term storage. Kgs. Lyngby, Denmark: *Technical University of Denmark (DTU)*.

- Cavichiolo, F., Ribeiro, R.P., Moreira, H.L.M., Loures, B.R.R., ...Leonardo, J.M.L.O. (2002). Efeito da suplementação de vitamina C e vitamina E na dieta, sobre a ocorrência de ectoparasitas, desempenho e sobrevivência em larvas de tilápia do Nilo (*Oreochromis niloticus* L.) durante a reversão sexual. *Acta Sci. Anim. Sci.* 24(4):943-948.
- Chen, R., Lochmann, R., Goodwin, A., Praveen, K., Dabrowski, K and Lee, K.J. (2004). Effect of dietary vitamins C and E on alternative complement activity, hematology, tissue composition, vitamin concentration and response to heat stress in juvenile golden shiner (*Notemigonus crysoleucas*). *Aquaculture*, 242: 553-569.
- Chew, B.P. (1995). Antioxidant vitamins affect food animal immunity and health. *J. Nutrition.* 125:1804S.
- Choubert, G. and Baccaunaud, M. (2006). Colour changes of fillets of rainbow trout fed astaxanthin or canthaxanthin during storage under controlled or modified atmosphere. *Leensmittel Wissenschaft und Technologie* 29: 1203-1213.
- Combs, G.F. Jr and Scott, M.L. (1974). Antioxidant effects on selenium and vitamin E function in chicks. *Nutrition.* 104:1297-1303, 1974.
- Combs, G.F.J and Pesti, G.M. (1976) Influence of ascorbic acid on selenium nutrition in the chick. *Nutrition.* 106:958-966, 1976.
- Fagerland, H. (2013). Studies of extra-cutaneous pathological pigmentation black spots in Atlantic salmon.
- FAO. Aquaculture production. (2004). Year book of Fishery Statistics - Vol.96/2. *Food and Agriculture organization of the United Nations*, Rome, Italy.
- FAO. Aquaculture production. (2012). Year book of Fishery Statistics. *Food and Agriculture organization of the United Nations*, Rome, Italy.
- Fjellanger, K., Obach, A., Rosenlund, G. (2000). Proximate analysis of fish with special emphasis on fat. In: Kestin, S.C., Warris, P.D. (Eds.). *Farmed Fish Quality. Fishing News Books Ltd., Blackwell Science, Oxford, UK.* pp. 307–317.

- Folkestad, A., Wold, J. P., Rørvik, K.A., Tschudi, J., ...Mørkøre, T. (2008). Rapid and non-invasive measurements of fat and pigment concentrations in live and slaughtered Atlantic salmon (*Salmo salar* L.). *Aquaculture*, 280 (1-4): 129-135.
- Folmar, L. C., Dickhoff, W.W. (1980). The parr-smolt transformation (smoltification) and seawater adaptations in salmonids. *Aquaculture* 21 1–37.
- Forsberg, O. I. & Guttormsen, A. G. (2006). A pigmentation model for farmed Atlantic salmon: nonlinear regression analysis of published experimental data. *Aquaculture*, 253 (1): 415-420.
- Forsyth, D., & Ponce, J. (2003). Computer vision: a modern approach. *New Jersey*: Prentice Hall.
- Furones, M.D., Alderman, D.J., Bucke, D., Fletcher, T.C., Knox, D and White, A. (1992). Dietary vitamin E and the response of rainbow trout (*Oncorhynchus mykiss*) (Walbaum), to infection with *Yersinia ruckeri*. *J. Fish Biol.*, 41: 1037-1041.
- Galvan, I., Alonso-Alvarez, C. (2008). An Intracellular Antioxidant Determines the Expression of a Melanin-Based Signal in a Bird. *PLoS ONE* 3(10): e3335. doi:10.1371/journal.pone.0003335.
- Gatlin, D.M and Wilson, R.P. (1984). Dietary selenium requirement of fingerling channel catfish. *J Nutrition*.114: 627–633. pmid: 6699743doi: 10.1016/ 0044 -8486 (86) 9027 2-3.
- Haard, N. F. (1992). Control of chemical composition and food quality attributes of cultured fish. *Food research international*, 25 (4): 289-307.
- Hamilton, S.J. (2004). Review of selenium toxicity in the aquatic food chain. *Sci Total Environ* 326: 1–31. pmid: 15142762. Doi: 10.1016/j.scitotenv. 2004.01.019.
- Hamre, K and Lie, Ø. (1995). Minimum requirement of vitamin E for Atlantic salmon (*Salmo salar* L.) at first feeding. *Aquaculture Research*, 26: 175 –184.

- Hamre, K., Christiansen, R., Waagbø, R., Maage, A., Torstensen, ..., Albrektsen, S. (2004). Antioxidant vitamins, minerals and lipid levels in diets for Atlantic salmon (*Salmo salar* L.): effects on growth performance and fillet quality. *Aquaculture Nutrition*, 10: 113–123. doi: 10.1111/j.1365-2095.2003.00288.x
- Hamre, K., Waagbø, R., Berge, R. and Lie, A. (1997). Vitamin C and E interact in juvenile Atlantic salmon (*Salmo salar* L.). *Free Radic. Biol. Med.*, 22: 137-149.
- Hamre, K., Waagbø, R., Berge, R. K. & Lie, Ø. (1997). Vitamins C and E interact in juvenile Atlantic salmon (*Salmo salar*, L.). *Free Radical Biology and Medicine*, 22 (1): 137-149.
- Hang, T.N.A. (2012). Effects of dietary oxidation status and vitamin E level on performance, fillet quality and robustness to acute stress in Atlantic salmon (*Salmo salar* L.). *Norwegian University of Life Sciences*. Master thesis.
- Hearing, V. J and Jimnez, M. (1987). Mammalian tyrosinase: the critical regulatory control point in melanocyte pigmentation. *Int. J. Biochemistry*. 19, 1141-1147.
- Hearing, V. J., Tsukamoto, K., (1991). Enzymatic control of pigmentation in mammals. *Laboratory of Cell Biology, National Cancer Institute, National Institutes of Health, Bethesda, Maryland 20892, USA*.
- Heia, K., Sivertsen, A. H. & Birkeland, S. (2002). Automated quality control of salmon fillets-hyperspectral imaging for on-line inspection. Poster presentation at the 14th international Conference on near infrared spectroscopy, Bangkok, Thailand, 9-13 November.
- Hilton, J.W., Hodson, P.V., Slinger, S.J. (1980). The requirement and toxicity of selenium in rainbow trout (*Salmo gairdneri*). *J Nutr* 110: 2527–2535. pmid: 7441379.
- Hintz, H.F. (1996). Vitamin E nutrition of the horse. In “Vitamin E in animal nutrition and management” (M.B. Coelho, ed.), p. 446. BASF Corporation, Mount Olive, NJ.
- Hoel, E., Garseth, Å.H., Midtlyng, P.J., Bruheim, T., Taksdal, T., ...Olsen, A.B. (2007). Pancreas disease — en utredning for Fiskeri-og Kystdepartementet. *Nationally Veterinary Institute*. In Norwegian.

- Huang, C. H. & Huang, S. L. (2004). Effect of dietary vitamin E on growth, tissue lipid peroxidation, and liver glutathione level of juvenile hybrid tilapia, *Oreochromis niloticus*×*O. aureus*, fed oxidized oil. *Aquaculture*, 237 (1-4): 381-389.
- Jacobson, E.S., (2000). Pathogenic roles for fungal melanin. *Clinical Microbiology Reviews* 13, 708–717.
- Jobling, M., Koskela, J. & Savolainen, R. (1998). Influence of dietary fat level and increased adiposity on growth and fat deposition in rainbow trout, *Oncorhynchus mykiss* (Walbaum). *Aquaculture Research*, 29 (8): 601-607.
- Jovanovic, A., Grubor-Lajsic, G., Djukic, N., Gardinovacki, G., Matic, A., Spasic, M. (1997). The effect of selenium on antioxidant system in erythrocytes and liver of the carp (*Cyprinus carpio* L.). *Crit Rev Food Science Nutrition*. 37: 443–448. pmid: 9315433 doi: 10.1080/10408399709527783.
- Kiessling, A., Espe, M., Ruohonen, K. & Mørkøre, T. (2004). Texture, gaping and colour of fresh and frozen Atlantic salmon flesh as affected by pre-slaughter iso-eugenol or CO₂ anaesthesia. *Aquaculture*, 236 (1-4): 645-657.
- Kiessling, A., Ruohonen, K., Bjornevik, M. (2006). Muscle fiber growth and quality in fish. *Special Issue*, 137-146.
- Koller, L.D., Exon, J.H. (1986). The two faces of selenium deficiency and toxicity are similar in animals and man. *Canadian Journal of Veterinary Research* 50: 297–306. pmid: 3527390.
- Koppang, O.E., Haugarvoll, E., Hordvik, I., Aune, L. and Poppe, T.T. (2005). Vaccine-associated granulomatous inflammation and melanin accumulation in Atlantic salmon (*Salmo salar* L.) white muscle. *Journal of Fish Diseases*. 28, 13–22.
- Larsson, T., Krasnov, A., Lerfall, J., Taksdal, T., Pedersen, M., Mørkøre, T. (2012). Fillet quality and gene transcriptome profiling of heart tissue of Atlantic salmon with pancreas disease (PD). *Aquaculture*, 330–333 (2012) 82–91.
- Lauritzen, K., Martinsen, G., Olsen, R.L. (1999). Copper induced lipid oxidation during salting of cod (*Gadus morhua* L.). *J Food Lipids* 6: 299-315.

- Lerfall, J. (2011). The effect of pancreas disease and salting conditions on the quality of raw and cold-smoked Atlantic salmon (pp.14-16). Ås, Norway: *Hist.*
- Luten, J., Schram, E. (2006). Enrichment of functional selenium in farmed African catfish (*Clarias goriepinus*) by dietary modulation. *Seafood research from fish to dish*. P: 193-200.
- MacDermid, J., et al. (2012). A blinded placebo-controlled randomized trial on the use of astaxanthin as an adjunct to splinting in the treatment of carpal tunnel syndrome. *Hand*, 7(1), 1-9. Retrieved from <http://www.ncbi.nlm.nih.gov/pmc/articles/PMC3280376/>.
- Mackintosh, J.A. (2001). The antimicrobial properties of melanocytes, melanosomes and melanin and the evolution of black skin. *Journal of Theoretical Biology*, 211, 101–113.
- Maqsood, S. and Benjakul, S. (2010). Comparative studies on molecular changes and pro-oxidative activity of haemoglobin from different fish species as influenced by pH. *Food Chem.* 124 (3), 875–883.
- Marmol, V.D., Solano, F., Sels, A., Huez, G., Libert A.,Lejeune, F. (1993). 101, 871—874.
- Marty-Mahé, P., Loisel, P., Fauconneau, B., Haffray, P., Brossard, D., Davenel, A. (2004). Quality traits of brown trout (*Salmo trutta*) cutlets described by automated color image analysis. *Aquaculture*. 232, 225–240.
- McDowell, L.R. (1989). Vitamin E. Vitamins in animal nutrition: Comparative aspects to human nutrition. San Diego, CA: *Academic Press*; p. 94-131.
- Mills, D. (1989). Ecology and Management of Atlantic salmon. Springer-Verlag.
- Mørkøre, T. (2008). Tekstur i oppdrettsluks. Kunnskapsstatus og forhold som bidrar til fastere fillet. Rapport 32/2008.

- Mørkøre, T. (2010). Personal communication about importance of pigment level in Atlantic salmon. Ås, Norway.
- Mørkøre, T. (2012). Filet av oppdrettslaks: Kvalitetsavvik og årsakssammenhenger Nofima rapport.
- Mørkøre, T. (2012). Mørke flekker i laksefilet -Årsaker til forekomst og forebyggende tiltak.
- Mørkøre, T. and Prytz, K. (2013). Melanin deposition in salmon fillets. FAQ.
- Mu, G. (2014). Changes in the quality and yield of fish fillets due to temperature fluctuations during processing. *United Nations University Fisheries Training Program, Iceland* [final project]. <http://www.unuftp.is/static/fellows/document/mugang13prf.pdf>
- Mutoloki, S., Alexandersen, S. & Evensen, Ø. (2004). Sequential study of antigen persistence and concomitant inflammatory reactions relative to side-effects and growth of Atlantic salmon (*Salmo salar* L.) following intraperitoneal injection with oil-adjuvanted vaccines. *Fish and Shell fish Immunology*, 16, 633–644.
- Nickell, D.C., Bromage, N.R. (1998b). The effect of timing and duration of feeding astaxanthin on the development and variation of fillet color and efficiency of pigmentation in rainbow trout (*Oncorhynchus mykiss*). *Aquaculture*, 169, 223-246.
- Niki, E., Kawakami, A., Yamamoto, Y., Kamiya, Y. (1985) Oxidation of lipids. VIII. Synergistic inhibition of oxidation of phosphatidylcholine liposome in aqueous dispersion by vitamin E and vitamin C. *Bull Chem Soc Jpn* 1985; 58: 1971-5.
- Niki, E., Noguchi, N., Tsuchihashi, H. and Gotoh, N. (1995). Interaction among vitamin C, vitamin E and β -carotene. *The American Journal of Clinical Nutrition*.
- Norsk Fiskeoppdrett. (2008). Melanin I laksefilet. Nr. 9. Årgang 33.
- Olsen, S.H., Sorensen, N.K., Larsen, R., Elvevoll, E.O., Nilsen, H. (2008). Impact of pre-slaughter stress on residual blood in fillet portions of farmed Atlantic cod (*Gadus morhua*) - Measured chemically and by Visible and Near-infrared spectroscopy. *Aquaculture*. 284, 90-97.

- Pazos, M., Andersen, M.L., Skibsted, L.H. (2009). Efficiency of Hemoglobin from Rainbow Trout, Cod, and Herring in Promotion of Hydroperoxide Derived Free Radicals. *J. Agric. Food Chem.* 57, 8661-8667.
- Peng, S., Chen, L., Qin, J., Hou, J., Yu, N., ...Ye, J. (2009). Effects of dietary vitamin E supplementation on growth performance, lipid peroxidation and tissue fatty acid composition of black sea bream (*Acanthopagrus schlegeli*) fed oxidized fish oil. *Aquacult. Nutr.* 15, 329–337.
- Puangkaew, J., Kiron, V., Somamoto, T., Okamoto.
- Peng, S., Hou, J., Yu, N., Long, Z.,...Li, E. (2009). Effects of dietary vitamin E supplementation on growth performance, lipid peroxidation and tissue fatty acid composition of black sea bream (*Acanthopagrus schlegeli*) fed oxidized fish oil. *Aquaculture Nutrition*, 15 (3): 329-337.
- Pereira de Abreu, D.A., Paseiro Losada, P., Marotob, J., Cruz, J.M. (2011). Food Chemistry. Lipid damage during frozen storage of Atlantic halibut (*Hippoglossus hippoglossus*) in active packaging film containing antioxidants. Volume 126, Issue 1, 1 May 2011, Pages 315–320. doi: 10.1016/j. Food chemistry. 2010.10.048.
- Pittman, K., Grigory, V.M. & Brandebourg, T. (2013). Bridging the gap to sustainable salmon farming: overcoming the gaping problem. *Journal of Fisheries & Livestock Production* 1, 104.
- Polvi, S.M. and Ackman, R.G. (1992). Atlantic salmon (*Salmo salar* L.) muscle lipids and their response to alternative dietary fatty acid sources. *J. Agric. Food Chem.* 40: 1001-1007.
- Purser, J. & Forteach, N. (2003). Salmonids. In J.S. Lucas & P.C. Southgate (eds.), *Aquaculture: Farming Aquatic Animals and Plants*, pp. 295-320. Blackwell Publishing, Oxford, England.
- Rafiq, M. (2015). Dietary Impact of feed on performance, health and tissue melanization of Atlantic salmon (*Salmo salar* L.): *Norwegian University of Life Sciences*, Department of Animal and Aquaculture Sciences. Master thesis. 66 pp.

- Richards, M.P., Aranda Roman, I.V., He, C., Phillips G.N. Jr. (2009). Effect of pH on structural changes in Perch hemoglobin that can alter redox stability and heme affinity. *J. Aquat. Food Prod. Tech.* 18, 416-423.
- Rider, S.A., Davies, S.J., Jha, A.N., Fisher, A.A., Knight, J., Sweetman, J.W. (2009) Supra-nutritional dietary intake of selenite and selenium yeast in normal and stressed rainbow trout (*Oncorhynchus mykiss*): Implications on selenium status and health responses. *Aquaculture* 295: 282–291. doi: 10.1016/j.aquaculture.2009.07.003.
- Roberts, R.J., (1975). Melanin-containing cells of the teleost fish and their relation to disease. In: *The Pathology of Fishes* (edit. By Ribelin, W.E. & Migaki, G.), 399–428. University of Wisconsin Press, Madison, WI.
- Roth, B., Obach, A., Hunter, D., Nortvedt, R., Oyarzun, F. (2009b). Factors affecting residual blood and subsequent effect on blood spotting in smoked Atlantic salmon fillets. *Aquaculture*. 297, 163-168.
- Ruane, N., Rodger, H., Graham, D., Foyle, L., Norris, A., ...Geoghegan, F. (2005). Research on pancreas disease in Irish farmed salmon 2004/2005 — current and future initiatives, *Marine Environment and Health Series* No.22.
- Sahoo, P. & Mukherjee, S. (2002). Influence of high dietary α -tocopherol intakes on specific immune response, nonspecific resistance factors and disease resistance of healthy and aflatoxinB1-induced immunocompromised Indian major carp, *Labeo rohita* (Hamilton). *Aquacult. Nutr.* 8, 159–167.
- Sandnes, K., Torrissen, O. and Waagbø, R. (1992). The minimum dietary requirement of vitamin C in Atlantic salmon (*Salmo salar* L.) fry using Ca ascorbate-2-monophosphate as dietary source. *Fish Physiology and Biochemistry*. Volume 10, Issue 4, pp 315-319. DOI: 10.1007/BF00004480.
- Sato, K., Niki, E., Shimasaki, H. (1990). Free radical-mediated chain oxidation of low density lipoprotein and its synergistic inhibition by vitamin E and vitamin C. *Arch Biochem Biophys.* 1990:279:402-5.

- Schubring, R., Meyer, C. (2002). Quality factors of terrestrial snail products as affected by the speices. *J Food Sci* 67: 3148-3151.
- Sichel, G., Scalia, M., Mondio, F. & Corsaro, C. (1997). The amphibian Kupffer cells build and demolish melanosomes: an ultrastructural point of view. *Pigment Cell Research*, 10, 271–287.
- Sigurgisladottir, S., ØTorrissen, O., Lie, Ø., Thomassen, M., Hafsteinsson, H. (1997). *Reviews in Fisheries Science*. Salmon quality: Methods to determine the quality parameters. Vol. 5, Iss. 3.
- Sigurgisladottir, S., Torrissen, O., Lie, O., Thomassen, M., Hafsteinsson, H. (1997). *Rev Fish Science* 5:223–252.
- Skjervold, P.O., Bencze Rørå, A.M., Fjæra, S.O., Vegusdal, A., Vorre, A., Einen, O. (2001a). Effects of pre-, in-, or post-rigor filleting of live chilled Atlantic salmon. *Aquaculture*, 194, 315–326.
- Skjervold, P.O., Fjæra, S.O., Østby, P.B., Isaksson, T., Einen, O., Taylor, R. (2001b). Properties of salmon flesh from different locations on pre-and post-rigor fillets. *Aquaculture*, 201, 91–106.
- Skonberg, D.I., Hardy, R.W., Barrows, F.T., Dong, F.M. (1998). Color and flavor analyses of fillets from farm-raised rainbow trout (*Oncorhynchus mykiss*) fed low-phosphorus feeds containing corn or wheat gluten. *Aquaculture*, 166, 269-277.
- Spickler, A.R. & Roth, J.A. (2003). Adjuvants in veterinary vaccines: modes of action and adverse effects. *Journal of Veterinary Internal Medicine* 17, 273–281.
- Stéphan, G., Guillaume, J., and Lamour, F. (1995). Lipid peroxidation in turbot (*Scophthalmus maximus*) tissue: effect of dietary vitamin E and dietary n-6 or n-3 polyunsaturated fatty acids. *Aquaculture* 130: 251-268.
- Stetter, J. R. & Penrose, W. R. (2002). Understanding Chemical Sensors and Chemical Sensor Arrays (Electronic Noses): Past, Present, and Future. *Sensors update*, 10 (1): 189.

- Stien, H.L., Hirmas, E., Bjørnevik, M., Karlsen, Ø., Nortvedt, R., ...Kiessling, A. (2005) The effects of stress and storage temperature on the color and texture of pre-rigor filleted farmed cod (*Gadus morhua* L.). *Aquaculture Research*. 36, 1197-1206. Doi:10.1111/j.1365-2109.2005.01339.x.
- Stien, H.L., Manne, F., Ruohonene, K., Kause, A., Torrissen, K., Kiessling, A. (2006). Automated image analysis as a tool to quantify the colour and composition of rainbow trout (*Oncorhynchus mykiss* W.) cutlets. *Aquaculture*, 261 (2006) 695–705. www.elsevier.com/locate/aqua-online.
- Sulaimon, S.S., & Kitchell, B.E., (2003). The biology of melanocytes. *Veterinary Dermatology*, 14, 57–65.
- Tacchi, L., Bickerdike, R., Douglas, A., Secombes, C.J., Martin, S.A.M. (2011). Transcriptomic responses to functional feeds in Atlantic salmon (*Salmo salar* L.). *Fish & Shellfish Immunology*. 31 (2011) 704-715.
- Thorisen, J., Hoheim, B and Koppang, E.O. (2006). Isolation of the Atlantic salmon tyrosinase gene family reveals heterogenous transcripts in a leukocyte cell line. *Pigment Cell Research*. 19, 327-6.
- Tocher, D. R., Mourente, G., Van der Eecken, A., Evjemo, J. O., ...Olsen, Y. (2003). Comparative study of antioxidant defence mechanisms in marine fish fed variable levels of oxidized oil and vitamin E. *Aquaculture International*, 11 (1-2): 195-216.
- Warriss, P.D. (2010). *Meat Science*, 2nd Edition: An introductory text. Chapter 12: Measuring the composition and physical characteristics of meat: 182-186.
- Woodward, B. (1994). Dietary vitamin requirements of cultured young fish, with emphasis on quantitative estimates for salmonids. *Aquaculture*, 124: 133–168
- Zhou, X., Wang, Y., Gu, Q., Li, W. (2009). Effects of different dietary selenium sources (selenium nanoparticle and seleno-methionine) on growth performance, muscle composition and glutathione peroxidase enzyme activity of crucian carp (*Carassius auratus gibelio*). *Aquaculture* 291: 78–81. doi: 10.1016/j.aquaculture.2009.03.007.

9 Internet resources

Based on data sourced from the relevant FAO, Species Fact Sheets. Available at:

<http://www.fao.org/fishery/species/2929/en>.

Food and Agriculture Organization of the United Nations .FAO (2016). Atlantic salmon Nutritional requirements. Available at: <http://www.fao.org/fishery/affris/species-profiles/atlantic-salmon/nutritional-requirements/en/>.

Food and Agriculture Organization of the United Nations .FAO (2016). Aquaculture development and coordination program. Fish feed technology. Chapter 10. Antioxidants in Compounded Feeds. Available at: <http://www.fao.org/docrep/x5738e/x5738e0b.htm>.

Melanin in Wikipedia. Available at: <http://www.en.wikipedia.org/wiki/Melanin>.

Norwegian School of Veterinary Science.2013. “Melanin pigmentation in salmon fillets— causes and risk factors”. Available at: [http://www.nvh.no/en/Home/News/News/stories/Melanin pigmentation in salmon fillets--causes and risk factors/](http://www.nvh.no/en/Home/News/News/stories/Melanin%20pigmentation%20in%20salmon%20fillets--causes%20and%20risk%20factors/).

Norwegian University of Life and Science. 2015. Riddle of dark spots in salmon solved. Available at: <http://www.nmbu.no/en/news/node/23798>.

Norwegian School of Veterinary Science.2013. “Disease control in Norwegian salmon aquaculture with emphasis on Pancreas Disease and salmon louse”. Available at: [http://www.nvh.no/en/Home/News/News/stories/Disease/controlling/Norwegian/salmon/aquaculture/with/emphasis/on/Pancreas/Disease/and/salmon louse.](http://www.nvh.no/en/Home/News/News/stories/Disease/controlling/Norwegian/salmon/aquaculture/with/emphasis/on/Pancreas/Disease/and/salmon%20louse)

The Norwegian Ministry of Trade: Industry and Fisheries. Retrieved 27. Jan.2016, from: http://www.fisheries.no/aquaculture/Aquaculture/#.Vi_cmtSqPHx.

10 Appendixes

Appendix A

Visual characteristics and image analysis of dark spots of Atlantic salmon (*Salmo salar* L.) fed a standard diet (Control) or the same diet added VC, VE and Se (Antioxidant). Results are presented as LS-Means \pm SE and different superscripts indicate significant differences between dietary treatments ($p \leq 0.05$).

Parameters	Control	Antioxidant	P-value
Melanin frequency, %	45 \pm 0.05 ^A	31 \pm 0.04 ^B	0.0417
Melanin score in organ, score	1.36 \pm 0.08 ^A	1.21 \pm 0.08 ^A	0.1559
Melanin score on belly, score	1.88 \pm 0.08 ^A	1.61 \pm 0.08 ^B	0.0156
Melanin score on fillet, score	0.7 \pm 0.07 ^A	0.5 \pm 0.08 ^B	0.0256
Distance from the spot centre to lateral line of the fillet, cm	3.54 \pm 0.10 ^A	3.45 \pm 0.11 ^A	0.6520
Number of dark stained segments	2.3 \pm 0.17 ^A	1.4 \pm 0.21 ^B	0.0246
Myoc_Area (mm)	30.9 \pm 1.19 ^B	34.8 \pm 1.29 ^A	0.0301
Myoc_L*	49.8 \pm 0.42 ^B	51.4 \pm 0.5 ^A	0.0202
Myoc_a*	20.3 \pm 0.45 ^A	20.4 \pm 0.43 ^A	0.8047
Myoc_b*	16.4 \pm 0.45 ^A	14.9 \pm 0.38 ^B	0.0178
Width of Myoc (mm)	2.2 \pm 0.16 ^B	2.6 \pm 0.12 ^A	0.0229
Spots location, B1, %	59	81	.
Spots location, B 2, %	33	17	.
Spots location, RYGG, %	8	2	.
Melanin, %	34.8	44.4	.
Scar, %	12.5	9.3	.
Blood, %	14.3	7.4	.
Melanin and scar, %	23.2	27.5	.
Melanin and blood, %	9.8	7.4	.
Blood and scar, %	5.4	4.0	.

Appendix B

Colorimetric analysis (CIE L* a* b*) of different dark spot size of Atlantic salmon (*Salmo salar* L.) fed a standard diet (Control) or the same diet added VC, VE and Se (Antioxidant) on Day 0 and Day 7. Results are presented as LS-Means \pm SE and different superscripts indicate significant differences between dietary treatments ($p \leq 0.05$).

Parameters			L*	a*	b*
Control	Day 0	Score 1	49.96 \pm 0.36 ^A	13.41 \pm 0.37 ^A	17.04 \pm 0.38 ^A
		Score 2	49.66 \pm 0.69 ^{AB}	12.02 \pm 0.55 ^{AB}	14.74 \pm 0.71 ^A
		Score 4	49.44 \pm 0.87 ^{AB}	10.08 \pm 1.17 ^{AB}	12.87 \pm 1.38 ^A
	Day 7	Score 1	50.81 \pm 0.59 ^A	13.51 \pm 0.39 ^{AB}	18.01 \pm 0.52 ^A
		Score 2	49.75 \pm 1.14 ^A	10.39 \pm 0.72 ^{AB}	14.16 \pm 0.97 ^B
		Score 4	48.12 \pm 1.79 ^A	8.99 \pm 1.26 ^A	12.65 \pm 1.70 ^B
Antioxidant	Day 0	Score 1	50.92 \pm 0.44 ^A	12.93 \pm 0.53 ^A	16.34 \pm 0.71 ^A
		Score 2	48.11 \pm 0.10 ^B	11.4 \pm 0.85 ^{AB}	14.86 \pm 0.90 ^A
		Score 4	48.74 \pm 2.05 ^{AB}	6.93 \pm 1.94 ^C	7.62 \pm 1.03 ^C
	Day 7	Score 1	50.26 \pm 0.71 ^A	13.39 \pm 0.78 ^A	17.87 \pm 0.99 ^A
		Score 2	48.2 \pm 0.97 ^A	11.01 \pm 1.44 ^A	14.07 \pm 1.33 ^B
		Score 4	47.66 \pm 2.12 ^A	3.37 \pm 0.85 ^C	5.5 \pm 1.35 ^C



Norges miljø- og biovitenskapelig universitet
Noregs miljø- og biovitenskapelige universitet
Norwegian University of Life Sciences

Postboks 5003
NO-1432 Ås
Norway